

Magnetic Resonance Imaging Findings of Elbow Involvement in Behçet's Disease: Medical Education

Behçet Hastalığında Dirsek Eklemi Tutulumunun Manyetik Rezonans Görüntüleme Bulguları

Yonca ANIK, MD,^a
Ayşe ERGÜNEY ÇEFLE, MD,^b
Bahar MÜEZZİNOĞLU, MD,^c
Gür AKANSEL, MD,^a
Ali DEMİRCİ, MD^a

Departments of ^aRadiology,
^bInternal Medicine ^cPathology,
Kocaeli University,
School of Medicine, Kocaeli

Geliş Tarihi/Received: 19.03.2007
Kabul Tarihi/Accepted: 10.05.2007

Yazışma Adresi/Correspondence:
Yonca ANIK, MD
University of Kocaeli
School of Medicine
Department of Radiology, Kocaeli
TÜRKİYE/TURKEY
yoncaanik@yahoo.com

ABSTRACT Behçet's Disease is a systemic vasculitis of unknown etiology. Articular involvement is a well-recognized feature, that is generally intermittent, self-limiting, non-erosive, non-destructive, and non-deforming, usually monoarticular or symmetrically oligo-articular subacute arthritis. While knees, ankles and wrists are most commonly affected, elbow involvement is very rare. Previous descriptions of articular involvement have been mostly limited to conventional radiographic findings. We report magnetic resonance imaging (MRI) findings of pathologically proven acute synovitis on chronic arthritis of the left elbow in a 25 year-old man with Behçet's disease, who followed up for 9 years.

Key Words: Magnetic resonance imaging; Behcet Syndrome; arthritis

ÖZET Behçet hastalığı etiyolojisi bilinmeyen sistemik bir vaskülitir. Eklem tutulumu iyi bilinen bir özellik olup genelde kendini sınırlayan, geçici, erozyona veya destrüksiyona yol açmayan, sıklıkla monoartiküler veya simetrik oligoartiküler subakut artrit şeklindedir. Diz, ayak bileği ve el bileği en sık etkilenen bölgelerdir, dirsek tutulumu son derece nadir görülür. Literatürde tanımlanmış artiküler tutulum bulguları genellikle konvansiyonel radyografi bulgularıdır. Bu yazıda 9 yıldır takipli Behçet Hastalığı tanılı 25 yaşında erkek hastada sol dirsekte patolojik olarak kanıtlanmış kronik artrit zemininde akut sinovitin manyetik rezonans (MR) görüntüleme bulguları sunulmaktadır.

Anahtar Kelimeler: Manyetik rezonans görüntüleme; Behçet hastalığı; kronik artrit

Türkiye Klinikleri J Med Sci 2008, 28:378-381

Behçet's disease, which is a systemic vasculitis, may commonly exhibit articular involvement; however the elbow is very rarely affected.¹⁻⁵ Plain radiographs and clinical findings may not be satisfactory to diagnose the degree of involvement. MRI shows clearly the presence of synovial proliferation and inflammation. MRI findings in the case with Behçet's disease demonstrating acute synovitis in chronic arthritis of the left elbow are discussed in this paper.

A 25-year-old man was presented with progressive left elbow pain, which had started about 9 months ago. The patient had a 9-year history of recurrent oral and genital ulcerations, uveitis, and papulopustular skin lesions. He had been diagnosed with Behçet's disease; however, the follow-up was irregular. Physical examination showed swelling and tenderness of

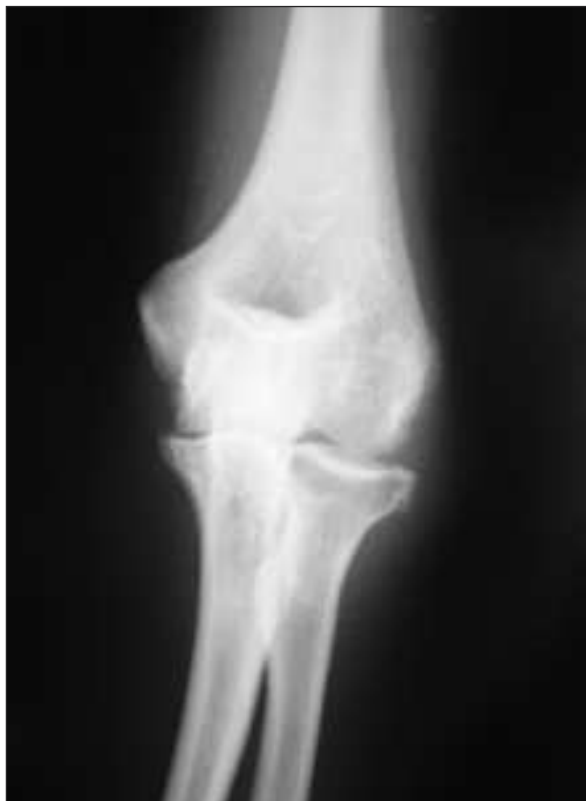

FIGURE 1: Plain radiograph shows joint-space narrowing, marginal erosions along the radial side of the elbow joint with soft tissue swelling.

the left elbow as well as limited range of motion. Plain radiograph showed joint-space narrowing, marginal erosions along the radial side of the elbow joint and soft tissue swelling (Figure 1). Informed consent was obtained. MRI was performed via 1.5-T MR scanner (Philips Gyroscan Intera Master, Eindhoven, The Netherlands, 30 mT/m maximum gradient strength, 150 mT/m per millisecond slew rate) using a surface coil. The patient was placed in the prone position with his left arm extending next to his head. MRI protocol included T1 (TR/TE= 578/15, TSE factor: 3, matrix: 320 x 512, NSA: 4) and T2 (TR/TE= 2500/100, TSE factor: 21, matrix: 320 x 512, NSA: 3) weighted TSE sequences; additional fat saturated T2 weighted images were performed in axial, sagittal and coronal planes. MRI revealed joint effusion and synovial thickening with marginal erosions and soft tissue edema (Figure 2a, 2b). After intravenous administration of 0.1 mmol/kg contrast medium (gadolinium-DTPA, Magnevist®, Schering, Germany), there was enhancement of the inflamed synovium due to acute synovitis (Figure 2c). The patient was diagnosed

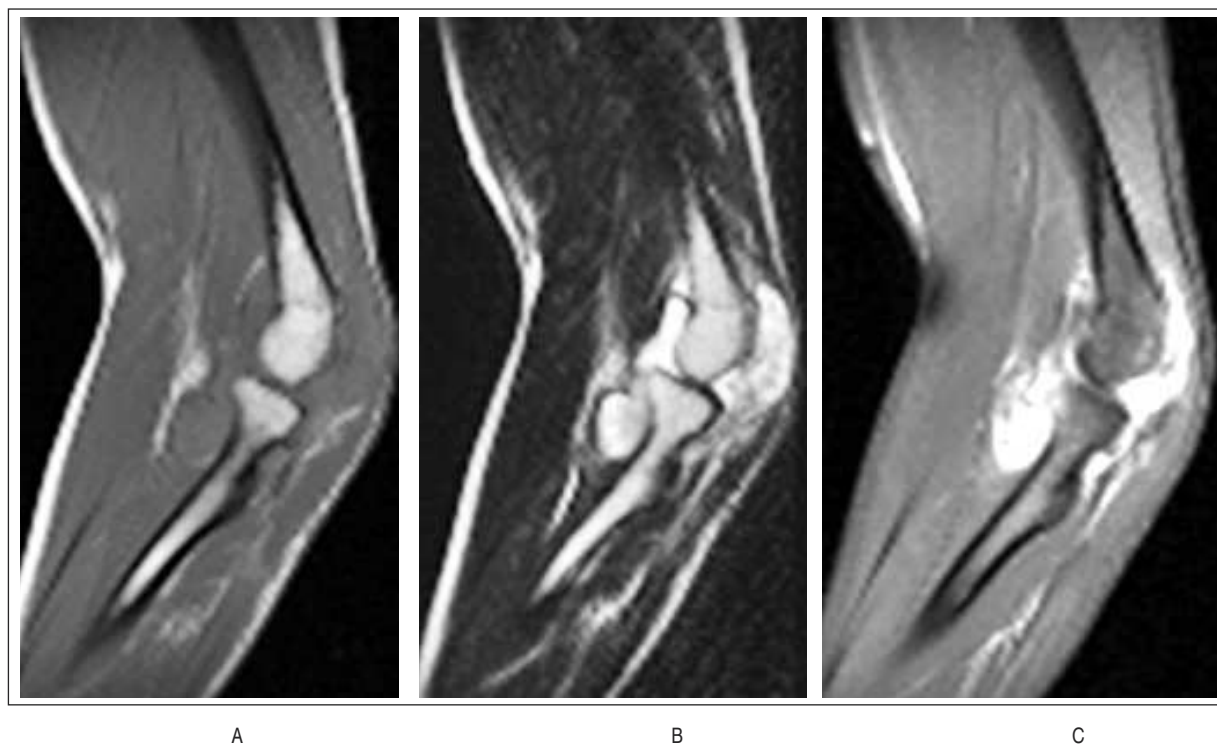


FIGURE 2: Sagittal **A.** precontrast T1-weighted, and **B.** T2-weighted images demonstrate joint effusion, significant synovial hypertrophy and soft tissue edema. **C.** Marked enhancement of the inflamed synovium following intravenous gadolinium is seen on post-contrast T1-weighted image.

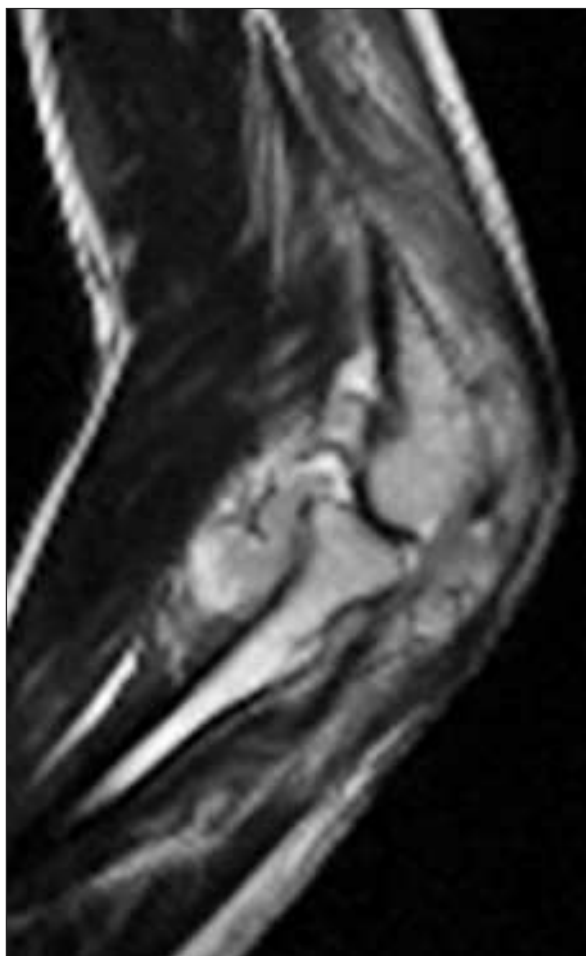
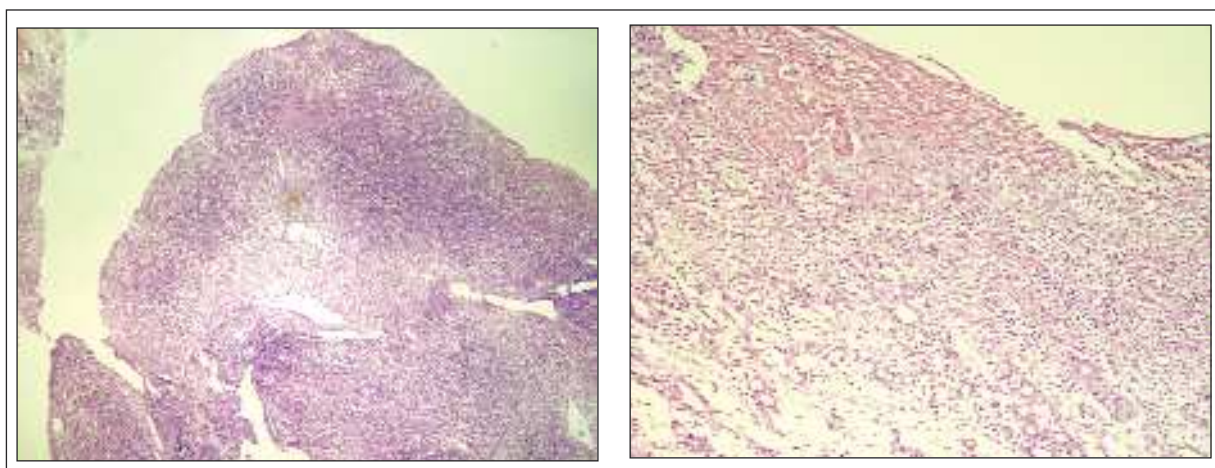


FIGURE 3: Sagittal T2 weighted images on the follow-up period at 3 months demonstrate significant synovial proliferation.

with arthritis caused by Behçet's disease. He was given indomethacin 125 mg/day, prednisolone 10 mg/day and sulphasalazine 2 g/day. The findings did not change significantly on follow-up MRI examination at 3 months after treatment (Figure 3). Although intraarticular corticosteroid injection was performed, no clinical response was achieved notably, so a synovial biopsy was carried out to rule out any infectious disease including tuberculosis. Since pathological examination showed non-specific acute synovitis on chronic base, azathiopurine 125 mg/day was added to the treatment (Figure 4a and 4b).

DISCUSSION

Behçet's disease is a systemic vasculitis of unknown etiology with the classical triad of oral and genital ulcerations and uveitis. The diagnosis is based on the criteria of the International Study Group defined in 1990.¹ Ocular, articular, vascular, pulmonary, mucocutaneous, gastrointestinal and nervous tissues are prone to develop manifestations of Behçet's disease.² Although articular involvement is a well-recognized feature (5% to 97% prevalence), the elbow is very rarely affected.³⁻⁵ Children are more likely to present with joint manifestations (73.7%) and polyarthritis (35.7%) than adults.⁵ Articular involvement is generally described as an intermittent, self-limiting, non-erosive, non-destructive, and non-deforming, usually



A

B

FIGURE 4: **A.** Villus like projections of hypertrophied synovium with diffusely proliferating mononuclear inflammatory cells (H&E x40). **B.** Acutely inflamed fibrous surface of the synovium with underlying vascular proliferation and chronic inflammation (H&E x40).

monoarticular or symmetrically oligo-articular subacute arthritis. Knees, ankles and wrists are the most commonly involved joints, while involvement of the spine, sacroiliac joints, shoulder, hip are rare and elbow is very rare.^{2,5-9} The duration of attacks is usually 2 months or less, but may occasionally be as long as 4 years.^{2,5-8} Unusual forms include polyarthritis resulting in joint deformity and/or destruction.^{5,10,11.}

Imaging findings include mostly non-specific findings such as osteoporosis and soft-tissue swelling, rarely accompanied by joint-space narrowing and marginal erosions.^{3-5,11,12} Enhancement due to gadolinium uptake in the synovium may correlate with acute synovitis. Biopsy may confirm the imaging findings of synovial proliferation and inflammation.^{6,12-14} Synovial inflammation was documented in previous reports. It is confirmed by synovial fluid, usually a good mucin clot formation, hypertrophy and hyperplasia of synovial lining cells, hypervascularity, subsynovial accumulation of inflammatory cells, and replacement of the superficial zones of the synovial membrane by dense inflamed granulation tissue composed of lymphocytes, macrophages, fibroblasts, neutrophils, and vascular elements.^{6,12,14} Rheumatoid arthritis is the main entity in the radiological and pathological differential diagnosis.¹⁴

Our case demonstrated monoarticular, chronic, erosive, deforming elbow involvement.

The cardinal radiological findings consisted of joint-space narrowing, marginal erosions along the radial side of the elbow joint accompanying soft tissue swelling and acute synovitis with synovial proliferation and inflammation. Long-standing Behçet's disease, monoarthritic involvement, negative rheumatoid factor and typical MRI findings lead us to diagnosis of arthritis due to Behçet's disease. There was no clinical response to non-steroidal anti-inflammatory drugs, oral and intraarticular corticosteroid treatment and sulphasalazine. Thus biopsy was performed. Histologically, synovial tissue showed villus like hypertrophy with prominent inflammation, in part, synovial surface had fibrinous material and intimately mixed polymorphonuclear leucocytes were seen. In other areas and beneath this acutely inflamed surface there was vascular proliferation and prominent, vaguely nodular lymphoplasmocytic infiltration in the synovial tissue. There were neither giant cells nor granulomatous structures detected. The patient is currently taking azathiopurine in addition to his previous medications.

CONCLUSION

Although very rare, Behçet's arthritis should be considered for the differential diagnosis of elbow arthritis. MRI gives information about the degree and phase of synovial involvement and is helpful for the evaluation of treatment.

REFERENCES

1. Criteria for diagnosis of Behçet's disease. International Study Group for Behçet's Disease. *Lancet* 1990;335:1078-80.
2. Serdaroğlu P. Behçet's disease and the nervous system. *J Neurol* 1998;245:197-205.
3. Kim HA, Choi KW, Song YW. Arthropathy in Behçet's disease. *Scand J Rheumatol* 1997;26:125-9.
4. Park JH. Clinical analysis of Behçet disease: arthritic manifestations in Behçet disease may present as seronegative rheumatoid arthritis or palindromic rheumatism. *Korean J Intern Med* 1999;14:66-72.
5. Benamour S, Zeroual B, Alaoui FZ. Joint manifestations in Behçet's disease. A review of 340 cases. *Rev Rhum Engl Ed* 1998;65:299-307.
6. Yurdakul S, Yazici H, Tüzün Y, Pazarlı H, Yalçın B, Altaç M, et al. The arthritis of Behçet's disease: a prospective study. *Ann Rheum Dis* 1983;42:505-15.
7. Caporn N, Higgs ER, Dieppe PA, Watt I. Arthritis in Behçet's syndrome. *Br J Radiol* 1983;56:87-91.
8. Katz AM. Behçet's disease: summary notes. *J Cutan Med Surg* 1998;3:88-9.
9. Benhamou CL, Dougados M, Amor B. Destructive arthritis and Behçet's syndrome. *Ann Med Interne (Paris)* 1982;133:576-9.
10. Düzgün N, Ateş A. Erosive arthritis in a patient with Behçet's disease. *Rheumatol Int* 2003;23:265-7.
11. Jawad AS, Goodwill CJ. Behçet's disease with erosive arthritis. *Ann Rheum Dis* 1986;45:961-2.
12. Choi JA, Kim JE, Koh SH, Chung HW, Kang HS. Arthropathy in Behçet disease: MR imaging findings in two cases. *Radiology* 2003;226:387-9.
13. Vernon-Roberts B, Barnes CG, Revell PA. Synovial pathology in Behçet's syndrome. *Ann Rheum Dis* 1978;37:139-45.
14. Gibson T, Laurent R, Highton J, Wilton M, Dyson M, Millis R. Synovial histopathology of Behçet's syndrome. *Ann Rheum Dis* 1981;40:376-81.