

Primary Hydatidosis Within Biceps Brachii: Case Report

Biceps Brachii Kası İçinde Primer Kist Hidatik

Mehmet Cengiz ÇOLAK, MD,^a
Hasan KOCATÜRK, MD,^b
Recep ÇELİK, MD,^c
Nesrin GÜRSAN, MD^d

Departments of
^aCardiovascular Surgery
^bCardiology,
^cOrthopaedics,
Şifa Medical Center,
^dDepartment of Pathology,
Ataturk University,
Faculty of Medicine, Erzurum

Geliş Tarihi/Received: 25.08.2008
Kabul Tarihi/Accepted: 06.11.2008

Yazışma Adresi/Correspondence:
Mehmet Cengiz ÇOLAK, MD
Şifa Medical Center,
Department of
Cardiovascular Surgery, Erzurum,
TÜRKİYE/TURKEY
drmccolak@yahoo.com

ABSTRACT Primary hydatid disease in the muscle is very rare. Usually, intramuscular hydatid cysts are secondary, resulting either from the spread of cysts spontaneously or after surgery. We report an unusual case of primary hydatidosis within biceps brachii muscle. It was diagnosed on the basis of the computed tomography appearance, clinical and pathological findings. Under general anesthesia we carefully tried to isolate the cyst from the surrounding muscles. However, the mass was ruptured inadvertently. Following irrigation of cystic cavity with hypertonic saline solution, the cyst wall was excised. There is no recurrence in the postoperative second year. In geographic regions where hydatidosis is endemic, hydatid cyst should be included in the differential diagnosis of a cystic mass in the muscle to avoid fine-needle biopsy and it must be carefully dissected from the surrounding muscles. The rupture of the cyst may not only result in recurrence and dissemination, but may also cause anaphylaxis and its surgical resection is difficult.

Key Words: Muscles; rupture; echinococcosis

ÖZET Kista primer kist hidatik çok nadir görülmektedir. Genellikle ya operasyon sonrası ya da kistin spontan olarak yayılması ile kas içinde sekonder olarak bulunmaktadır. Biceps brachii kası içinde bir primer kist hidatik vakası tespit edildi. Kompüterize tomografi, klinik ve patolojik bulgular ile tanı konuldu. Genel anestezi altında kist, dikkatlice kastan izole edilmeye çalışıldı; fakat istemeyerek rüptür oluştu. Kist kavitesi hipertonic tuzlu solüsyon ile yıkandı ve kist duvarı çıkarıldı. Kist çıkarıldıktan sonra 2 yıl içinde tekrarlama görülmedi. Kist hidatiğin endemik olduğu bölgelerde, kastaki bir kistik kitlenin ayırıcı tanısı yapılırken ince- iğne biyopsisinden kaçınılmalı ve çevreleyen kas dokusundan kist dikkatlice izole edilmelidir. Cerrahi rezeksiyonun zorluğundan, yayılma ve tekrarlardan dolayı kist rüptürü anafilaksiye neden olabileceği dikkate alınmalıdır.

Anahtar Kelimeler: Biceps brachii kası; kist rüptürü; echinococcosis

Türkiye Klinikleri J Med Sci 2010;30(1):406-9

Echinococcosis (hydatid disease) is caused by *Echinococcus granulosus*, a small tapeworm parasite in dogs and wolves, and occasionally in cats. It occurs endemically in many regions worldwide including the Mediterranean countries.¹ The main host and source of infection for humans is the dog. It acquires the infection through ingestion of infected cystic organs of another affected animal. The feces of an infected animal contain a large number of eggs, which the dog transfers to its muzzle, tongue, and fur by licking its anal region. The humans get the infection from unwashed hands after having touched the dog that had swallowed the tapeworm eggs.

Indirectly, the infection in humans may result from drinking water contaminated with dog feces or by consuming fresh fruit and vegetables washed or irrigated with contaminated water. The embryo within the swallowed egg is released from its envelope by the action of duodenal and intestinal juice, it penetrates intestinal mucosa, enters the circulation, and via the portal vein reaches the liver.¹ Around 75% of the parasites are retained in the capillary circulation, thus making the liver the most common localization of the disease.² If an embryo passes the obstacle, it migrates via the vena cava and right heart to the pulmonary capillaries. Therefore, the lungs are the second most common localization of *Echinococcal* cysts.¹ However, the embryo may pass this mechanical obstacle as well and reach via greater circulation any other organ in the body such as kidney, spleen, brain, heart, bone, orbit and muscle, and develop there.¹ Since the clinical picture is determined by the site, size, and the number of the cysts, it may vary greatly. The symptoms of compression are usually the initial clinical manifestation of the disease, preceded by a relatively long asymptomatic period. The patient's general condition may exacerbate dramatically due to the complications of cyst rupture or infection.²

CASE REPORT

A 59-year-old man was admitted to the department of cardiovascular surgery, for a tumor-like lesion in his right arm. Ten years before, it had been detected nodule with a 1 x 1 cm in diameter. It started growing, especially during the past year. The physical examination revealed a 9 x 3-cm, firm, tender and slightly mobile mass with smooth borders in the region of the biceps brachii. There was no fluctuation, erythema, ecchymosis, increased warmth, or lymphadenopathy. The elbow and shoulder had the full range of motion. Distal pulses were equal in the both upper extremities. The remainder of the physical examination was unremarkable. Complete laboratory data were normal. Plain radiographs were normal. Echocardiography was normal. Ultrasonography (US) revealed a hypoechoic cystic mass with echogenic septations (Figure 1). A non-contrast computerized tomography (CT) revealed

a cylindrically shaped 9.18 x 3.78 x 3.58-cm mass within the right biceps muscle (Figure 2). The density of the mass was slightly greater than that of the subcutaneous fat. The mass was confined within the biceps muscle without any bony involvement. Magnetic resonance imaging (MRI) could not be obtained because of the patient's claustrophobia. A careful clinical examination, plain chest and abdominal X-rays, ultrasound, CT and bone scanning revealed no other lesions.

We administered albendazol 400 mg twice a day starting four days before the operation and continuing for 28 days after the operation. Under general anesthesia, we carefully tried to isolate the cyst from the surrounding muscles. But the mass was ruptured inadvertently (Figure 3). Following irrigation of cystic cavity with hypertonic saline solution, the cyst wall was excised. Macroscopic and microscopic histopathological examinations confirmed the diagnosis of a hydatid cyst (Figures 4, 5). In the cyst, laminated and germinal layers were observed without any scolices. The patient refused Casoni skin test and serological tests in the preoperative and the postoperative period. There is no recurrence in the second postoperative year.

DISCUSSION

Incidence of musculoskeletal hydatidosis is not clear. According to authors, incidence of musculoskeletal Echinococcosis including involvement of subcutaneous tissue is 1%–5.4% among all cases of hydatid disease.³ Soft-tissue hydatid cysts occur in 2.3% of cases reported from endemic areas. They are usually associated with involvement of other solid organs.³ Muscular hydatid cysts may be primary, but may also occur secondarily when cysts spread from other areas, either spontaneously or after previous operations for hydatidosis in other regions of the body.⁵ Primary intramuscular hydatidosis is rare because the intramuscular growth of cysts is hindered by the muscle's contractility, and by the lactic acid in the muscle. Hydatid cysts tend to grow around the muscles of the neck, trunk and roots of the limbs, perhaps because there is greater vascularization and less muscular activity in these regions. They develop very

slowly and act as space occupying lesions, producing symptoms related to pressure on the surrounding tissues.⁵

Diagnosis of Echinococcosis should be considered when slowly growing soft tissue masses are present in the patients coming from rural areas especially in endemic countries. Because an intramuscular hydatid cyst may mimic any soft tissue tumor, preoperative clinical diagnosis of intramuscular hydatid disease is difficult.⁶ Before surgical excision or biopsy and extirpation of the cyst, diagnosis of Echinococcosis should be excluded to avoid leakage of cyst contents.⁵ It may be impossible to excise a large cyst en bloc, in which case the cyst is drained intraoperatively, irrigated with a scolecidal agent such as hypertonic saline, and then excised. Inadvertent cyst rupture releases viable scoleces, which may enter the circulation, disseminate to distant organs, and reproduce asexually to form additional cysts. The likelihood of recurrent infestation is increased after rupture of the parent cyst. Because the fluid of cyst contains a highly antigenic protein, leakage of cyst contents may cause anaphylactic shock.^{6,7} Thus, excision of an intact cyst is usually curative, whereas cyst rupture may be fatal.⁸ Diagnosis of echinococcosis is available through Casoni skin test and various serological tests, however they may give negative results because of encapsulation

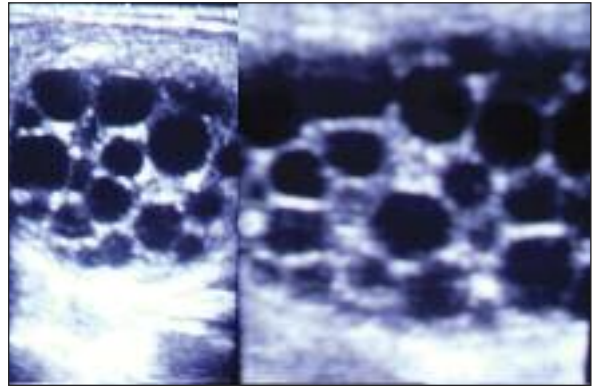


FIGURE 1: Ultrasonography shows an anechoic multiseptated cystic lesion in the biceps brachii.

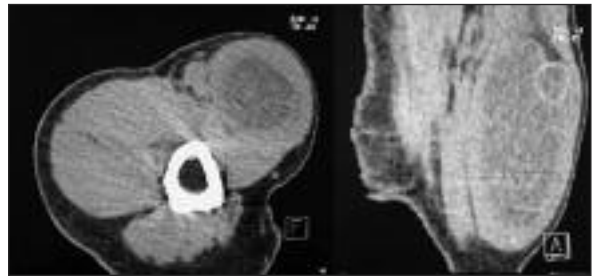

FIGURE 2: Axial (left) and sagittal (right) computerized tomography demonstrates that hypodense mass confined within the biceps brachii.

of the lesion; immunoelectrophoresis is the most specific method.⁵ US is useful in diagnosis, showing the size, localization and type of the cyst. The sen-

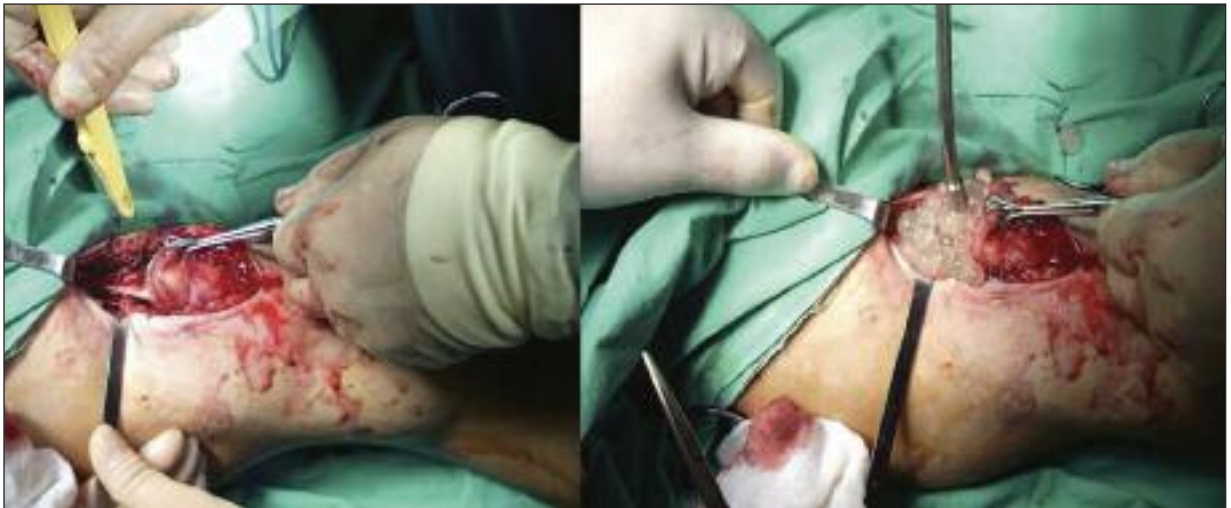

FIGURE 3: Intraoperative appearance of a hydatid cyst within the right biceps brachii.

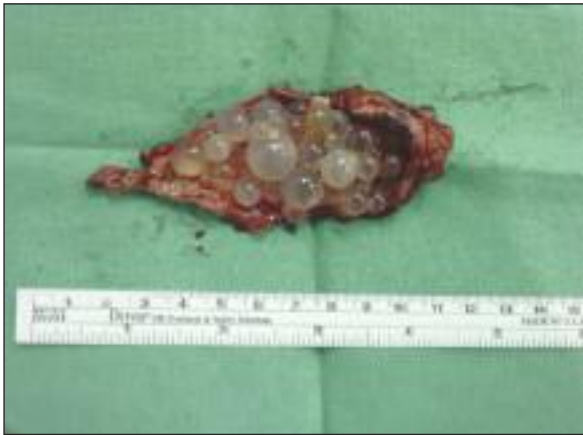

FIGURE 4: Macroscopic appearance of a hydatid cyst after it was cut open.

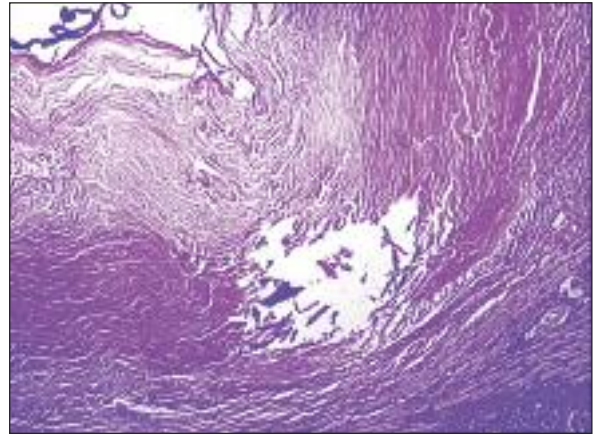


FIGURE 5: Microscopic view of a muscular hydatid cyst. Note the hyaline layer. No scolices are seen. PAS staining (X200).

sitivity of US is 95%, and if vesicular fibrils are present, the sensitivity of US increases to 100%. CT scan should be performed in suspicious cases or in order to determine the technique of surgery with demonstration of the relationship to adjacent organs.⁴ Preoperative diagnosis of musculoskeletal *E. granulosus* infection is difficult clinically and radiologically. It may resemble any soft tissue tumor. MRI is best for clear identification of involved structures and for surgical planning.⁵ It is also an effective means of making a differential di-

agnosis. Pericyst can be detected by US and the pathognomonic 'water-lily' sign (type-2 hydatid cyst) can be detected by MRI.⁸

Although hydatidosis is endemic in Turkey, this patient was misdiagnosed as having an abscess and underwent fine needle aspiration, which is contra-indicated in hydatid disease. In endemic areas, any cystic enlargement of soft tissue should raise the suspicion of hydatid disease. Serologic tests and US should be performed before any invasive procedure.

REFERENCES

1. Glunčić I, Roje Z, Bradarić N, Petricević A, Pisac VP, Glunčić V. Primary echinococcosis of the sternocleidomastoid muscle. *Croat Med J* 2001;42(2):196-8.
2. Morović M. Human hydatidosis in Dalmatia, Croatia. *Epidemiol Infect* 1997;119(2):271-6.
3. Orhan Z, Kara H, Tuzuner T, Sencan I, Alper M. Primary subcutaneous cyst hydatid disease in proximal thigh: an unusual localisation: a case report. *BMC Musculoskelet Disord* 2003;4:25.
4. Fikry T, Harfaoui A, Sibai H, Zryouil BL. Echinococcosse musculaire primitive. *J Chir* 1997;134(7-8):325-8.
5. Kazakos CJ, Galanis VG, Verettas DA, Polychronidis A, Simopoulos C. Primary hydatid disease in femoral muscles. *J Int Med Res* 2005;33(6):703-6.
6. Ates M, Karakaplan M. Hydatid cyst in the biceps and gluteus muscles: case report. *Surg Infect (Larchmt)* 2007;8(4):475-8.
7. Taşpınar V, Erdem D, Erk G, Baydar M, Göğüş N. [Intraoperative anaphylaxis caused by a hydatid cyst (case report)]. *Türkiye Klinikleri J Anest Reanim* 2004;2(1):36-40.
8. Durakbasa MO, Kose O, Islam NC, Kilicoglu G. A primary hydatid cyst of the gracilis: a case report. *J Orthop Surg (Hong Kong)* 2007;15(1):118-20.