

Rectovaginal Foreign Body After Rectal Suppository Insertion: Case Report

Rektal Fitol Uygulanması Sonrası Rektovajinal Yabancı Cisim

Nazile ERTÜRK,^a
Zeynep İLERİSOY YAKUT^b

^aClinic of Pediatric Surgery,
Ankara Etilik Zübeyde Hanım Gynecology
Training and Research Hospital,

^bClinic of Radiology,
Ankara Atatürk Training and
Research Hospital, Ankara

Geliş Tarihi/Received: 14.05.2013
Kabul Tarihi/Accepted: 11.11.2013

Yazışma Adresi/Correspondence:
Nazile ERTÜRK
Ankara Etilik Zübeyde Hanım Gynecology
Training and Research Hospital,
Clinic of Pediatric Surgery, Ankara,
TÜRKİYE/TURKEY
erturknazile@gmail.com

ABSTRACT In this case report, a case of vaginal discharge with foreign body was detected in vagina and history of foreign body insertion into rectum was presented. A rectal suppository was administered to a girl due to high fever. A few days later, she inserted a crayon to both her rectum and vagina during play at home. Crayon inserted to rectum was thrown out with bloody defecation but the one in vagina was not removed and since it led to vaginal discharge some time later, the family referred to the hospital. In literature review, we did not encounter a similar case. This may be due to rarity of such a combination. Another reason may be that diagnosis may be delayed since complaints arise at different times. The aim of this case report was to draw attention to such combinations in order to prevent complications.

Key Words: Rectum; vagina; foreign bodies; child

ÖZET Bu olgu sunumunda, vajinasında saptanan yabancı cisme bağlı vajinal akıntısı ve rektumunda yabancı cisim öyküsü bulunan bir olgu rapor edilmiştir. Olgumuz olan bir kız çocuğuna yüksek ateş nedeniyle bir rektal fitil önceden uygulanmıştır. Olgumuz birkaç gün sonra evde oynarken hem rektum hem de vajinasına boya kalemi yerleştirmiştir. Rektuma yerleştirilen boya, kanlı defekasyon ile dışarı atılmış, fakat vajinadaki çıkamamış ve bir süre sonra oluşan vajinal akıntı nedeniyle aile çocuğu hastanemize getirmiştir. Literatürde benzer bir olguya rastlamadık. Bu, böyle bir kombinasyonun nadirliğinden olabilir. Diğer bir neden, belki de şikâyetlerin farklı zamanlarda ortaya çıkmasıyla tanının gecikmesi olabilir. Bu olgu sunumunun amacı, komplikasyonları önlemek için bu konuya dikkatleri çekmektir.

Anahtar Kelimeler: Rektum; vajina; yabancı cisimler; çocuk

Türkiye Klinikleri J Pediatr 2013;22(4):194-6

Curiosity in their surroundings and the feeling of discovery may lead children to swallow foreign bodies or to insert them into vagina and rectum.¹ In contrast to adult cases, small children often cannot explain how or when vaginal or rectal foreign bodies may have been inserted. Sometimes affectation to imitate adults as it may cause. Adolescents may insert foreign bodies or have someone insert it for them (sexual act).² Here, we present a case of a child who inserted crayons into her rectum and vagina after rectal suppository administration.

CASE REPORT

A 2.5 year old girl presented to our clinic with complaints of vaginal discharge. It was learned from her history that her complaints started about

one month ago and was aggravated recently. In addition, few days before the onset of her complaints, she was administered rectal suppository in order to decrease fever. A few days after fever subsided, some blood came from anus and then with defecation a small crayon was thrown out. At that time, patient referred to emergency service with this complaint, but as rectal bleeding did not continue and physical examination did not yield any important findings, no additional treatment or investigation was considered.

No pathological finding was observed during systemic examination. In perineal examination, vulva had hyperemic appearance, hymen was intact with septum, and there was greenish, foul smelling discharge at the entrance of vagina. Anus had a natural appearance. Rectal digital examination was carried out, and hardness was palpated at anterior wall of rectum.

Laboratory investigations were as follows: Hb: 12 g/dL, leukocyte: 7800/mm³, in urine analysis: protein (-), sugar (-), density 1010. In microscopic investigation 5-6 leukocytes were found. No microbial growth occurred in urine and vaginal discharge culture. In direct abdominal graphy, there was a thin and long dense image in pelvic region (Figure 1). In abdominal ultrasonography foreign body appearance was seen in pelvic region (Figure 2), and it was reported that this appearance resembled a crayon. In view of these findings, patient was diagnosed with vaginal foreign body.

Due to the age of the child, vaginoscopy under general anesthesia was planned. Preparations were completed after the consent of the family was obtained. Patient was laid in lithotomy position. Vulva was cleaned with 1% povidone-iodine solution (Bethadine). Foreign body in the vagina was palpated by rectal digital examination. The edge of foreign body was seen while stroking it anteriorly by rectal touché. At the same time, through the opening of hymen, a forceps was introduced and a crayon with a length of 3.5 cm was pulled out.

Without the examination by vaginoscopy, vagina was irritated with Bethadine solution, and

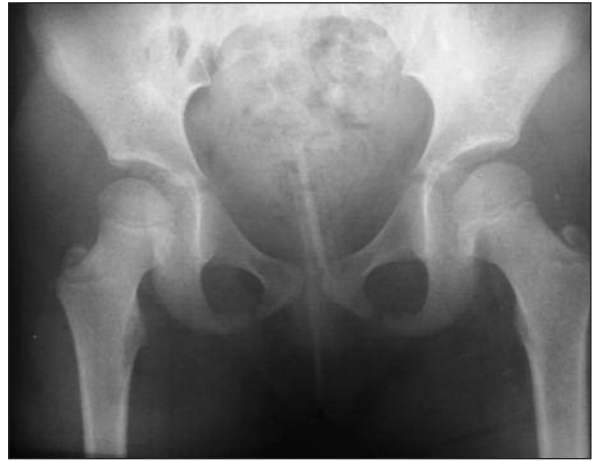

FIGURE 1: X-ray of pelvis showing a thin and long dense image in pelvic region.

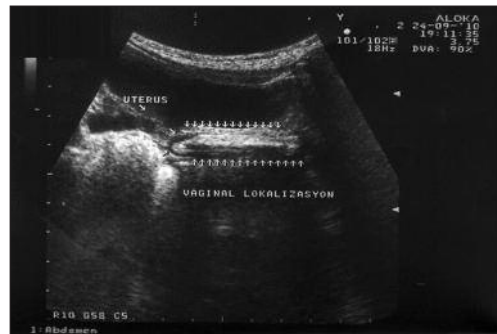


FIGURE 2: Vaginal foreign body, ultrasound image.

intervention finished. 50 mg/kg oral ampicillin was prescribed to be used for 5 days. It was observed that complaints improved on 3rd day of treatment and, completely disappeared one week later.

DISCUSSION

Rectal foreign bodies lead to rectal or abdominal pain, rectal bleeding, constipation and urinary retention.³ Among rectal foreign bodies in children, the most frequently encountered are thermometer in infants and small toys, crayons, crayons and batteries in older children.^{4,5}

In our case, rectal foreign body was thrown out through defecation and although it caused minimal bleeding during this process, other complications did not develop. While rectal foreign body was thrown out through defecation causing mini-

mal bleeding vaginal foreign body was not recognized and staying at vagina caused vaginal discharge.

Vaginal foreign bodies may present with a greenish, bloody, and foul-smelling discharge.⁶ The most frequently seen vaginal bodies in children are toilet paper, clothes and carpet fibers.⁷ These foreign bodies may find their way to vagina spontaneously. The second most common foreign bodies are usually crayons, lids of pens and pastel paints.⁴ It is established that children insert these foreign bodies into their vagina during exploration of their bodies.

In the literature, there are publications reporting that suppositories used to decrease fever were pushed into vagina.⁸

The child mentioned, inserted crayons into her vagina and rectum since she was influenced by emergency department nurse who inserted rectal suppository into her rectum. In a way she wanted to pretend the nurse and also discover her body as playing at home by herself. We concluded that it was not a sexual abuse case since we couldn't get any supportive findings in physical examination and by questioning the family.

Sometimes foreign bodies could stay long without being recognized and cause serious complications such as without being recognized foul smelling, yellow green vaginal discharge, intermittent genital bleeding or dysurea. Another quite important finding occurring rarely is secondary vaginal atresia, which usually arises as a complication. In the case presented by Deborah et al., it was reported that foreign body which remained in vagina for a long time has caused vaginal fibrous adhesions.⁹

In conclusion, children, in whom rectal foreign body was detected, should also be examined for vaginal foreign body in order to prevent further complications. In addition, for patients presenting with the complaint of long lasting foul smelling vaginal discharge or bleeding, foreign body should be kept in mind and imaging methods should be used accordingly.

PREVENTION

Parents and caregivers should be cautioned not to leave small objects around children and children must not be left unsupervised. This is especially important at times of holidays, parties and big gatherings.

REFERENCES

1. Bacon JL. Pediatric vulvovaginitis. *J Pediatr Adolesc Gynecol* 1989;2(2):86-93.
2. Hesham A-Kader H. Foreign body ingestion: children like to put objects in their mouth. *World J Pediatr* 2010;6(4):301-10.
3. Goldstein DP, Pinsonneault O. Pediatrics and Adolescent Gynecology. In: Danforth ND, Scott RJ, eds. *Obstetrics Gynecology*. 5th ed. Philadelphia: Lippincott Williams & Wilkins; 1986. p.853-4.
4. Paradise JE, Willis ED. Probability of vaginal foreign body in girls with genital complaints. *Am J Dis Child* 1985;139(5):472-6.
5. Azman B, Erkuş B, Güvenç BH. Balloon extraction of a retained rectal foreign body under fluoroscopy, case report and review. *Pediatr Emerg Care* 2009;25(5):345-7.
6. Moraloğlu S, Türkyılmaz Z. [Pediatric gynecologic emergencies]. *Türkiye Klinikleri J Surg Med Sci* 2007;3(15):77-82.
7. Henderson PA, Scott RB. Foreign body vaginitis caused by toilet tissue. *Am J Dis Child* 1966;111(5):529-32.
8. Striegel AM, Myers JB, Sorensen MD, Funnell PD, Koyle MA. Vaginal discharge and bleeding in girls younger than 6 years. *J Urol* 2006;176(6 Pt 1):2632-5.
9. Simon DA, Berry S, Brannian J, Hansen K. Recurrent, purulent vaginal discharge associated with longstanding presence of a foreign body and vaginal stenosis. *J Pediatr Adolesc Gynecol* 2003;16(6):361-3.