

Occipital Ganglioglioma: A Case Report and A Short Review

Oksipital Ganglioglioma: Olgu Sunumu ve Kısa Gözden Geçirme

Mehmet Bülent ÖNAL, MD,^a
Fırat NARİN, MD,^b
Hakan ORUÇKAPTAN, MD^b

^aDepartment of Neurosurgery,
GATA,

^bDepartment of Neurosurgery,
Hacettepe University
Faculty of Medicine, Ankara

Geliş Tarihi/Received: 05.12.2009
Kabul Tarihi/Accepted: 04.08.2010

Yazışma Adresi/Correspondence:
Mehmet Bülent ÖNAL, MD
GATA,
Department of Neurosurgery, Ankara
TÜRKİYE/TURKEY
bulentonal@hotmail.com

ABSTRACT Gangliogliomas are uncommon slow-growing benign tumors of the central nervous system. They are frequently localized in temporal lobes and frequently seen during childhood. Our case differs from the cases reported in literature in respect to localization, congenital landmarks and age of presentation. We should keep in mind that gangliogliomas can take place in the occipital lobe rarely, and in older ages. The patient in this report admitted to our hospital with a seizure, which is usual for gangliogliomas. He was older when compared to the ganglioglioma patients reported in the literature with some congenital abnormalities. Three years after gross-total resection, patient still does not have contrast agent enhancement in the control magnetic resonance imaging scans. Congenital malformations can be informative for gangliogliomas in the future if this case is supported by some others.

Key Words: Occipital lobe; ganglioglioma; congenital abnormalities

ÖZET Gangliogliomalar santral sinir sisteminin az görülen yavaş büyüyen benign tümörleridir. Genellikle temporal loblarda yerleşir ve sık olarak çocukluk çağında görülürler. Bu olgu literatürdeki olgulardan yerleşim, konjenital işaretler ve ortaya çıkma yaşı olarak farklılık göstermektedir. Gangliogliomaların ender olarak oksipital lobta yer alabileceği ve aynı zamanda daha ileri yaşlarda da ortaya çıkabileceğini akılda tutmalıyız. Bu rapordaki hasta hastaneye gangliogliomalar için alınmış olan epileptik atak şikâyeti ile başvurdu. Bu olgu konjenital anormallikleri olan literatürdeki olgulara göre daha ileri yaşta bir hastadır. Gross total rezeksiyondan üç yıl sonra kontrol manyetik rezonans taramalarında kontrast ajan artışı bulunmuyordu. Bu olgular diğerleri ile desteklenirse konjenital malformasyonlar gangliogliomalar hakkında bilgi verici olabilirler.

Anahtar Kelimeler: Oksipital lob; gangliogliom; doğumsal anomaliler

Türkiye Klinikleri J Med Sci 2011;31(1):215-20

Central nervous system (CNS) tumors containing nerve cells are infrequent neoplasms and account for approximately 2% of all brain tumors.¹⁻³ Gangliogliomas are uncommon slow-growing benign tumors of the CNS, they consist of a mixture of two cell types that are ganglion cells and glial cells.⁴ Although ganglion cells express markers of nerve cell differentiation, glial cells express mostly astrocytic markers.¹ Although most tumors are localized in the temporal lobe, these tumors may involve anywhere in the CNS such as spinal cord, brain stem, third and fourth ventricles, cerebellum, pineal region, thalamus, intrasellar region and optic nerve.^{5,6}

Gangliogliomas are usually seen in childhood and frequently localized in temporal lobes.

CASE REPORT

A 32-year-old man admitted to our clinic with the complaint of generalized seizures in the previous 6 months. The patient had an uneventful medical and social history. He denied any evidence of epilepsy and trauma previously. His physical and neurological examination were in normal limits except for his congenital deformities mainly involving the extremities. He had multiple finger deformities with agenesis of distal and medial phalanges on 4th and 5th fingers of the left hand as well as the absence of distal and medial phalanges of the 5th finger on the right hand. He had overriding fourth toes and rudimentary 3rd and 5th toes on the right side (Figure 1). He had valgus deformities at his feet as well as a barrel chest deformity, hypertelorism and low hair line over the neck. The results of his blood counts and biochemical evaluation were normal.

Computerized tomography (CT) study revealed a large calcified occipital lesion on the left side

(Figure 2A-2C). Magnetic resonance imaging (MRI) study showed a 6×8×8 cm mass with little gadolinium (Gd) enhancement. The tumor had low echo intensity on T1- weighted (W) and high echo intensity on T2-W images. Islands of high signal intensity in T2-W and low signal intensity in T1-W and FLAIR images represented the calcified areas of tumor (Figure 2D-2G). The mass effect of the tumor was unexpectedly minimal with slight compression of the left lateral ventricle and mild surrounding edema.

On the third day of admission, after an informed consent was obtained from the patient, he underwent surgery through left occipital craniotomy. The tumor with occasional calcified islands and low vascular supply was removed totally. The postoperative course was uneventful and he was discharged in a few days after surgery.

Histopathological examination showed a neoplasm with spindle glial cells and atypical ganglionic cells as well as dense calcified component embedded in a fibrovascular stroma. Strong reactivity of ganglionic cells to synaptophysin, chromogranin and CD34 and GFAP positivity in stromal

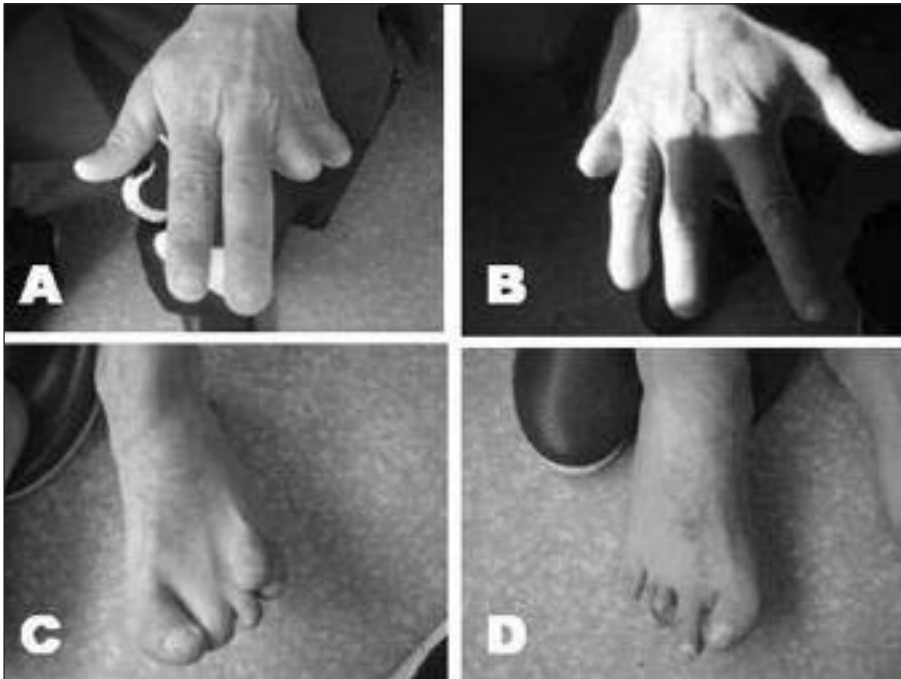


FIGURE 1: Multiple congenital limb deformities of the patient are demonstrated.

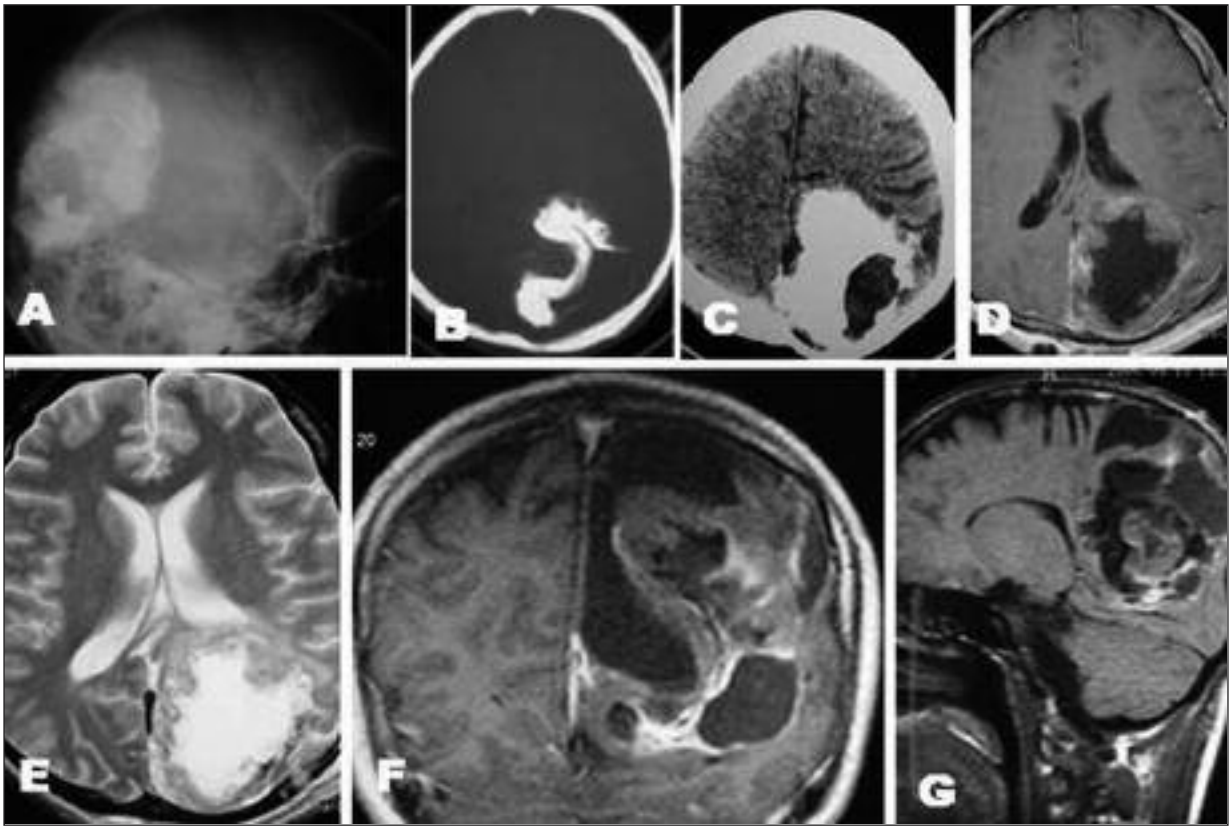


FIGURE 2: Preoperative imaging studies **A**, cranial CT bone window **B**, parenchyma **C**, T1- W Gd- enhanced axial MRI **D**, T2- W axial MRI (**E**), T1- W Gd- enhanced coronal **F**, T1- W sagittal **G** MRI images revealed calcification in occipital lobe are arranged in order. CT features show hypodense and calcified tumor presenting little contrast enhancement. MRI features show the lesion hypointense on T1- WI whereas high signal intensity on T2- WI. Tumor shows minimal mass effect or peritumoral edema.

glial cells were evident on immunocytochemical evaluation. Ki-67 proliferation index was below %1 throughout the lesion. Under the light of these findings, the diagnosis of a well-differentiated ganglioglioma (WHO grade I) was made.

Except the glial reactivity around the surgical cavity, radiological studies during the last follow up which is three years after resection, showed neither signs of recurrence nor a residual lesion (Figure 3). His antiepileptic treatment was tapered gradually and he is still seizure-free since the operation.

DISCUSSION

Gangliogliomas are unusual tumors of the CNS and contain a mixture of neoplastic glial and well-differentiated ganglion cells. These tumors were first described by Courville in 1930.⁷ Gangliogliomas are

usually seen in childhood and adolescence, however its manifestation can be delayed until the third decade of life.^{1,3,8} The overall incidence of these tumors varies between 0.4% and 1.7%, however can be as high as 7.6% in childhood period due to its high penetrance.⁹⁻¹²

These tumors are usually located supratentorially with a predilection to temporal lobes, however they may be found in all parts of the CNS.^{3,5,13} Involvement of the occipital region is quite rare in the clinical practice, as the case presented.^{1,5,8,14-18}

Seizure is the most common presenting symptom, which is usually (40%) chronic temporal lobe epilepsy.¹⁹

Gangliogliomas are classified as grade I and II according to recent World Health Organization (WHO) classification system. On the other hand

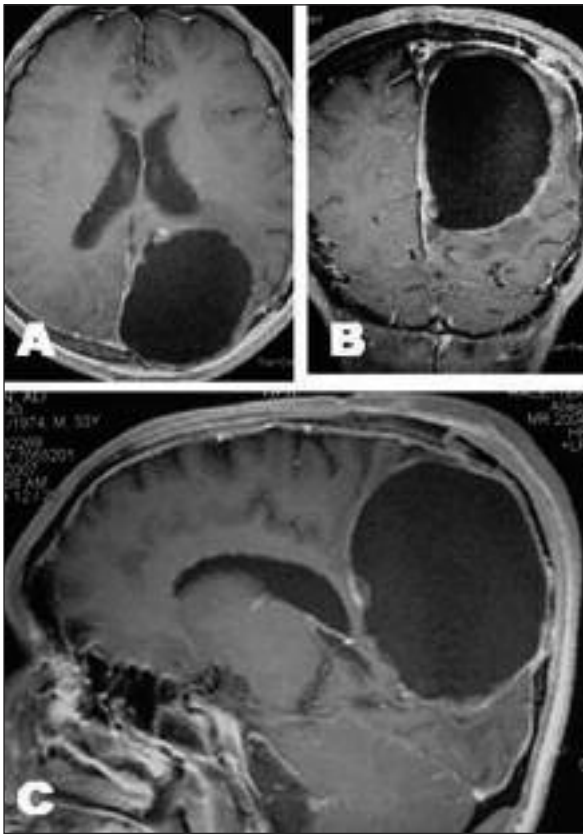


FIGURE 3:T1-W Gd-enhanced axial (A), coronal (B) and sagittal (C) MRI images show only reactive gliosis around the surgical cavity but any signs of recurrence three years after surgery.

gangliogliomas showing anaplastic glial components are defined as grade III (anaplastic gangliogliomas).¹⁹ Gangliogliomas are slow growing benign tumors of the CNS, although malignant variants are rarely seen.^{8,20} Malignant progression incidence according to WHO classification is 6% in grade I and 20% in grade III gangliogliomas.²¹

The histopathological diagnosis of ganglioglioma requires the presence of neoplastic neuronal and glial cells. The glial component of a ganglioglioma is usually composed of low grade astrocytes, fibrillary or pilocytic cells; however cases with oligodendroglial component have also been reported.³ Ganglion cells express markers of nerve cell differentiation such as the presence of Nissl substance and axon or dendrites.¹ Nissl substance can be demonstrated with cresyl violet staining.²⁰

Immunohistochemical markers such as synaptophysin, neurofilament protein and NeuN are used to characterize the dysplastic nature of neurons in areas where distinguishing normal brain parenchyma from neoplastic lesion is difficult. Glial fibrillary acidic protein (GFAP) is used to identify astrocytic elements and Ki67 index is used for proliferative activity in neoplastic cells. Although gangliogliomas display considerable morphologic heterogeneity with respect to neuronal and glial phenotypes, immunohistochemical detection of CD34 and low Ki67 indices often can be used to confirm the diagnosis.²² Perifocal occurrence of CD34 immunoreactivity is highly suggestive of a ganglioglioma, which was positive in our case.^{21,23,24}

Patient in current case has some congenital anomalies of the limbs. We believe this association is coincidental and probably indicates a rare condition affecting the limbs. These congenital malformations can be informative in the future if this association is supported with more cases. Individual cases have been described in association with a family history of neurofibromatosis, Peutz-Jeghers syndrome and Turcot syndrome.²¹ An association is found with genetic malformations such as Down syndrome, partial agenesis of the corpus callosum and cerebellar micropolygyria.^{7,13,20} In addition, congenital abnormalities such as thyroglossal duct, tracheoesophageal fistula, and pulmonic stenosis accompanied by an atrial septal defect have also been report.⁷ Although no genetic disease was found in our case, the patient present with many congenital abnormalities. To our best knowledge, this association has not been previously reported (Figure 1). These congenital malformations may have a relation with the ganglioglioma and may be considered as landmarks.

Radiological diagnosis of any CNS tumors includes CT and MRI scans. In the literature, CT usually shows a hypodense tumor (40%) presenting little contrast enhancement (80%). Calcification is documented approximately in 20-50% of all patients and cystic tumors are reported in 40% of patients.^{7,19} MRI scanning is more sensitive than CT scanning in demonstrating noncalcified tumors; and more precise in identifying tumors when com-

pared to CT scan. Gangliogliomas are isointense or hypointense on T1-WI whereas high signal intensity on T2-WI is reported in literature in the majority of patients. Gadolinium enhancement shows various nonspecific patterns. Gangliogliomas, especially the ones without cystic components, usually show no mass effect or peritumoral edema.¹⁹

The prognosis is favorable in most patients with intracranial ganglioglioma. Many patients can expect to be cured from their tumors as well as from their epilepsy. However some patients will suffer from recurrent tumor and/ or malignant progression.

In most series, recurrences were noted 1-3 years after surgery; however late recurrences and malignant transformations may be seen even 5-11 years after surgery. Unlike diffuse gliomas, the benefit of radiotherapy is unclear. Routine radiotherapy is not indicated after subtotal resection of low-

grade gangliogliomas. Prolonged follow up is necessary after gross total resection or subtotal removal of low grade gangliogliomas. Postoperative radiotherapy is necessary after subtotal resection of high grade gangliogliomas. It is generally agreed that subtotally resected gangliogliomas should be treated with radiotherapy when there is documented progression or if the astrocytic component shows malignant characteristics.^{7-9,21-23} Estimated occurrence of malignant transformation is about %6. Malignant transformation is usually associated with incomplete tumor resection and radiation therapy in some cases.^{11,19,21}

A lesion presenting iso- hypo intensity in gray matter on T1- WI without a mass effect in temporal lobe of a young patient with seizures may be the characteristic imaging in gangliogliomas. We should keep in mind that gangliogliomas may involve the occipital lobe.

REFERENCES

- Kalyan-Raman UP, Olivero WC. Ganglioglioma: a correlative clinicopathological and radiological study of ten surgically treated cases with follow-up. *Neurosurgery* 1987;20(3):428-33.
- Lagares A, Gómez PA, Lobato RD, Ricoy JR, Ramos A, de la Lama A. Ganglioglioma of the brainstem: report of three cases and review of the literature. *Surg Neurol* 2001;56(5): 315-22.
- Nair V, Suri VS, Tatke M, Saran RK, Malhotra V, Singh D. Gangliogliomas: A report of five cases. *Indian J Cancer* 2004;41(1):41-6.
- Garcia CA, McGarry PA, Collada M. Ganglioglioma of the brain stem. Case report. *J Neurosurg* 1984;60(2):431-4.
- Demierre B, Stichnoth FA, Hori A, Spoerri O. Intracerebral ganglioglioma. *J Neurosurg* 1986;65(2):177-82.
- Çelik F, Kandemir B, Bilal S. [Cerebellar ganglioglioma]. *Turkiye Klinikleri J Med Res* 1988;6(3):195-8.
- Haddad SF, Moore SA, Menezes AH, VanGilder JC. Ganglioglioma: 13 years of experience. *Neurosurgery* 1992;31(2): 171-8.
- Kang DH, Lee CH, Hwang SH, Park IS, Han JW, Jung JM. Anaplastic ganglioglioma in a middle-aged woman: a case report with a review of the literature. *J Korean Med Sci* 2007;22(Suppl):S139-44.
- Im SH, Chung CK, Cho BK, Wang KC, Yu IK, Song IC, et al. Intracranial ganglioglioma: pre-operative characteristics and oncologic outcome after surgery. *J Neurooncol* 2002;59(2):173-83.
- Johannsson JH, Rekatte HL, Roessmann U. Gangliogliomas: pathological and clinical correlation. *J Neurosurg* 1981;54(1):58-63.
- Karremann M, Pietsch T, Janssen G, Kramm CM, Wolff JE. Anaplastic ganglioglioma in children. *J Neurooncol* 2009;92(2):157-63.
- Sutton LN, Packer RJ, Rorke LB, Bruce DA, Schut L. Cerebral gangliogliomas during childhood. *Neurosurgery* 1983;13(2): 124-8.
- Celli P, Scarpinati M, Nardacci B, Cervoni L, Cantore GP. Gangliogliomas of the cerebral hemispheres. Report of 14 cases with long-term follow-up and review of the literature. *Acta Neurochir (Wien)* 1993;125(1-4):52-7.
- Bruni P, Ierardi A, Albrizio M. [Right temporo-occipital ganglioglioma in a 10-year-old patient]. *Pediatr Med Chir* 1983;5(1-2): 137-9.
- Campos MG, Zentner J, Ostertun B, Wolf HK, Schramm J. Anaplastic ganglioglioma: case report and review of the literature. *Neurol Res* 1994;16(4):317-20.
- Demaerel P, Droessaert M, Lammens M, Menten J, Nuttin B, Verbeeck R, et al. Anaplastic (malignant) ganglioglioma arising from heterotopic grey matter nodules. *J Neurooncol* 1996;30(3):237-42.
- Fletcher WA, Hoyt WF, Narahara MH. Congenital quadrantanopia with occipital lobe ganglioglioma. *Neurology* 1988;38(12):1892-4.
- Kurian NI, Nair S, Radhakrishnan VV. Anaplastic ganglioglioma: case report and review of the literature. *Br J Neurosurg* 1998;12(3):277-80.
- Adachi Y, Yagishita A. Gangliogliomas: Characteristic imaging findings and role in the temporal lobe epilepsy. *Neuroradiology* 2008;50(10):829-34.
- Russell DS, Rubinstein LJ. *Pathology of Tumors of The Nervous System*. 5th ed. Baltimore: Williams&Wilkins; 1989. p.289-307.
- Majores M, von Lehe M, Fassunke J, Schramm J, Becker AJ, Simon M. Tumor recurrence and malignant progression of gangliogliomas. *Cancer* 2008;113(12):3355-63.

22. Luyken C, Blümcke I, Fimmers R, Urbach H, Wiestler OD, Schramm J. Supratentorial gangliogliomas: histopathologic grading and tumor recurrence in 184 patients with a median follow-up of 8 years. *Cancer* 2004;101(1):146-55.
23. Selch MT, Goy BW, Lee SP, El-Sadin S, Kincaid P, Park SH, et al. Gangliogliomas: experience with 34 patients and review of the literature. *Am J Clin Oncol* 1998;21(6):557-64.
24. Wolf HK, Müller MB, Spänle M, Zentner J, Schramm J, Wiestler OD. Ganglioglioma: a detailed histopathological and immunohistochemical analysis of 61 cases. *Acta Neuropathol* 1994;88(2):166-73.