

# An Unusual Association: Duodenal Atresia and Jejunoileal Atresia with “Apple Peel” Configuration: Case Report

## Alışılmadık Bir Birliktelik: Duodenal Atrezi ve “Apple Peel” Tipinde Jejunoileal Atrezi

Halil İbrahim TANRIVERDİ,<sup>a</sup>  
Ufuk ŞENEL<sup>a</sup>

<sup>a</sup>Department of Pediatric Surgery,  
Gaziosmanpaşa University  
Faculty of Medicine, Tokat

Geliş Tarihi/Received: 21.03.2013  
Kabul Tarihi/Accepted: 30.08.2013

Yazışma Adresi/Correspondence:  
Halil İbrahim TANRIVERDİ  
Gaziosmanpaşa University  
Faculty of Medicine,  
Department of Pediatric Surgery, Tokat,  
TÜRKİYE/TURKEY  
halilibrahimtanriverdi@gmail.com

**ABSTRACT** Duodenal atresia is believed to be the result of incomplete recanalization of the embryonic foregut, whereas “apple peel” jejunoileal atresia has been attributed to a prenatal vascular accident to the superior mesenteric artery. Association of a duodenal and jejunoileal atresia with an “apple peel” configuration of the remaining small bowel is very rare due to the significantly different etiology. This association raises questions about embryology of these anomalies. We report a rare case of duodenal atresia with “apple peel” configuration of remaining small bowel with absent superior mesenteric artery, and also agenetic ears, agenetic forearms, penoscrotal hypospadias and renal fusion anomaly accompanied.

**Key Words:** Intestinal atresia; embryology; congenital abnormalities

**ÖZET** Duodenal atrezinin, embriyonik dönemde önbarsağın yetersiz rekanalizasyonu sonucu geliştiğine inanılırken “apple peel” tipindeki jejunoileal atrezinin, prenatal dönemde superior mezenterik arterdeki vasküler kazalar sonucu geliştiği düşünülmektedir. Bu belirgin farklı etyolojilerinden dolayı duodenal atrezi ile “apple peel” tipindeki jejunoileal atrezinin birlikteliği oldukça nadirdir. Bu birliktelik, adı geçen anomalilerin embriyolojileri hakkında şüphelerin ortaya çıkmasına neden olmaktadır. Duodenal atrezi ve superior mezenterik arterin yokluğu ile birlikte “apple peel” tipindeki jejunoileal atrezinin saptandığı, ayrıca agenetik kulakları, agenetik önkol-ları, penoskrotal hipospadiasi ve renal füzyon anomalisi olan nadir bir yenidoğan olgu sunulmuştur.

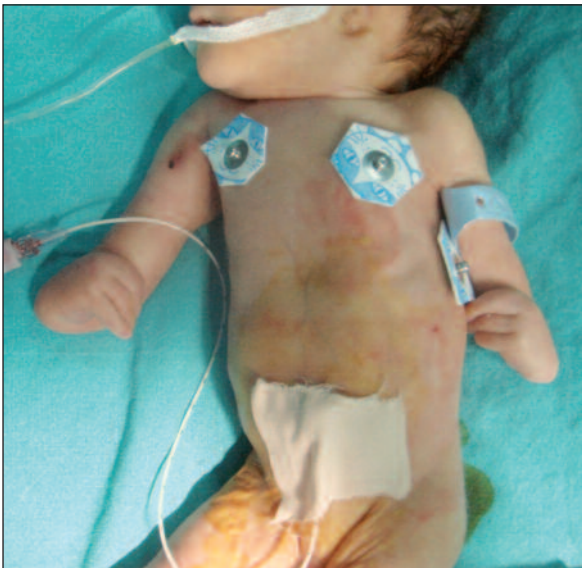**Anahtar Kelimeler:** Barsak atrezisi; embriyoloji; doğumsal anomaliler

**Türkiye Klinikleri J Case Rep 2013;21(4):182-5**

**D**uodenum is the most common site of the neonatal obstruction.<sup>1</sup> Incidence of duodenal atresia has been estimated at 1 in 6000 to 1 in 10 000 births.<sup>2</sup> Duodenal atresia is believed to be the result of incomplete recanalization of the embryonic foregut, whereas “apple peel” jejunoileal atresia has been attributed to a prenatal vascular accident to the superior mesenteric artery.<sup>3-8</sup> Association of a duodenal and jejunoileal atresia with an “apple peel” configuration of the remaining small bowel is very rare due to the significantly different etiology, and raises questions on the etiology of duodenal atresia. We report a rare case of duodenal atresia with “apple peel” configuration of remaining small bowel with absent superior mesenteric artery, and also agenetic ears, agenetic forearms, penoscrotal hypospadias and renal fusion anomaly accompanied.

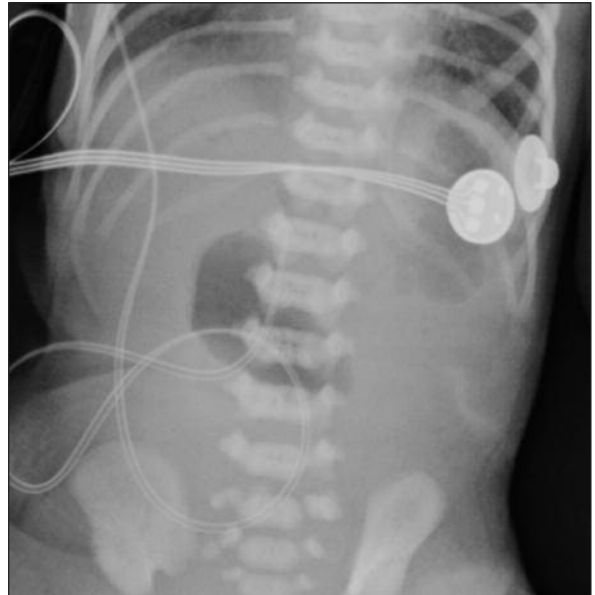## CASE REPORT

A 29 week gestation, 1230 g baby was born from 25 years old mother because of premature rupture of membrane. This was the third pregnancy of the mother and the other children were healthy. There was no teratogenic contact and infection during pregnancy. Antenatal ultrasound scan of the baby showed a distended stomach and duodenum with a “double bubble” sign. The baby had also agenetic ears, agenetic forearms and penoscrotal hypospadias (Figure 1). Plain radiograph of the abdomen showed the classic “double bubble” sign (Figure 2). Renal fusion anomaly was determined at ultrasonography. Laparotomy showed a dilated first and second parts of duodenum. The distal third and fourth parts of the duodenum as well as the proximal jejunum were absent. The remaining small bowel assumed a helical configuration around a single marginal artery, with a typical “apple peel” configuration. The mesenteric artery was absent. There was a wide mesenteric gap between duodenum and jejunal remnant (Figure 3). The duodenum was anastomosed to the hypoplastic jejunum. A revision was performed for anastomosis leak, but baby succumbed also with potency of very low birth weight and prematurity.

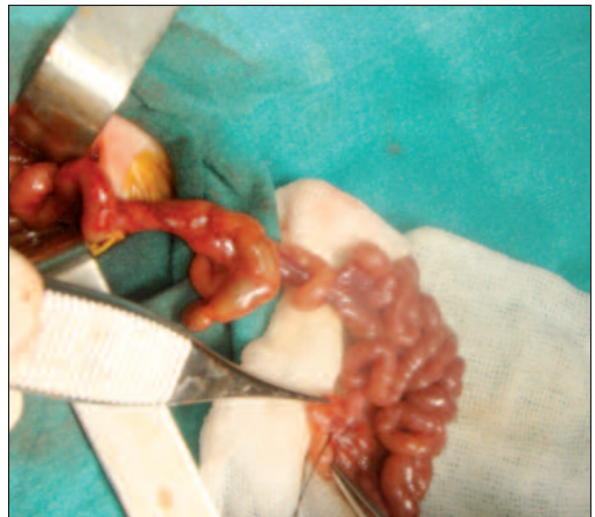


**FIGURE 1:** Patient's general outlook.

(See color figure at <http://www.turkiyeklinikleri.com/journal/turkiye-klinikleri-journal-of-case-reports/1300-0284/tr-index.html>)



**FIGURE 2:** Double bubble at plain abdominal graphy



**FIGURE 3:** Apple peel jejunoileal atresia.

(See color figure at <http://www.turkiyeklinikleri.com/journal/turkiye-klinikleri-journal-of-case-reports/1300-0284/tr-index.html>)

## DISCUSSION

Embryologically, after the formation of intestinal canal, the developing embryonic foregut goes a complete solid core stage that subsequently vacuolises.<sup>9</sup> Duodenal atresia is related to failure of recanalisation of the solid stage of developing embryonic foregut, as described by Tandler in

1900.<sup>10</sup> Jejunoileal atresia is result from interruption of vascular supply to the atretic bowel segment.<sup>11</sup> In 1961, Santulli and Blanc used the term "apple peel atresia" for the first time.<sup>12</sup> Apple peel atresia consist of high jejunal atresia with a wide gap in the mesentery. The distal segment of ileum is shortened and assumes a helical configuration around a retrograde perfusing vessel, which compensates for the partially absent superior mesenteric artery. Our patient had an atretic third and fourth part of duodenum and also the proximal jejunum. The remaining small bowel had a helical configuration around a single marginal artery, with a typical "apple peel" configuration. The mesenteric artery was absent. Also here was a wide mesenterial gap between duodenum and jejunal remnant.

The recanalization theory is widely accepted in duodenal atresia.<sup>5,8,10,13</sup> An intrauterine vascular accident has been accepted as the cause of apple peel atresia and presents with a spectrum of occlusions of one or more branches of the superior mesenteric artery.<sup>8,14,15</sup> The dual vascular supply of the duodenum, originating from the celiac axis and SMA, explain why apple peel atresia do not involve the duodenum according to the conventional concept. The third part of duodenum is fed by inferior pancreaticoduodenal artery, which is the first branch of the superior mesenteric artery. The two thirds of

the duodenum is fed by the superior pancreaticoduodenal artery, which is the branch of gastroduodenal artery, a main branch of celiac artery.<sup>16</sup> The association of duodenal atresia and apple peel jejunoileal atresia is impossible to traditional opinion. There are a few reports -one of them is our report- about the association of these anomalies.<sup>17,18</sup> Also association between intestinal atresia with pyloric atresia which has the same embryologic theory with duodenal atresia, is rare.<sup>19</sup> This association raises questions about embryology of these anomalies.

Duodenal atresia, especially in the presence of associated abnormalities has a high perinatal mortality.<sup>20</sup> Congenital duodenal obstruction of the newborn is frequently complicated by prematurity, low birth weight and other associated anomalies.<sup>21</sup> Our patient died because of very low birth weight, prematurity and associated anomalies.

The current case suggests, however, that the today's embryological theory of duodenal atresia and apple peel jejunoileal atresia is inadequate. In this case, did duodenal and jejunoileal atresia occurred because of vascular accident or failure of recanalization, perhaps a different theory? Also this case is the one with addition anomalies such as agenetic ears, agenetic forearms, penoscrotal hypospadias and renal fusion anomaly.

## REFERENCES

- Dalla Vecchia LK, Grosfeld JL, West KW, Rescorla FJ, Scherer LR, Engum SA. Intestinal atresia and stenosis: a 25-year experience with 277 cases. *Arch Surg* 1998;133(5):490-6; discussion 496-7.
- Fonkalsrud EW, DeLorimier AA, Hays DM. Congenital atresia and stenosis of the duodenum. A review compiled from the members of the Surgical Section of the American Academy of Pediatrics. *Pediatrics* 1969;43(1):79-83.
- Gross E, Armon Y, Abu-Dalu K, Gale R, Schiller M. Familial combined duodenal and jejunal atresia. *J Pediatr Surg* 1996;31(11):1573.
- Lister J, Irving I, Rickham PP. Duodenal atresia and stenosis: Annular pancreas. In: Lister J, Irving IM, eds. *Neonatal Surgery*. 2<sup>nd</sup> ed. Boston: Butterworths; 1990. p.424-41.
- Lambrecht W, Kluth D. Hereditary multiple atresias of the gastrointestinal tract: report of a case and review of the literature. *J Pediatr Surg* 1998;33(5):794-7.
- Leonidas JC, Amoury RA, Ashcraft KW, Fellows RA. Duodenojejunal atresia with "apple-peel" small bowel. A distinct form of intestinal atresia. *Radiology* 1976;118(3):661-5.
- Seashore JH, Collins FS, Markowitz RI, Seashore MR. Familial apple peel jejunal atresia: surgical, genetic, and radiographic aspects. *Pediatrics* 1987;80(4):540-4.
- Lister J, Irving I, Rickham PP. Intestinal atresia and stenosis, excluding the duodenum. In: Lister J, Irving IM, eds. *Neonatal Surgery*. 2<sup>nd</sup> ed. Boston: Butterworths; 1990. p.453-73.
- Weber DM, Freeman NV. Duodenojejunal atresia with apple peel configuration of the ileum and absent superior mesenteric artery: observations on pathogenesis. *J Pediatr Surg* 1999;34(9):1427-9.
- Tandler J. [Evolutionary history of the human duodenum in early embryonic stages]. *Morph Jahrb* 1900; 29(4): 187-216.
- Louw JH, Barnard CN. Congenital intestinal atresia; observations on its origin. *Lancet* 1955;269(6899):1065-7.
- Santulli TV, Blanc WA. Congenital atresia of the intestine: pathogenesis and treatment. *Ann Surg* 1961;154:939-48.

13. Moutsouris C. The "solid stage" and congenital intestinal atresia. *J Pediatr Surg* 1966;1(5): 446-50.
14. Olson LM, Flom LS, Kierney CM, Shermeta DW. Identical twins with malrotation and type IV jejunal atresia. *J Pediatr Surg* 1987;22 (11):1015-6.
15. Martin LW, Zerella JT. Jejunoileal atresia: a proposed classification. *J Pediatr Surg* 1976;11(3):399-403.
16. Ernst CE. Anatomy and collateral pathways of the mesenteric circulation. In: Zuidema GD, ed. *Shackelford's Surgery of the Alimentary Tract*, Vol. 15. Philadelphia, PA: Saunders; 1996. p.3-9.
17. Weber DM, Freeman NV. Duodenojejunal atresia with apple peel configuration of the ileum and absent superior mesenteric artery: observations on pathogenesis. *J Pediatr Surg* 1999;34(9):1427-9.
18. Ahmad A, Sarda D, Joshi P, Kothari P. Duodenal atresia with 'apple-peel configuration' of the ileum and absent superior mesenteric artery: a rare presentation. *Afr J Paediatr Surg* 2009;6(2):120-1.
19. Sencan A, Mir E, Karaca I, Günşar C, Sencan A, Topçu K. Pyloric atresia associated with multiple intestinal atresias and pylorochole- dochal fistula. *J Pediatr Surg* 2002;37(8): 1223-4.
20. Has R, Batukan C, Ermiş H, Başaran S, Yüksel A, İbrahimoğlu L. [Duodenal atresia: Pre- natal diagnosis and perinatal outcome of 27 fetuses]. *Türkiye Klinikleri J Gynecol Obst* 2001;11(4):209-14.
21. Karaca İ, Şencan A, Süzen A, Etensel B, Günşar C, Mir E. [Congenital duodenal ob- struction: An 8 year review]. *Türkiye Klinikleri J Gastroenterohepatol* 2000;11(2):61-4.