

Leiomyoma of the Renal Pelvis

RENAL PELVİSTE LEİOMYOMA

Çağatay GÖĞÜŞ*, Sümer BALTACI**, Diclehan ORHAN***, Kadir TÜRKÖLMEZ**

* Urologist, Dept. of Urology, Ankara University, School of Medicine

** Assoc.Prof., Dept. of Urology, Ankara University, School of Medicine

*** Assoc.Prof., Dept. of Pathology, Ankara University, School of Medicine, ANKARA

Summary

Purpose: Leiomyoma of the renal pelvis is an extremely rare benign tumor. Herein, we report a case of leiomyoma arising from the right renal pelvis. To our knowledge this is the eighth case, reported in the world literature.

Case Report: A 38-year-old woman. Presented with right lumbar pain. An excretory urogram revealed a filling defect in the right renal pelvis. The patient had undergone a right nephroureterectomy with preoperative diagnosis of transitional cell carcinoma and the pathological examination revealed renal pelvis leiomyoma.

Results: Although its rarity and difficulty in correct preoperative diagnosis, leiomyoma of the renal pelvis should be included in the list of differential diagnosis of renal pelvis pathologies.

Key Words: Leiomyoma, Renal pelvis, Tumor

T Klin J Med Sci 2003, 23:483-485

Özet

Amaç: Renal pelviste leiomyoma çok nadir görülen benign bir tümördür. Olgu sunumuzda, sağ renal pelvisten kaynaklanan bir leiomyoma vakası takdim edilmektedir. Bilgimize göre vaka dünya literatüründeki sekizinci vakadır.

Olgu Sunumu: Otuz sekiz yaşında bayan hasta sağ lumbar ağrı şikayeti ile başvurdu. İntravenöz pyelografide sağ renal pelviste dolma defekti izlendi. Preoperatif olarak transizyonel hücreli kanser tanısı alan hastaya sağ nefroureterektomi uygulandı ve renal pelvis leiomyomu tanısı patolojik inceleme sonrası konuldu.

Sonuç: Çok nadir görülmesine ve preoperatif dönemde tanı konulmasının zorluğuna rağmen renal pelviste leiomyoma renal pelvis patolojilerinin ayırıcı tanısında mutlaka akılda tutulmalıdır.

Anahtar Kelimeler: Leiomyoma, Renal pelvis, Tümör

T Klin Tıp Bilimleri 2003, 23:483-485

Leiomyoma is a rare benign tumor containing smooth muscle. Although it may be seen in every part of the genitourinary tract, leiomyoma of the renal pelvis is extremely rare and to our knowledge only 7 cases have been reported in literature (1-5). The most difficult problem with renal pelvis leiomyoma is the accurate preoperative diagnosis. A case of leiomyoma arising from the right renal pelvis in a 38-year-old woman was presented.

Case Report

A 38-year-old woman presented with right flank pain. Physical examination was normal. Laboratory studies revealed a normal hemogram and normal biochemical values. Urinalysis showed microhematuria.

An excretory urogram revealed a filling defect in the right renal pelvis with minimal pyelocaliectasis. There were also small stones in the upper and middle calyces (Figure 1). Computerized tomography (CT) of the abdomen demonstrated a 2 x 1 cm. solid mass at the central part of the right renal pelvis. Right nephroureterectomy was performed because of diagnosis of a transitional cell carcinoma.

Gross examination of the nephrectomy specimen revealed a tumor localized to the renal pelvis measuring 20x18x12 mm. The tumor was a well circumscribed nodular mass with a firm, gray-white solid cut surface. Light microscopic examination of the HE stained sections showed that the tumor cells were arranged in interlacing fascicles and in some areas, there was a whorled pattern. Tumor was composed of cells with fusiform nuclei

and bipolar spindle cytoplasm. Nuclear pleomorphism, atypia and mitosis were absent. Stroma of the tumor was light eosinophilic and hypocellular (Figure 2). Trichrome and Van Gieson stained sections revealed that there was no collagen in the tumor. Immunohistochemically, positive immunostaining was detected in the cytoplasm of the spindle cells with smooth muscle actin, desmin and vimentin. Tumor cells did not show any immunostaining for CD34, S-100 protein, HMB-45 and MIB-1.

The tumor had not recurred 18 months post-operatively.

Discussion

Leiomyoma is a rare benign tumor and may involve any organ of the genitourinary tract. They are usually small and discovered at autopsy. Histologically they are well circumscribed and encapsulated without showing any mitosis or atypia. The kidney is the most affected organ in the genitourinary tract (5).

Leiomyoma of the renal pelvis was first reported by Litzky et al. (1) in 1971 and since then only six more cases have been reported in literature (2-5). Ours is the eight case of leiomyoma arising from the renal pelvis. Most of the patients were women between 24 and 50 years old as in our case (1-4). Yusim et al. reported the first case of renal pelvis leiomyoma in a male (5). The main clinical symptoms are flank pain and/or painless hematuria (1-5). The main problem is accurate preoperative diagnosis and all of the reported cases were treated with nephroureterectomy or radical nephrectomy because of a preoperative diagnosis of malignant tumor except the one that was reported by O'Brien et al. (3). In that case, interestingly there was a cyst formation and a partial nephrectomy was performed. Despite newer imaging modalities it is almost impossible to distinguish renal pelvis leiomyoma from malignant tumors. The diagnosis can only be made after surgical excision and microscopic evaluation. The prognosis is excellent and no extrarenal invasion or metastasis have been reported (1-5).

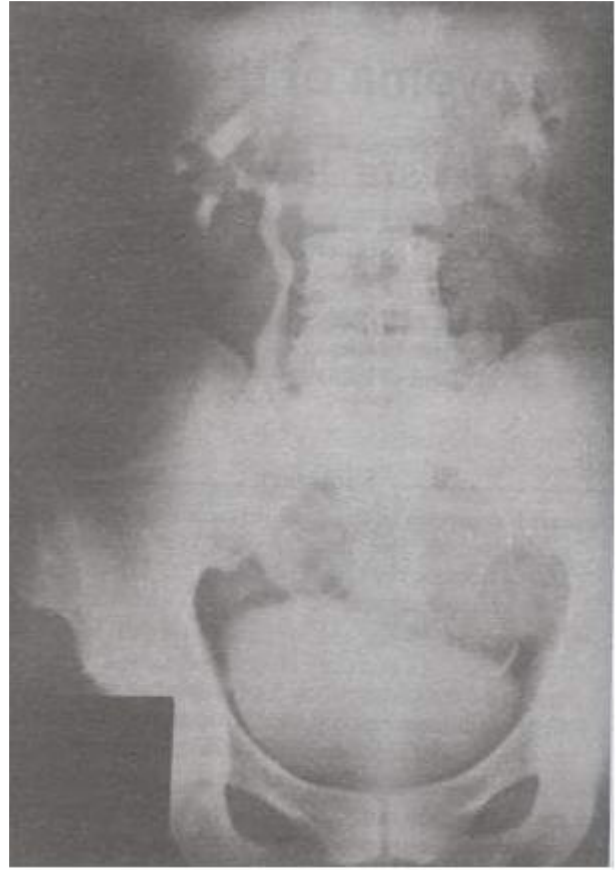


Figure 1. Intravenous pyelography showing a filling defect in right renal pelvis.



Figure 2. Renal pelvic tumor, lying beneath the desquamated mucosa. Few dilated collecting ducts, surrounded by an infiltration of lymphocytes (HEX25).

Leiomyoma should be differentiated histologically from other rare spindle cell tumors

like schwannoma, angiomyolipoma, malign fibrous histiocytoma and solitary fibrous tumor (6-8). In our case, immunohistochemically tumor cells showed positive immunostaining with smooth muscle actin, desmin and vimentin. However, there was no reactivity for CD34, HMB45, S-100 protein and MIB-1 as expected in leiomyomas (4,9) but not in other tumors (6-8). Due to these results our diagnosis was leiomyoma of the renal pelvis.

We think that, leiomyoma should be kept in mind in the differential diagnosis of filling defects of renal pelvis, especially in young females.

REFERENCES

1. Litzky GM, Seidel RF, O'Brien JE. Leiomyoma of the renal pelvis. *J Urol* 1971; 105: 171-3.
2. Uchida M, Watanabe H, Mishina T, Shimada N. Leiomyoma of the renal pelvis. *J Urol* 1981; 125: 572-4.
3. O'Brien A, Sinnott B, McLean P, Doyle GD. Leiomyoma of the renal pelvis. *Brit J Urol* 1992; 70 : 331-2.
4. Kho GT, Duggan MA. Bizarre leiomyoma of the renal pelvis with ultrastructural and immunohistochemical findings. *J Urol* 1996; 141: 928-9.
5. Yusim IE, Neulander EZ, Eidelberg I, Lismer LJ, Kaneti J. Leiomyoma of the genitourinary tract. *Scan J Urol* 2001; 35: 295-9.
6. Yazaki T, Satoh S, Lizumi T, Umeda T, Yamaguchi Y. Solitary fibrous tumor of renal pelvis. *Int J Urol* 2001; 8: 504-8.
7. Micali S, Virgili G, Vespasiani G, Silecchia A, D'Alessandro P, Micali F. Benign shwannoma surrounding and obstructing the ureteropelvic junction. First case report. *Eur Urol* 1997; 32: 121-3.
8. Tarjan M, Cserni G, Szabo Z. Malignant fibrous histiocytoma of the kidney. *Scand J Urol Nephrol* 2001; 35: 518-20.
9. Paal E, Miettinen M. Retroperitoneal leiomyomas: a clinicopathologic and immunohistochemical study of 56 cases with a comparison to retroperitoneal leiomyosarcomas. *Am J Surg Pathol* 2001; 25: 1355-63.

Geliş Tarihi: 13.01.2003

Yazışma Adresi: Dr.Çağatay GÖĞÜŞ
Ankara Üniversitesi Tıp Fakültesi
Üroloji AD, ANKARA
cgogus@tr.net