

Purpuric Pityriasis Rosea: A Case Report

PURPURİK PİTRİYAZİS ROZEA: OLGU SUNUMU

Cihangir ALİAĞAOĞLU, MD,^a Mustafa ATASOY,^b MD,
İlhami KİKİ,^c Aysun TOKER, MD,^d Teoman ERDEM, MD,^a

^aDepartment of Dermatology, Numune State Hospital

^bDepartment of Dermatology, Atatürk University, Faculty of Medicine

^cDepartment of Internal Medicine, Atatürk University, Faculty of Medicine

^dDepartment of Biochemistry, Numune State Hospital, ERZURUM

Abstract

Pityriasis rosea (PR) is a common self-limited exanthem of unknown cause. The typical presentation of PR is easily recognized. Since purpuric PR is a very rarely seen variant, its diagnosis is sometimes difficult. In our 16-year-old female patient, maculopapular eruptions were healed spontaneously after one month. Erythrocyte extravasation in the dermis was observed in the histopathologic examination.

Key Words: Purpuric pityriasis rosea

Türkiye Klinikleri J Dermatol 2006, 16:23-25

Özet

Pitriyazis rozea (PR) sebebi bilinmeyen, kendi kendini sınırlayan yaygın bir döküntüdür. PR'nin tipik görünümü kolayca tanınır. Purpurik PR nadir görülen bir tip olmasından dolayı, tanısı bazen güçtür. 16 yaşındaki bayan hastada makülopapüler döküntüler bir ay sonra kendiliğinden iyileşti. Histopatolojik incelemede dermiste damar dışına çıkmış eritrositler gözlemlendi.

Anahtar Kelimeler: Purpurik pitriyazis rozea

Pityriasis rosea is a short-lived rash that commences initially as a large so-called "herald" patch followed by a rapidly evolving eruption on the trunk and extremities. Characteristic pattern of lesions follow the lines of cleavage in a "christmas tree" distribution. PR is most frequently seen between first and third decade but a range of 3 month to 83 years were reported. The incidence doesn't change according to sex.^{1,2} Clinical types of PR are papular PR, vesicular PR, pustular PR, inverse PR, cephalic PR, PR gigantea, PR urticata, and purpuric PR.¹ The typical presentation of PR is easily recognized. The condition was first reported by Gibert

in 1860. Hartman first described a patient with purpuric PR in 1994.^{1,2}

Up to now, there have been only 11 case reports related to purpuric PR in the literature.^{1,2} Therefore, we aimed to present such an interesting and rare variant of PR.

Case Report

A 16-year-old young female presented with a 1-week history of an asymptomatic widespread eruptions observed on the trunk.

In physical examination, multiple purpuric macules and papules over the different sizes were seen especially more commonly in trunk, on upper parts of both arms and on neck. The lesions on trunk were especially on upper parts of trunk and the lesions appearance was like "christmas tree" (Figure 1). There was no sign of a herald patch, and mucosal examination was normal.

White blood cell count, erythrocyte sedimentation rate, prothrombin time, partial throm-

Geliş Tarihi/Received: 22.03.2005

Kabul Tarihi/Accepted: 20.01.2006

Yazışma Adresi/Correspondence: Mustafa ATASOY, MD
Atatürk University Faculty of Medicine,
Department of Dermatology, ERZURUM
mustafaatasoy@hotmail.com
atasoymustafa@gmail.com

Copyright © 2006 by Türkiye Klinikleri

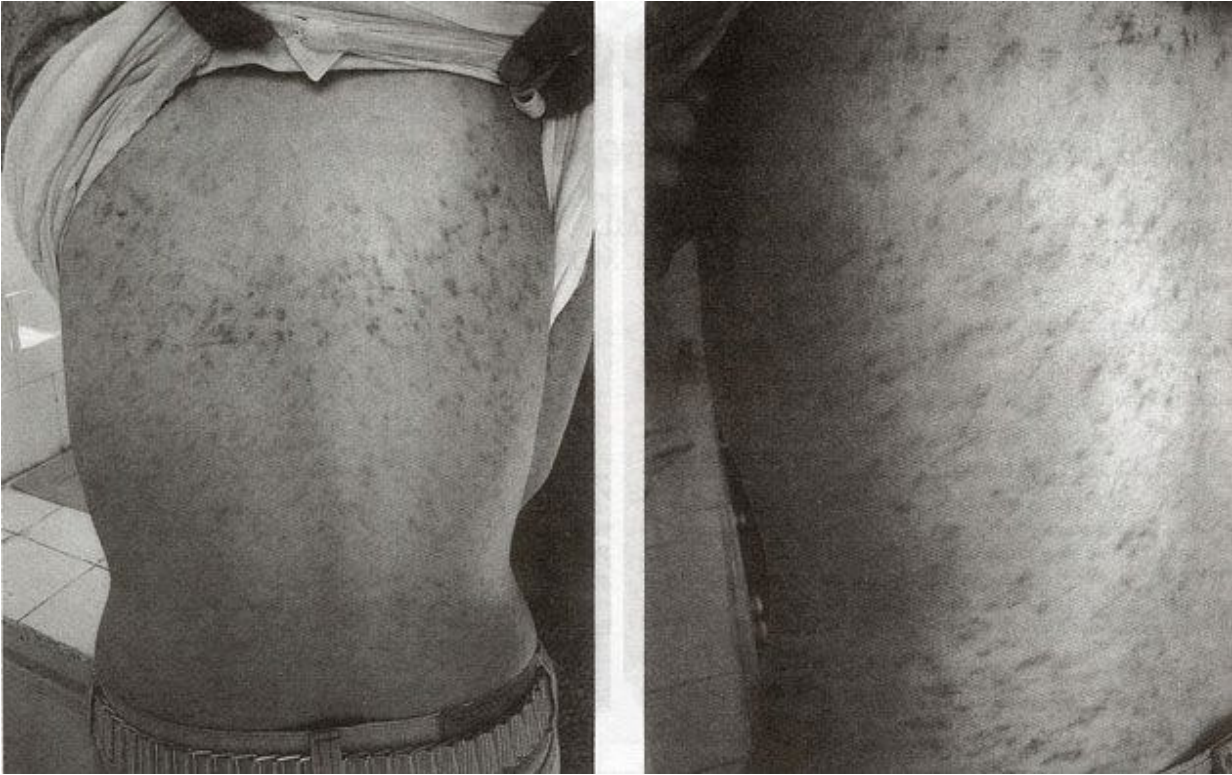

Figure 1. The appearance of “christmas tree” and maculopapular eruptions on the trunk.

boplastin time, biochemical and urinary analyses were all within normal limits. Antinuclear antibody, rapid plasma reagin, rickettsial profile, and streptococcal antibody titers were unremarkable.

A biopsy specimen from a lesion of the trunk showed superficial perivascular lymphohistiocytic infiltrate and erythrocyte extravasation, dermal edema, spongiosis (Figure 2). Direct immunofluorescence testing of the skin was negative.

From these clinical and histopathological findings, the diagnosis of PR was made. The patient was followed-up without treatment. The patient was advised to minimize bathing and sweating. After one month, the eruptions disappeared and no recurrence was observed.

Discussion

Although the etiology is unknown, some infections, drug reactions (captopril, penicillamine, isotretinoin, omeprazole), psychogenic

disturbances and autoimmunity are suggested causes. Increased serum IgM and decreased serum C3 levels in PR patients suggest that the tissue injury is immunologic in origin and may depend on production of antibodies capable of reacting with virus or viral-coded antigens.^{2,3} It has been claimed that a significant number of patients of PR had experienced recent upper respiratory tract infection.⁴ There was not any sign of recent upper respiratory tract infection or prodromal symptoms in our patient. Medication history was absent.

The histopathologic features of purpuric PR are extravasation of erythrocytes into the papillary dermis without evidence of vasculitis. Other features of typical PR such as focal parakeratosis, spongiosis and a superficial lymphocytic perivascular infiltrate may be present.^{1,2}

The differential diagnosis includes hematologic disease, vasculitis and a pigmented purpuric dermatosis.¹

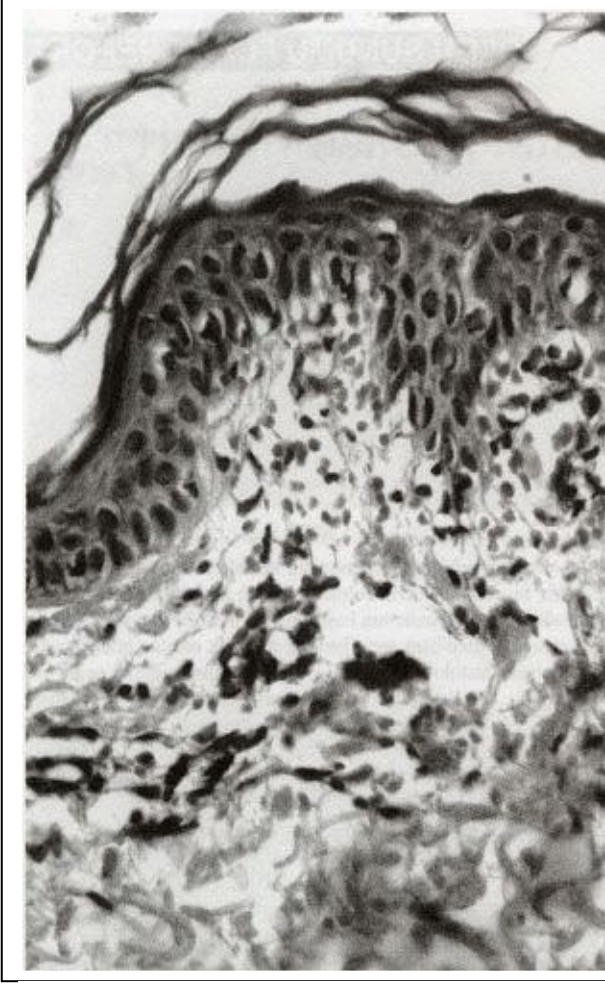


Figure 2. Perivascular lymphocyte infiltration and extravasated erythrocytes in the dermis (HE x40).

In purpuric PR, the lesions are in “christmas tree” appearance and are mostly located on the trunk. In hypersensitivity vasculitis, the lesions are in palpable purpural character and mostly involve extensor surfaces of the lower extremities. In pigmented purpuric dermatosis, the lesions are seen on the extensor surfaces of the lower extremities and are in an irregularly red-brown manner.⁵ Additionally, this condition is easily differentiated from hypersensitivity vasculitis due to the absence of perivascular neutrophil infiltration, nuclear dust and fibrin accumulation in histopathologic examination.^{1,2}

REFERENCES

1. Pierson JC, Dijkstra JW, Elston DM. Purpuric pityriasis rosea. *J Am Acad Dermatol* 1993;28:1021.
2. Sezer E, Saracoglu ZN, Urer SM, Bildirici K, Sabuncu I. Purpuric pityriasis rosea. *Int J Dermatol* 2003;42:138-40.
3. Abdel-Hafez K, Deyab Z. Pityriasis rosea. An immunologic study. *Int J Dermatol* 1987;26:231-3.
4. Chuang Ty, Perry HO, Ilstrup DM, Kurland LT. Recent upper respiratory tract infection and pityriasis rosea: A case-control study of 249 matched pairs. *Br J Dermatol* 1983;108:587-91.
5. Braun-Falco O, Plewing G, Wolff HH, Burgdorf WHC: *Dermatology*, 2nd ed, Berlin; Springer-Verlag: 2000. p.584-5, 904-8, 974-5.