




## Ligneous Gingivitis Due to Type I Plasminogen Deficiency in a Hydrocephalic Patient

 Müge ÇİMEN<sup>a</sup>,  
 Sezin ÖZER<sup>b</sup>,  
 Berk ÖZYILMAZ<sup>c</sup>

<sup>a</sup>Department of Pediatric Dentistry, İstanbul Okan University Faculty of Dentistry, İstanbul, TURKEY

<sup>b</sup>Private Dentist, Samsun, TURKEY

<sup>c</sup>Department of Medical Genetics, İzmir Tepecik Training and Research Hospital, İzmir, TURKEY

Received: 07 Dec 2018

Received in revised form: 24 Jan 2019

Accepted: 29 Jan 2019

Available online: 31 Jan 2019

Correspondence:

Müge ÇİMEN,  
İstanbul Okan University  
Faculty of Dentistry,  
Department of Pediatric Dentistry,  
İstanbul, TURKEY  
cimenmg@gmail.com

This study was presented as a poster at the 24<sup>th</sup> Turkish Pediatric Dentistry Association Congress, 19-22 October 2017, Antalya, Turkey.

**ABSTRACT** Ligneous gingivitis is a rare progressive destructive membranous periodontal disease that is caused by plasminogen deficiency and characterized by nodular gingival enlargement. Early diagnosis and treatment of gingival lesions due to plasminogen deficiency may play an important role in preventing infections and retarding the onset of a destructive periodontitis. The most challenging issue for clinicians in ligneous gingivitis and conjunctivitis is to increase the effectiveness of treatment. For this reason, pediatric dentists play a key role in the early diagnosis and treatment of the disease. The aim of this case report is to present the symptoms and treatment of a child with ligneous gingivitis.

**Keywords:** Congenital hydrocephaly; ligneous gingivitis; type I plasminogen deficiency; nodular gingival enlargement; periodontal disease

Ligneous mucosal diseases include lesions that are stemless, hard-looking and pseudomembrane formations are seen in more than one mucosal tissue. However, gingival and conjunctival involvements are often seen during childhood and thus help early diagnosis. Skin, female genital mucosa and tracheobronchial arc involvement are also reported in literature.<sup>1</sup> It is known that the resulting “wood-like” lesions are fibrin deposition due to plasminogen (PLG) deficiency.<sup>2</sup>

The PLG synthesized in the liver plays an important role from fibrinolysis to wound healing, cell migration and angiogenesis.<sup>3</sup> It is in the form of pro-enzymes in the bloodstream and can be converted to plasmin by both tissue PLG activator (tPA) as well as by urokinase plasminogen activator (uPA). During the healing of the wound surface, tPA activates the fibrinolytic effect of plasmin. This fibrinolytic effect contributes to the homeostasis by providing the breakdown of fibrin deposits.<sup>4</sup>

Plasminogen deficiency may be congenital or acquired. Congenital PLG deficiency is divided into type I hypoplasminogenemia and type II dysplasminogenemia.<sup>2</sup> Hypoplasminogenemia is a genetic disorder characterized by an autosomal recessive inheritance. Plasminogen level and activity in hypoplasminogenemia is very low or undetectable.<sup>5</sup> Therefore, fibrin accumulation at inflammation site and delayed wound healing are observed in the patients.<sup>3</sup>

Ligneous gingival inflammation is a progressive destructive, membranous periodontal disease characterized by nodular gingival enlargement, rarely due to plasminogen deficiency.<sup>6</sup> Although ligneous gingivitis was described by Frimodt-Moller in 1973, identification of ligneous conjunctivitis is earlier.<sup>7</sup> Ligneous conjunctivitis was first described by Bouisson in 1847.<sup>8</sup> In this case report, it is aimed to present oral findings and the treatment of a hydrocephalic child with ligneous gingivitis.

## CASE REPORT

A 33-month-old female patient diagnosed with hydrocephalus that had extensive gingival enlargement and complaint of pain in the upper and lower jaws applied to our clinic by her parents (Figure 1).

In her medical history, she was learned to receive conjunctivitis treatment. Due to her ocular and gum findings, she was consulted with the pediatrician for suspicion of plasminogen deficiency. Hematologic analysis at Pediatric Hematology Department of Ondokuz Mayıs University Faculty of Medicine revealed plasminogen deficiency.

Intraoral examination of the patient showed widespread gingival enlargement and infected areas due to plaque accumulation, especially in the anterior regions. Gingival hyperplasia areas, covered with spontaneous and stimulant, hyperemic, nodular, and pseudomembrane were painful (Figure 2).

Although the patient's mouth and cheek mucosa were healthy, ulcerative lesions were observed




FIGURE 1: 33-month-old female patient with hydrocephalus.

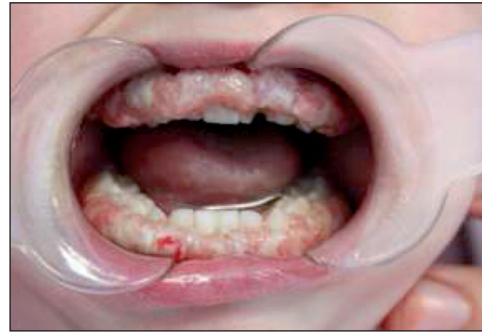

FIGURE 2: Nodular membranous gingival enlargement.

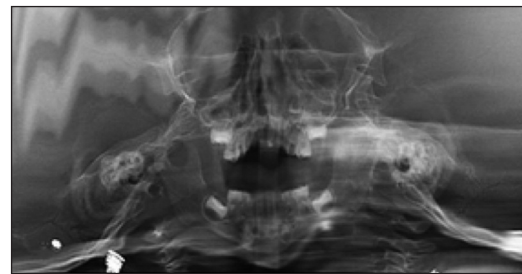

FIGURE 3: Panoramic radiograph.

in the tongue and lip corners. According to radiographic examination findings, there was no permanent dental germ defect in the patient (Figure 3). Hematological analysis of the patient revealed an increase in the number of white blood cells and lymphocytes.

The patient was learned to have been shunted due to hydrocephalus during the neonatal period and the shunt catheter was renewed due to blockage. It is reported in the literature that type I plasminogen deficiency may be a rare cause of congenital occlusive hydrocephalus.<sup>9</sup> Genetic analysis of the patient was made due to the consanguineous marriage that caused the autosomal recessive genetic transition of plasminogen deficiency. Molecular genetic evaluation of the patient started with chromosomal microarray analysis (CMA). For the analysis of copy number changes, CytoScan Optima Array Kit from Affymetrix was used. The microarray chip used was offering whole-genome coverage for the detection of chromosomal abnormalities with 315,608 markers. CMA results of the patient showed no clinically significant copy number changes.

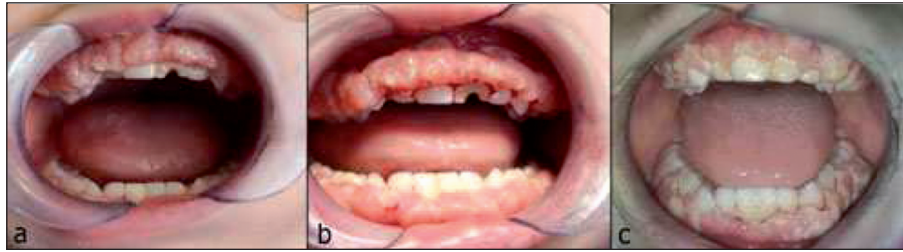

FIGURE 4: At 1st month (a), 3<sup>rd</sup> month (b) and 6<sup>th</sup> month (c) follow up.

For the further molecular genetic evaluation, especially for the clinical diagnosis of plasminogen deficiency and associated syndromes; TruSight Inherited Disease NGS Panel from Illumina was used. This targeted sequencing panel was covering 552 genes associated with severe, autosomal recessive pediatric onset diseases including the one that was associated with clinical diagnosis of the patient, Plasminogen Deficiency (PLG). However, NGS analysis of the gene panel did not reveal a pathogenic mutation.

Ligneous gingivitis/periodontitis and/or ligneous conjunctivitis were not observed in the intraoral examinations of the parents. The other two siblings of the patient did not have evidence of the disease. The parents were informed about nutrition and oral care procedures, and after scheduling an appointment they were referred to Pediatric Hematology Department of Ondokuz Mayıs University Faculty of Medicine for systemic plasma treatment. Throughout the follow-up period of 6 months, pain complaints decreased, gum growths retreated, but not completely disappeared. The left deciduous central tooth was restored with the modified glass ionomer resin at sixth month (Figure 4a, 4b, 4c). Oral informed consent was obtained from the parents for publication of this case report and images.

## DISCUSSION

Severe type 1 plasminogen deficiency is an autosomal recessive multi-system inherited disease. Ligneous gingivitis (30%) and ligneous conjunctivitis (81%) are most common in affected patients. In addition, severe plasminogen deficiency is seen in at least 12% of the patients with congenital occlusive hydrocephalus.<sup>9</sup>

Almost three-quarters of the case reports related to ligneous gingivitis are in the Turkish population.<sup>6,10</sup> Consanguinity rates are very high in our country and this may be responsible for this relatively higher incidence of ligneous gingivitis in this population. Parents of our patient are cousins, consistently with literature.<sup>6,10</sup> Although no pathogenic causes have been found in the patient's molecular genetic evaluation, ongoing studies with different methods such as exome sequencing may reveal genetic results that may explain the clinical situation.

Our patient had the well-known findings associated with severe type I plasminogen deficiency including ligneous conjunctivitis, ligneous gingivitis and hydrocephalus. Because topical plasminogen and intravenous plasminogen concentrate replacement are useful in the treatment of ligneous conjunctivitis, systemic plasminogen therapy was applied in this patient with ligneous gingivitis. Systemic plasminogen therapy was reported to yield successful results in another child who had homozygous type I plasminogen.<sup>11</sup>

Early diagnosis and treatment of gingival lesions due to plasminogen deficiency may play a role in prevention of infections and at the onset of a destructive periodontitis. The most challenging issue for clinicians in ligneous gingivitis and conjunctivitis is increasing the effectiveness of treatment. Therefore, pediatric dentists may play a key role in the early diagnosis and treatment of the disease.

### Source of Finance

*During this study, no financial or spiritual support was received neither from any pharmaceutical company that has a direct connection with the research subject, nor from a company*

that provides or produces medical instruments and materials which may negatively affect the evaluation process of this study.

### Conflict of Interest

No conflicts of interest between the authors and / or family members of the scientific and medical committee members or members of the potential conflicts of interest, counseling, expertise, working conditions, share holding and similar situations in any firm.

### Authorship Contributions

**Idea/Concept:** Müge Çimen, Sezin Özer; **Design:** Müge Çimen; **Control/Supervision:** Müge Çimen, Sezin Özer; **Data Collection and/or Processing:** Müge Çimen; **Analysis and/or Interpretation:** Müge Çimen, Sezin Özer, Berk Özyılmaz; **Literature Review:** Müge Çimen, Sezin Özer, Berk Özyılmaz; **Writing the Article:** Müge Çimen, Sezin Özer, Berk Özyılmaz; **Critical Review:** Müge Çimen, Sezin Özer; **References and Fundings:** Müge Çimen, Sezin Özer, Berk Özyılmaz; **Materials:** Müge Çimen, Sezin Özer, Berk Özyılmaz.

## REFERENCES

- Günhan Ö, Avcı A, Dereci Ö, Akgün S, Celasun B. Extensive fibrin accumulation and accompanying epithelial changes in the pathogenesis of ligneous mucosal disease (ligneous periodontitis). *Am J Dermatopathol.* 2012;34(1):35-40. [[Crossref](#)] [[PubMed](#)]
- Schuster V, Seregard S. Ligneous conjunctivitis. *Surv Ophthalmol.* 2003;48(4):369-88. [[Crossref](#)]
- Tefs K, Gueorgieva M, Klammt J, Allen CM, Aktas D, Anlar FY, et al. Molecular and clinical spectrum of type I plasminogen deficiency: a series of 50 patients. *Blood.* 2006;108(9):3021-6. [[Crossref](#)] [[PubMed](#)]
- Law RH, Abu-Ssaydeh D, Whisstock JC. New insights into the structure and function of the plasminogen/plasmin system. *Curr Opin Struct Biol.* 2013;23(6):836-41. [[Crossref](#)]
- Tefs K, Georgieva M, Seregard S, Tait CR, Luchtman-Jones L, Ziegler M, et al. Characterization of plasminogen variants in healthy subjects and plasminogen mutants in patients with inherited plasminogen deficiency by isoelectric focusing gel electrophoresis. *Thromb Haemost.* 2004;92(2):352-7. [[Crossref](#)] [[PubMed](#)]
- Günhan O, Günhan M, Berker E, Gürkan CA, Yildirim H. Destructive membranous periodontal disease (ligneous periodontitis). *J Periodontol.* 1999;70(8):919-25. [[Crossref](#)] [[PubMed](#)]
- Frimodt-Moller J. Conjunctivitis ligneosa combined with a dental affection. Report of a case. *Acta Ophthalmol (Copenh).* 1973;51(1):34-8. [[Crossref](#)] [[PubMed](#)]
- Bouisson M. Ophthalmie sur-aigue avec formation de pseudomembranes à la surface de la conjonctive. *Ann Ocul.* 1847;17:100-4.
- Annagür A, Altunhan H, Özbek O, Öztürk BT, Örs R. Congenital hydrocephalus as a rare cause of severe type 1 plasminogen deficiency. *Türk Arch Ped.* 2013;47:248-50. [[Crossref](#)]
- Sivolella S, De Biagi M, Sartori MT, Berengo M, Bressan E. Destructive membranous periodontal disease (ligneous gingivitis): a literature review. *J Periodontol.* 2012;83(4):465-76. [[Crossref](#)] [[PubMed](#)]
- Çiftçi E, Ince E, Akar N, Dogru Ü, Tefs K, Schuster V. Ligneous conjunctivitis, hydrocephalus, hydrocele, and pulmonary involvement in a child with homozygous type I plasminogen deficiency. *Eur J Pediatr.* 2003;162(7-8):462-5. [[Crossref](#)] [[PubMed](#)]