

# Acute Myocarditis in Postpartum Period Presenting with Eosinophilia: Case Report

## Postpartum Dönemde Eozinofilinin Eşlik Ettiği Akut Miyokardit

Ercan VAROL, MD,<sup>a</sup>  
 Mehmet ÖZAYDIN, MD,<sup>a</sup>  
 Zehra KÜÇÜKTEPE, MD,<sup>a</sup>  
 Doğan ERDOĞAN, MD,<sup>a</sup>  
 Abdullah DOĞAN, MD<sup>a</sup>

<sup>a</sup>Department of Cardiology,  
 Süleyman Demirel University  
 Faculty of Medicine, Isparta

Geliş Tarihi/Received: 25.11.2008  
 Kabul Tarihi/Accepted: 23.02.2009

Yazışma Adresi/Correspondence:  
 Ercan VAROL, MD  
 Süleyman Demirel University  
 Faculty of Medicine,  
 Department of Cardiology, Isparta,  
 TÜRKİYE/TURKEY  
 drercanvarol@yahoo.com

**ABSTRACT** We report a rare case of 20-year-old woman with acute myocarditis in postpartum period presenting with eosinophilia with pericardial, pleural effusion and apical thrombus. She had underwent cesarean section 2 months ago. She was admitted to our clinic because of dyspnea, fatigue and swelling of legs for 1 month. Laboratory testing revealed eosinophil ratio 28%, eosinophil  $1.8 \times 10^9/L$ . Echocardiography showed reduced left ventricular systolic function, a fresh thrombus within left ventricular apex, spontan echo contrast within left ventricle and severe pericardial effusion with right atrial and ventricular collapse. Pericardiocentesis was performed. Pericardial and pleural fluid samples showed hypereosinophilia. With the onset of standart heart failure treatment and corticosteroid treatment, the patient's clinical status, symptoms and laboratory findings improved dramatically. The left ventricular function and laboratory findings returned to normal completely at 6 months.

**Key Words:** Eosinophilia, myocarditis

**ÖZET** Biz bu yazıda, 20 yaşındaki kadın postpartum dönemde gelişen, eozinofilinin eşlik ettiği, perikardiyal, plevral efüzyon ve apikal trombus ile birlikte olan nadir bir akut miyokardit olgusunu sunduk. Olgu iki ay önce sezeryan operasyonu geçirmişti. Olgu bize son bir ay içinde gelişen nefes darlığı, yorgunluk ve ayaklarda şişme ile başvurdu. Kan sayımında eozinofil oranı %28 eozinofil  $1.8 \times 10^9/L$  bulundu. Ekokardiyografide azalmış sol ventrikül sistolik fonksiyonları, sol ventrikül apeksinde taze trombus, sol ventrikül içinde spontan eko kontrast, ciddi perikardiyal efüzyon ile birlikte sağ atriyal ve ventriküle bası mevcuttu. Olguya perikardiyosentez yapıldı. Perikardiyal ve plevral sıvı örneklerinde hipereozinofili tespit edildi. Kalp yetersizliği ve kortikosteroid tedavisinin uygulanmasıyla birlikte hastanın klinik durumunda, semptom ve laboratuvar bulgularında belirgin iyileşme sağlandı. Sol ventrikül fonksiyonları ve laboratuvar bulguları 6 ay içinde tamamen normale döndü.

**Anahtar Kelimeler:** Eozinofili, miyokardit

Türkiye Klinikleri J Cardiovasc Sci 2009;21(3):460-3

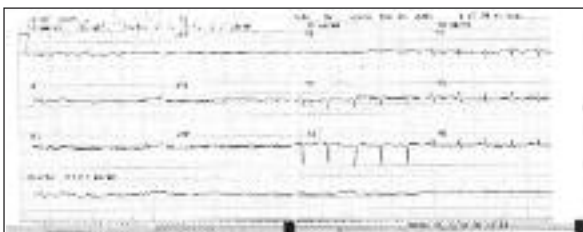**H**ypereosinophilic syndrome (HES) includes a heterogeneous group of disorders characterized by an absolute eosinophil count  $1.5 \times 10^9/L$  lasting for more than 6 months in the absence of any known cause of hypereosinophilia and with evidence of organ involvement. Cardiac disease occurs in more than 50% of HES patients and is the major cause of morbidity and mortality in these patients.<sup>1-3</sup> Here we report the case of a 20-year-old woman who presented with hypereosinophilia and severe, however reversible, impairment of the left ventricular function in postpartum period.

## CASE REPORT

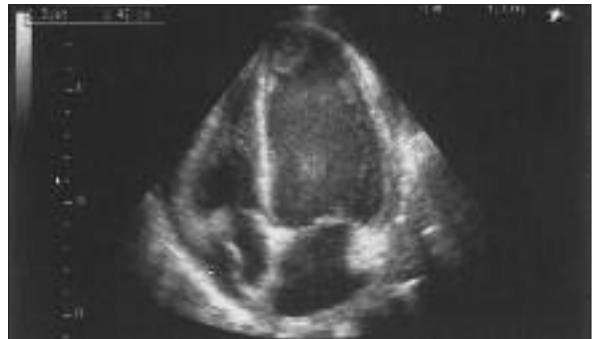A 20-year-old woman was admitted to our clinic because of dyspnea, fatigue and swelling of legs for 1 month of period. She had undergone cesarean section 2 months ago. She had a history of bronchial asthma for 5 years. She had been admitted two times in last month due to nausea, vomiting, cough and dyspnea and had been treated with antiasthmatic drugs including inhaled steroid with a diagnosis of asthma and treated with antibiotic with a diagnosis of urinary tract infection.

The blood pressure was 90/60 mmHg. The heart rate was 98 bpm and regular. There were no rales or rhonchi. An S3 was audible on cardiac examination. Electrocardiography showed sinus rhythm, low voltage and poor r wave progression (Figure 1). Chest radiograph showed pleural effusion on the left side. Echocardiography showed reduced left ventricular function (ejection fraction 20% with Simpson method), a fresh thrombus within left ventricular apex, spontaneous echo contrast within left ventricle and severe pericardial effusion with right atrial and ventricular collapse (Figure 2, 3, 4). Laboratory testing revealed the following values: glucose-89 mg/dL, creatinine-0.8 mg/dL, AST-19U/l, ALT-19U/l, hemoglobin-11.7 mg/dL, thrombocyte-542000/mm<sup>3</sup>, eosinophil ratio 28%, eosinophil  $1.8 \times 10^9/L$ , CRP-36.1, Ig E>1120 IU/mL and ESR-40 mm/h.

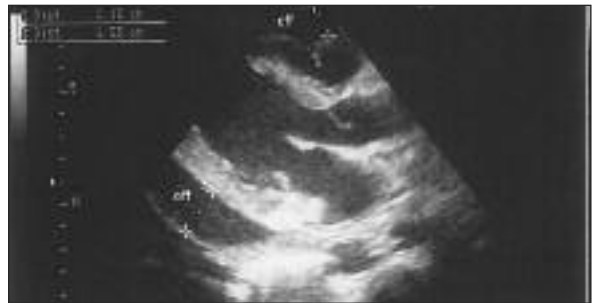The patient was hospitalized for investigation and treatment. She underwent pericardiocentesis due to tamponade findings and 300 cc of bloody fluid was removed. The fluid was exudative and analysis showed 600 WBC/mm<sup>3</sup> and density-



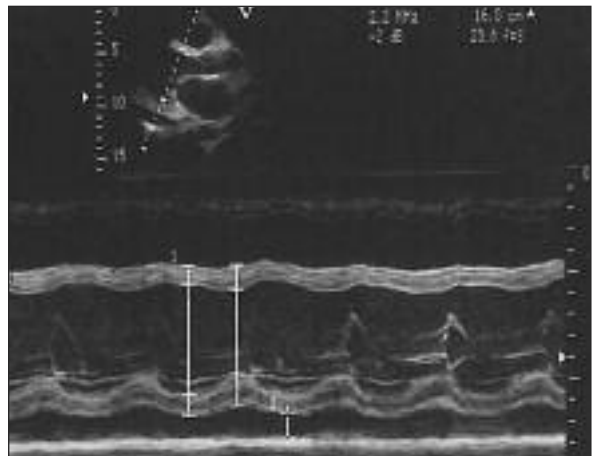
**FIGURE 1:** The admission 12-leads electrocardiogram reveals sinus rhythm, low voltage and poor r wave progression.



**FIGURE 2:** The echocardiogram showing the apical thrombus, spontan echo-contrast and right atrial compression.



**FIGURE 3:** The echocardiogram showing the right ventricular compression.



**FIGURE 4:** The echocardiogram showing the severely reduced left ventricular function with normal cardiac chambers.

1015. Bacterial cultures of the fluid were sterile and cytologic examination of fluid revealed an eosinophilic infiltrate without malignant cells. Abdominal ultrasonography revealed ascites and bilateral pleural effusion. We thought eosinophilic myocarditis as a diagnosis firstly. However, we did not perform

endomyocardial biopsy, so we could not say that the exact diagnosis is eosinophilic myocarditis. The consultation was made by department of hematology due to eosinophilia. Silazapril 1 mg, furosemide 80 mg, enoxaparin 0.6 SC 2 × 1, warfarin 5 mg and prednisolone 48 mg/day was began. Within 3 days after the onset of medication the patient's clinical status and symptoms improved dramatically. Due to intractable cough silazapril was stopped and candesartan was started. There was also a mild degree of fever. The consultation was made by department of Chest Diseases. Salbutamol, asetilcystein, budesonid and sulbactam-ampicillin were added to treatment with diagnosis of pneumonia. A repeat chest X-ray showed pleural effusion. Thoracocentesis performed yielded a transudative pleural fluid. Bacterial cultures of the fluid was sterile and cytologic examination of fluid revealed small number of eosinophilic infiltrate without malignant cells. The stool examination was negative for parasitic infections. The autoantibody studies did not indicate the presence of any systemic connective tissue disease either. The blood, sputum and throat cultures were negative. Bone marrow needle aspiration biopsy was taken after stabilization of the patient and massive eosinophilic hyperplasia of bone marrow was found. Acute leukemia was excluded.

The repeated echocardiograms 10 days later showed no change in ejection fraction but regression of pericardial effusion and thrombus. The patient was discharged 15 days later without any clinical sign of congestive heart failure. The echocardiogram at six months showed normal left ventricular systolic function and normal laboratory findings. She remains well with normal laboratory findings at five-years follow up.

## DISCUSSION

HES constitute a rare and heterogeneous group of disorders, defined as persistent and marked blood eosinophilia ( $> 1.5 \times 10^9/L$  for more than six consecutive months) associated with evidence of eosinophil-induced organ damage, where other causes of hypereosinophilia such as allergic, parasitic, and malignant disorders have been excluded.<sup>1</sup> HES oc-

cur most frequently in young to middle-aged patients, but may concern any age group. Men account for about 85% of patients and the syndrome primarily occurs in middle age. Target-organ damage mediated by eosinophils is highly variable among patients with involvement of skin, heart, lung, and central and peripheral nervous system in more than 50% of cases.<sup>1</sup> Cardiac disease is the major cause of morbidity and mortality in HES, occurring in 48% to 75% of HES cases.<sup>2,3</sup> Eosinophilic endomyocardial disease can be classified into three groups:

1) Acute necrotizing stage: pathologically it is characterized by an active infiltration of the myocardium by eosinophils, lymphocytes and histiocytes

2) Thrombotic phase:

3) Late fibrotic phase.<sup>4</sup> Cardiac damage follows extracellular protein deposit and activation of eosinophils by IL-5.<sup>5</sup> Eosinophilic myocarditis is a rare condition.<sup>6,7</sup> Eosinophilic myocarditis in peripartum stage is a very rare condition and there are only two reports.<sup>8,9</sup>

We presented a case of acute myocarditis in postpartum period presenting with eosinophilia with severe impaired left ventricular function, which was reversible with heart failure and prednisolone treatment. We thought eosinophilic myocarditis as a first diagnosis. However, in our case, we lacked previous blood counts of the patient. We also did not perform endomyocardial biopsy. Thus, the settled diagnosis of eosinophilic myocarditis was of suspicion. However, all blood count, pericardial and pleural fluid samples showed hypereosinophilia. The signs and symptoms of the patient improved dramatically with corticosteroid treatment. Other parasitic, immunologic and neoplastic causes of eosinophilia were excluded in our patient. We suspected that eosinophilia in the blood, associated with severe illness and a prompt clinical improvement, coinciding with normalization of the blood count in response to steroids, were indicative of the presence of a pathogenic relation between the eosinophilia and myocardial damage.

There are only two reports eosinophilic myocarditis in postpartum period. In previous reports, chronic irreversible impairment of left ventricular

function had been occurred. However, in our case, left ventricular systolic function returned to normal levels with only continuation of diastolic dysfunction. Only Gehrke D et al reported associated pericardial effusion in the postpartum eosinophilic myocarditis. In our case, there were pericardial effusion, pleural effusions with eosinophilic infiltrates and apical thrombus. Due to right ventricular

compression, pericardiocentesis was performed. She remains well with normal laboratory findings at five-years follow up.

In conclusion, eosinophilia can be a rare cause of myocarditis. Every effort for establishing the diagnosis should be performed since even severe cardiac dysfunction may be reversible upon appropriate therapy including corticosteroids.

## REFERENCES

1. Roufosse FE, Goldman M, Cogan E. Hypereosinophilic syndromes. *Orphanet J Rare Dis* 2007;2:37.
2. Ommen SR, Seward JB, Tajik AJ. Clinical and echocardiographic features of hypereosinophilic syndromes. *Am J Cardiol* 2000; 86(1):110-3.
3. Okinaka T, Isaka N, Nakano T. Coexistence of giant aneurysm of sinus of Valsalva and coronary artery aneurysm associated with idiopathic hypereosinophilic syndrome. *Heart* 2000;84(3):E7.
4. Olsen EG, Spry CJ. Relation between eosinophilia and endomyocardial disease. *Prog Cardiovasc Dis* 1985;27(4):241-54.
5. Desreumaux P, Janin A, Dubucquoi S, Copin MC, Torpier G, Capron A, Capron M, et al. Synthesis of interleukin-5 by activated eosinophils in patients with eosinophilic heart diseases. *Blood* 1993;82(5):1553-60.
6. Corradi D, Vaglio A, Maestri R, Legname V, Leonardi G, Bartoloni G, et al. Eosinophilic myocarditis in a patient with idiopathic hypereosinophilic syndrome: insights into mechanisms of myocardial cell death. *Hum Pathol* 2004;35(9):1160-3.
7. Huntgeburth M, Lindner M, Fries JW, Hoppe UC. Hypereosinophilic syndrome associated with acute necrotizing myocarditis and cardiomyopathy. *Z Kardiol* 2005;94(11): 761-6.
8. Pearce CB, McMeekin JD, Moyana TN, Sibley J. A case of peripartum eosinophilic myocarditis. *Can J Cardiol* 1999;15(4):465-8.
9. Gehrke D, Herzum M, Schönian U, Klein HH, Drude L, Mennel HD, et al. [Eosinophilic endomyocarditis post partum or pregnancy-related cardiomyopathy] *Herz* 1994;19(3): 176-81.