

The Fate of High-Density Porous Polyethylene Medpor Implants Inserted into Mandibular Bone Defects of Dogs

KÖPEKLERDEKİ MANDİBULA DEFEKTLERİNDE YERLEŞTİRİLEN PORÖZ YÜKSEK DANSİTELİ POLİETİLEN İMPLANTLARIN AKİBETİ

Kutlu SEVİN*, İbrahim AŞKAR**, Bizden TAVİL SABUNCUOĞLU***, Aydın SARAY****, Erdem YORMUK*

- * Dept. of Plastic and Reconstructive Surgery, Medical School of Ankara University, Ankara
** Dept. of Plastic and Reconstructive Surgery, Medical School of Dicle University, Diyarbakır
*** Dept of Histology and Embryology, Medical School of Ankara University, Ankara
**** Dept of Plastic and Reconstructive Surgery, Sevgi Hospital, Ankara, TURKEY

Summary

Various alloplasts have been investigated and new alternatives are found for reconstruction of tissue defects. Porous high-density polyethylene implant is well tolerated by surrounding tissue. Its porous structure is rapidly infiltrated by host tissue. In this study, we planned to investigate the fate of porous high-density polyethylene implant inserted into a bone defect in dogs. In ten dogs, bilateral bone defects of 1x1 cm. were formed on the corpus mandibula by oscillating saw and 1x1x0.5 cm implants were inserted into the defect on one side. In the eighth week, bone tissue was noted in the pores and also, blood vessels were found to enter the implant. We concluded that, porous high-density polyethylene implant is easy to manipulate and its relative immediate surgical stabilization makes it a useful material to be used in maxillofacial procedures.

Key Words: Porous high-density polyethylene implant, Bone healing, Tissue defects

T Klin J Med Res 1999, 17:125-127

Some tissue defects are difficult to repair and often require complex solutions. Although autogenous tissues are mostly preferred, various alloplasts have been investigated and new alternatives are found. Porous high-density polyethylene (PHDPE) is well tolerated by surrounding tissue, and its porous structure is rapidly infiltrated by host tissue. Some authors have shown fibrovascular and bony ingrowth into porous polyethylene implants (1,2).

Received: Feb. 27, 1998

Correspondence: Dr. Kutlu SEVİN
Ikizdere Sokak No: 7/9
Ankara, TURKEY

T Klin J Med Res 1999, 17

Özet

Doku defektlerinin onarımı için çeşitli maddeler araştırılmış ve yeni alternatifler bulunmuştur. Bunlardan biri olan poröz yüksek dansiteli polietilen implant, çevre dokular tarafından iyi tolere edilmekte ve süngerimsi yapısı, çevre dokuların içine hızla girmesine olanak sağlamaktadır. Bu deneysel çalışmada, köpeklerde, alt çene kemiğinde oluşturulan defektlere yerleştirilen polietilen implantların akıbeti araştırıldı. On adet köpekte, alt çene kemiğinde 1x1 cm. kemik çıkarılarak tek tarafa, 1x1x0.5 cm boyutlarında implant yerleştirildi. Sekizinci haftada lamelli kemik dokusunun implantın içine girdiği tespit edildi. Poröz yüksek dansiteli polietilen implantın, yerleştirildiği doku içinde hızla stabilize olması ve kullanım kolaylıkları nedeniyle maksillofasial cerrahide uygulanması yararlı bir sistem olduğu sonucuna varıldı.

Anahtar Kelimeler: Poröz yüksek dansiteli polietilen implant, Kemik iyileşmesi, Doku defekti

T Klin Araştırma 1999, 17:125-127

Dougherty and Wellisz developed an animal model to recreate the condition of an open fracture in communication with the maxillary sinus (3). They noted that PHDPE implants showed both vascular and soft-tissue ingrowth into its pores in rabbits. In the review of the literature, no paper was found dealing with the effects of PHDPE in bone defects of dogs. We planned to investigate the fate of PHDPE implant inserted into a bone defect in dogs.

Materials and Methods

Ten dogs were used for the study. Bilateral bone defects of 1x1 cm. were formed on the corpus mandibula of dogs by oscillating saw. PHDPE im-

plants (Porx Surgical Inc. GA, USA) of 1x1x0.5 cm were inserted into the defect on one side (Fig.1). The implant has average pore size of greater than 100 micro-meters and pore volume in the 50% range, with a density of 0.6 g/cm³. Nothing was inserted into the defect on the other side, which would be the control group. Biopsies were taken from each bone defect site on 4th and 8th weeks postoperatively. Each biopsy group consisted of five dogs.

Results

In the control group, connective tissue, and bone formation was noted on the fourth week (Figure 2). Cartilage tissue was not found. At the eighth week, connective and more bone tissue was formed (Figure

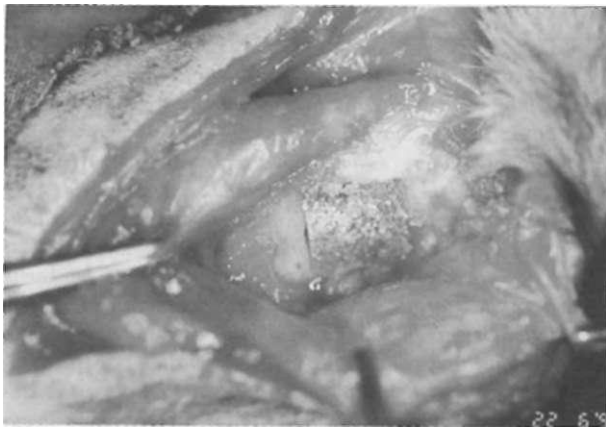


Figure 1. Porous high-density polyethylene implants of 1x1x0.5 cm were inserted into the defect on one side.

3). In the PHDPE group, connective tissue infiltration was noted through the PHDPE implant in the fourth week (Figure 4). Also, vascular formation was found to enter the implant. In the eighth week, bone tissue was noted in the pores of the implant (Figure 5). The implant retained its predetermined form macroscopically and histologically. The edges of the blocks were not rounded and no sign of resorption was observed. During the biopsies, the cut surface of the implant was noted to bleed from the pores.

Discussion

Dougherty and Wellisz developed an animal model to create an open fracture in the maxillary sinus. They studied the wound healing of sinus wall

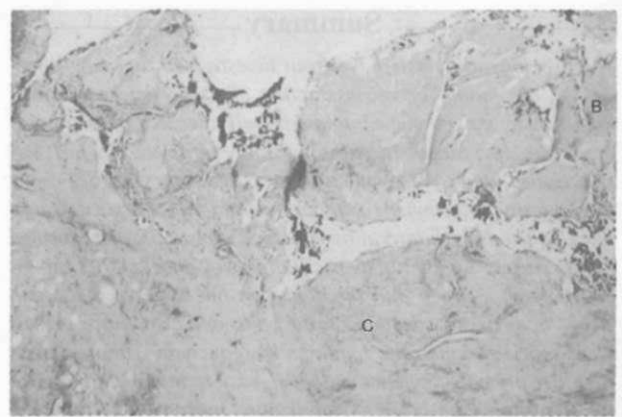


Figure 2. In the control group, connective tissue, bone formation was noted on the fourth week (H-E, X10). (B: Bone tissue, C: connective tissue)



Figure 3. At the eighth week, connective and more bone tissue was formed in the control group (H-E, X10). (B: Bone tissue, C: connective tissue)

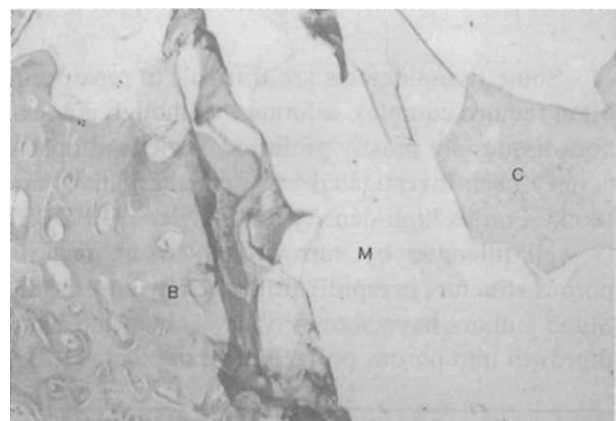


Figure 4. In the experimental group, connective tissue infiltration was noted through the implant in the fourth week (H-E, X10). (B: Bone tissue, C: connective tissue, M: PTFE implant)

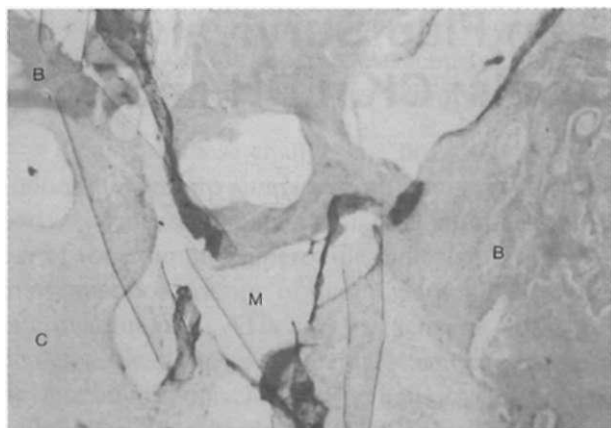


Figure 5. In the eighth week, bone tissue was noted to proliferate through the pores of the implant (H-E, X10). (B: Bone tissue, C: connective tissue, M: PTFE implant)

structures following fracture in the presence of PHDPE. Eight-mm defects were formed bilaterally in maxillary sinuses including bone and mucosa in rabbits. The implants were placed in the soft-tissue pockets to obturate the defects. PHDPE implants showed both vascular and soft-tissue ingrowth into its pores by week one. Bone ingrowth was seen by the third week. The PHDPE implants demonstrated bone and soft-tissue fixation, and mature overlying mucosa was reconstituted over the defects (3).

PHDPE is a biocompatible large-pore, high-density polyethylene implant which has proven both experimentally and clinically to fulfil the criterion for maxillofacial reconstructive and aesthetic surgical grafting (4). This implant has a smooth exterior surface and a series of conical ridges on its undersurface that enable easy bending, good contour adaptability, and suitable strength (5). Porous polyethylene sheets offer several distinct advantages when used for orbital reconstruction. They are easy to handle, to shape, to contour, to place and to fixate. They can be used with other autogenous and alloplastic implants. PHDPE has been used successfully as an implant in orbital fracture repair and in the management of both cosmetic and post-traumatic facial deformities. The material is well tolerated, resists infection, is nonantigenic, and promotes tissue ingrowth. Additionally, sutures can be passed through it. These characteristics led to its use as an implant in anophthalmic socket surgery (6). Couldwell described the use of PHDPE implant for cosmetic cranioplasty. The implant may be used

to cover any small- or medium-sized (< 8 cm) cranial defect, offering similar cosmetic results to standard alloplast cranioplasty while decreasing operation time (7). Porous polyethylene implant is a relatively new implant material that is well suited for this purpose and has a number of advantages over other alloplasts. It is a pure polyethylene with a unique manufacturing process and pore size. Technically, it is easy to work with; it can be carved, contoured, adapted, and fixated to obtain a precise three-dimensional framework. Physically, it is a pure, biocompatible, strong substance that does not resorb or degenerate. It demonstrates long-term stability, high tensile strength, resistance to stress and fatigue, and a virtual lack of surrounding soft-tissue reaction. Rapid tissue ingrowth occurs into the pores. Extensive vascular ingrowth creates the potential to transport cellular products that fight infection deep into the implant (8). The implant was noted to retain its predetermined form macroscopically and histologically. The edges of the blocks were not rounded or deformed and no sign of resorption was observed.

In conclusion, PHDPE implant is easy to manipulate and its relative immediate surgical stabilization makes it a useful system to be used in maxillofacial procedures.

REFERENCES

- Berghaus A, Mulch G, Handrock M. Porous polyethylene and proplast: Their behaviour in a bony implant bed. *Arch Otorhinolaryngol* 1984; 240:115-9
- Spector M, Harmond SL, Kreutner A. Characteristics of tissue ingrowth into proplast and porous polyethylene ingrowths in bone. *J Biomed Mat Res* 1979; 13:677-81
- Dougherty WR, Wellisz T. The natural history of alloplastic implants in orbital floor reconstruction: an animal model. *J Craniiofac Surg* 1994; 5:26-32.
- Shaber EP. Vertical interpositional augmentation genioplasty with porous polyethylene. *Int J Oral Maxillofac Surg* 1987; 16:678-81.
- Wellisz T, Dougherty W, Gross J. Craniofacial applications for the Medpor porous polyethylene flexblock implant. *J Craniofac Surg* 1992; 3:101-7.
- Karcsh JW, Dresner SC. High-density porous polyethylene (Medpor) as a successful anophthalmic socket implant. *Ophthalmol* 1994; 101:1688-95.
- Couldwell WT, Chen T.C, Weiss MH, Fukushima T, Dougherty W. Cranioplasty with the Medpor porous polyethylene flexblock implant. *J Neurosurg* 1994; 81:483-6.
- Romano JJ, Iliff NT, Manson PN. Use of Medpor porous polyethylene implants in 140 patients with facial fractures. *J Craniofac Surg* 1993; 4:142-7.