

A Life-Threatening Condition, Type III Endoleak Presented with Persistent Hiccup

Hayatı Tehdit Eden Bir Durum, İnatçı Hıçkırık ile Kendini Gösteren Tip III Endoleak

^{id} Mehmet Beşir AKPINAR^a, ^{id} Barış UYMAZ^b, ^{id} Fatih KOÇ^c, ^{id} Nurgül UZUN^d

^aDepartment of Cardiovascular Surgery, İstinye University Faculty of Medicine, İstanbul, Türkiye

^bClinic of Cardiovascular Surgery, Medical Park Antalya Hospital, Antalya, Türkiye

^cDepartment of Cardiology, İstinye University Faculty of Medicine, İstanbul, Türkiye

^dClinic of Neurology, Medical Park Antalya Hospital, Antalya, Türkiye

ABSTRACT Abdominal aortic aneurysm is a condition that the size of the aorta increased more than 1.5 times in normal size. The most clinical symptom is abdominal pulsatile mass, abdominal pain and back pain. Rupture is a major and life-threatening complication. Endovascular aneurysm repair (EVAR) is the most preferred minimally invasive technique for treatment of abdominal aortic aneurysms in recent years. Type III endoleak is a rare and mortal complication of EVAR. Persistent hiccup related to EVAR complication is very rare. We couldn't find similar case in the literature. We present a 72-year-old male patient-with history of EVAR 5 years ago-who applied to the hospital with persistent hiccups for 15 days and was diagnosed with Type III endoleak. The aim of this report is to highlight this rare interesting and life-threatening clinical condition of EVAR complication, presenting with persistent hiccups.

Keywords: Hiccup; aortic aneurysm; abdominal aorta; endovascular procedures; endoleak

ÖZET Abdominal aort anevrizması, aort boyutunun normal boyutundan 1,5 kattan fazla artması durumudur. En sık klinik semptom karında pulsatil kitle, karın ağrısı ve sırt ağrısıdır. Rüptür önemli ve yaşamı tehdit eden bir komplikasyondur. Endovasküler anevrizma onarımı [endovascular aneurysm repair (EVAR)], son yıllarda abdominal aort anevrizmalarının tedavisinde en çok tercih edilen minimal invaziv tekniktir. Tip III kaçak, EVAR'ın nadir ve ölümcül bir komplikasyonudur. Literatür taramamızda benzer bir yayın bulamadık. EVAR komplikasyonuna bağlı kalıcı hıçkırık çok nadirdir. Bu çalışmada 5 yıl önce EVAR öyküsü olan 72 yaşında, 15 gündür inatçı hıçkırık şikâyeti ile hastaneye başvuran ve Tip III kaçak tanısı konulan erkek hastayı sunuyoruz. Bu raporun amacı, kalıcı hıçkırıklarla ortaya çıkan EVAR komplikasyonunun bu nadir ilginç ve yaşamı tehdit eden klinik durumunu vurgulamaktır.

Anahtar Kelimeler: Hıçkırık; aort anevrizması; abdominal aort; endovasküler girişim; endoleak

Hiccups are distinctive sounds caused by contraction of the inspiratory muscles, including the diaphragm, and culminate in abrupt closure of the glottis. Hiccups are mostly transient and last in seconds or minutes. If it persists more than 48 hours; it's classified as "persistent hiccups", longer than 1 month classified as resistant hiccups. Main reasons of persistent hiccups are gastrointestinal, thoracic, metabolic disorders and central neurologic abnormalities that cause irritation of phrenic nerve, vagus nerve, or thoracic sympathetic fibers.¹ Hiccups asso-

ciated with major arterial pathologies have been detected in the literature with aortic dissections and aortic aneurysms.²⁻⁴ Endovascular aneurysm repair (EVAR) is a minimally invasive procedure that used to manage abdominal aortic aneurysms (AAA). Type III endoleak is an important complication, defined as continued blood flow in the aneurysm between endograft components or fabric disruption and nearly nine times increased risk of aortic rupture.⁵

We present a rare case of a 72-year-old male patient who applied to the hospital with the complaint of

Correspondence: Mehmet Beşir AKPINAR

Department of Cardiovascular Surgery, İstinye University Faculty of Medicine, İstanbul, Türkiye

E-mail: besirakpinar@gmail.com



Peer review under responsibility of Türkiye Klinikleri Journal of Medical Sciences.

Received: 04 Nov 2022

Received in revised form: 19 Nov 2022

Accepted: 21 Nov 2022

Available online: 30 Nov 2022

2146-9040 / Copyright © 2023 by Türkiye Klinikleri. This is an open access article under the CC BY-NC-ND license (<http://creativecommons.org/licenses/by-nc-nd/4.0/>).

persistent hiccups, was diagnosed with Type III endoleak in imaging studies, and underwent urgent open surgical repair.

CASE REPORT

A 72-year-old male presented with persistent hiccup which was continuous for 15 days. He was treated by proton pump inhibitor and chlorpromazine infusion for 10 days in another center. He also had faint abdominal pain, but he was considered that pain was because of hiccups. The patient had no previous history of hiccup, chest pain, malignancy, and trauma. He has a history of endovascular abdominal aortic aneurysm stent graft implantation (EVAR) 5 years ago [AFX bifurcated stent graft BA25-80/116-40 and AFX Vela proximal endograft system A34-34/C100-020 V (Endologix-USA)] in another center. He stated that there was no problem in the post-procedure follow-ups, and he did not have any complaints about abdominal aortic aneurysm. The last follow-up computed tomography (CT) scan was 2 years ago. Lumen was intact, the diameter of the lumen was 28 mm, diameter of the EVAR lumen was 37 mm, there was

around 1 cm thick thrombus inside the EVAR graft, thrombosed aneurysm diameter was 62 mm according to report. Renal arteries and suprarenal intestinal arteries were intact.

He was admitted to our center because of persistent hiccups. Intravenous chlorpromazine infusion proton pump inhibitor and Baclofen 10 mg 1x3 oral tablet treatments were started by neurologist. Hiccup symptom was diminished on the second day of treatment. Chest and abdominal contrast CT were done because of history of EVAR. CT scan revealed that there was 140 mm in length and 68x67 mm diameter infra renal abdominal aortic aneurysm. The main body of aortobiiliac EVAR stent graft was separated from the graft overlapping zone. This condition was determined as Type III endoleak. The alignment of the EVAR graft was completely distorted ([Figure 1](#), [Figure 2](#)). The blood tests revealed slightly elevated white blood cell (9.51 K/uL), and elevated C-reactive protein (199.62 mg/L) level. There was no obvious abdominal aortic pulsation on physical examination. Hemodynamic condition was stable, peripheral pedal pulses were palpable.

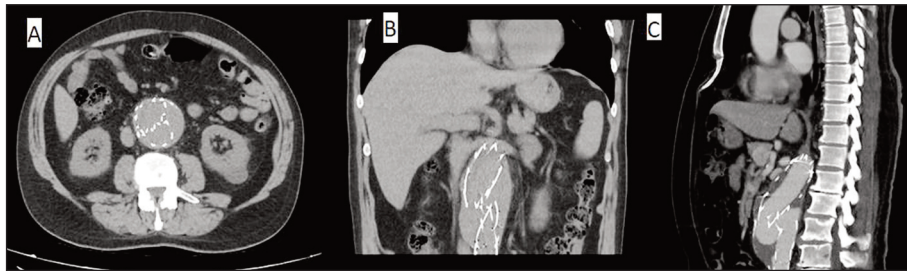


FIGURE 1: Computed tomography images of Type III endoleak and abdominal aortic aneurysm. A: Axial; B: Coronal; C: Sagittal images.

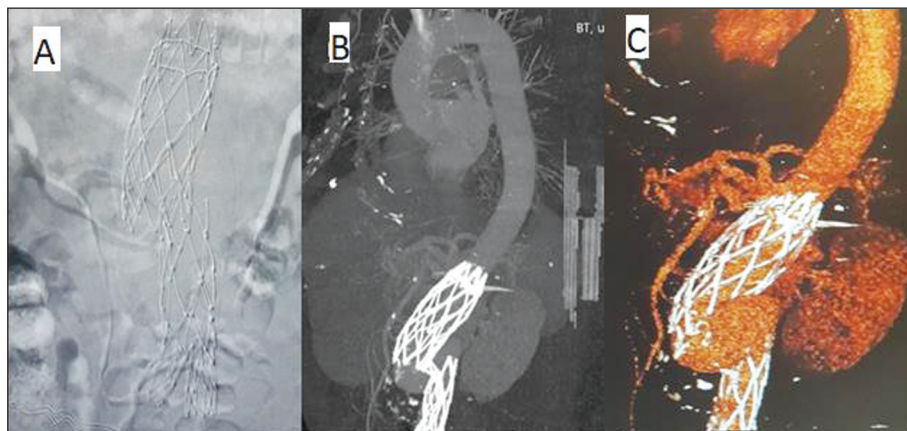


FIGURE 2: Images of Type III endoleak. The graft ends are separated as siphon-like configuration. A: Angiographic image; B, C: 3D computed tomography reconstruction images.

The patient condition was not suited for endovascular stent graft implantation because of siphon-like configuration of the anatomy and angulation as seen in the [Figure 2](#). He was prepared for open surgery. Coronary artery catheterization revealed non critical coronary artery atherosclerosis. Ejection Fraction was 55% and hypertensive left ventricular hypertrophy were discovered on echocardiography study.

Surgery was done by median laparotomy incision. Removing of the graft could damage the renal arteries and the aorta because of supra renal attachment of the hooks. Therefore, an aortic cross clamp was placed to infra-renal abdominal aorta. Distal cross clamps were placed to common iliac arteries. The aneurysm sac was opened. The graft parts were fused to surrounding aorta. Two metallic rings from the proximal and distal ends of EVAR graft were removed from the attachment points and a 30 mm Dacron tube graft interposition was performed. Postoperative course was uneventful, and the patient was discharged home on the 5th postoperative day by oral clopidogrel, cephalosporin and Baclofen.

Patient read through the manuscript and gave a written informed consent to publish the images and the article.

DISCUSSION

Hiccups reflex could be triggered either central or peripheral stimuli. Central causes are mostly related by central nervous system diseases, toxic-metabolic disturbances, psychogenic diseases and drugs.¹ Peripheral causes that stimulate the vagus nerve, phrenic nerve, and efferent fibers of the sympathetic chain from T6 to T12 include gastrointestinal disorders, thoracic disorders, and surgical and post-operative conditions.¹⁻³

Aortic aneurysm is a condition that the enlargement of the aortic diameter greater than 1.5 times normal size. They usually discover incidentally. Abdominal aortic aneurysm causes 1.3% of all deaths among mean aged 65-85 years. The overall rate of mortality for ruptured AAA is between 65% and 85%.⁶

EVAR has been an increasingly used treatment method in the treatment of AAA in recent years. However, endoleak is a significant drawback of EVAR procedure.

Type III endoleak means persistent blood flow through the body of the graft. Type III-a endoleak refers to separation of the main graft body from the limb or proximal or distal extension. Type III-b endoleak means there is a defect in the graft, such as a tear, break or fracture.⁷ Endoleak is a life-threatening complication because of high risk of abdominal aortic distension, and they may increase risk of rupture nine times according to elective AAA.⁵ Correction of the Type III endoleak could be done either additional endovascular intervention, open surgery, or combined procedures.⁸ In our case, the parts of EVAR graft were totally dislodged and the angulation between the parts was unsuitable for endovascular approach. Therefore, open surgery was preferred for correction of late Type III endoleak.

There are some reports suggesting endograft clamping for open repair of EVAR complications, especially in grafts with suprarenal attachment.⁹

We also preferred endograft clamping because of the severe adhesions of the graft ends and the aortic wall.

The most common clinical manifestation of abdominal aortic aneurysm is abdominal discomfort, pulsating mass in the abdomen, inguinal pain, and back pain. Abdominal aortic rupture is a serious condition, and its symptoms vary from, abdominal distension, severe back pain, abdominal pain, hypotension, cardiogenic shock, and even collapse.

There are few case reports that point association between hiccups and aortic aneurysms.^{2,3}

There is not enough information about hiccups mechanism for aortic disease. A reasonable assumption is that main branches of the aorta can impinge on the phrenic nerve due to close vicinity and can contribute to hiccups.² Most of the cardiovascular events reported with hiccups appear to be triggered by acute conditions such myocardial infarction (mostly inferior myocardial infarction), aortic dissection, or pulmonary embolism.^{4,10,11} In our case, it is possible that Type III leakage in the endovascular

graft caused sudden distension in the abdominal aorta and this situation triggered hiccups.

Our patient presented with persistent hiccups for 15 days. He was diagnosed as late Type III-a EVAR graft endoleak. We believe that the ethology of his hiccups was a manifestation of abdominal aortic distension and subsequent vagal and phrenic nerve irritation.

Source of Finance

During this study, no financial or spiritual support was received neither from any pharmaceutical company that has a direct connection with the research subject, nor from a company that provides or produces medical instruments and materials which may negatively affect the evaluation process of this study.

Conflict of Interest

No conflicts of interest between the authors and / or family members of the scientific and medical committee members or members of the potential conflicts of interest, counseling, expertise, working conditions, share holding and similar situations in any firm.

Authorship Contributions

Idea/Concept: Fatih Koç; **Design:** Mehmet Beşir Akpınar; **Control/Supervision:** Mehmet Beşir Akpınar, Barış Uyuz; **Data Collection and/or Processing:** Nurgül Uzun, Mehmet Beşir Akpınar; **Analysis and/or Interpretation:** Mehmet Beşir Akpınar; **Literature Review:** Mehmet Beşir Akpınar; **Writing the Article:** Mehmet Beşir Akpınar; **Critical Review:** Mehmet Beşir Akpınar; **References and Fundings:** Mehmet Beşir Akpınar.

REFERENCES

1. Bra-uelas Quiroga J, Urbano Garcia J, Bola-os Guedes J. Hiccups: a common problem with some unusual causes and cures. *Br J Gen Pract.* 2016;66(652):584-6. Erratum in: *Br J Gen Pract.* 2017;67(654):13. [[Crossref](#)] [[PubMed](#)] [[PMC](#)]
2. Loft LM, Ward RF. Hiccups. A case presentation and etiologic review. *Arch Otolaryngol Head Neck Surg.* 1992;118(10):1115-9. [[Crossref](#)] [[PubMed](#)]
3. Stine RJ, Trued SJ. Hiccups: an unusual manifestation of an abdominal aortic aneurysm. *JACEP.* 1979;8(9):368-70. [[Crossref](#)] [[PubMed](#)]
4. Ullah W, Khanal S, Sattar Z, Roomi S, Sattar Y, Figueredo VM. Singultus as a presentation for aortic dissection. *IHJ Cardiovascular Case Reports (CVCR).* 2019;3(2):84-6. [[Crossref](#)]
5. Harris PL, Vallabhaneni SR, Desgranges P, Becquemin JP, van Marrewijk C, Laheij RJ. Incidence and risk factors of late rupture, conversion, and death after endovascular repair of infrarenal aortic aneurysms: the EUROSTAR experience. European Collaborators on Stent/graft techniques for aortic aneurysm repair. *J Vasc Surg.* 2000;32(4):739-49. [[Crossref](#)] [[PubMed](#)]
6. Thompson MM. Controlling the expansion of abdominal aortic aneurysms. *Br J Surg.* 2003;90(8):897-8. [[Crossref](#)] [[PubMed](#)]
7. Bucci F, Fiengo L, Valerio N, Ferdani M. Late Type IIIb endoleak after endovascular aneurysm repair: case report and review of the literature. *G Chir.* 2011;32(6-7):329-33. [[PubMed](#)]
8. Maleux G, Poorteman L, Laenen A, Saint-Lébes B, Houthoofd S, Fourneau I, et al. Incidence, etiology, and management of Type III endoleak after endovascular aortic repair. *J Vasc Surg.* 2017;66(4):1056-64. [[Crossref](#)]
9. Perini P, de Troia A, Tecchio T, Azzarone M, Bianchini Massoni C, Salcuni P, et al. Infrarenal endograft clamping in late open conversions after endovascular abdominal aneurysm repair. *J Vasc Surg.* 2017;66(4):1048-55. [[Crossref](#)] [[PubMed](#)]
10. Torun E, Durmuş N. Pulmoner embolide farklı bir başvuru şikayeti: hıçkırık [An unusual presenting symptom in pulmonary embolism: hiccup]. *J Kartal TR.* 2011;22(1):25-8. [[Crossref](#)]
11. Yuan SM. Myocardial ischemia presenting with hiccups. *J Coll Physicians Surg Pak.* 2019;29(5):469-73. [[Crossref](#)] [[PubMed](#)]