






Michels Syndrome: A Case Report from Turkey and Review of Literature

 Murat DOĞAN,^a
 İbrahim HIRA,^a
 Mustafa ŞAHİN,^a
 Murat ERDOĞAN,^b
 Arzu KARATEPE HAŞHAŞ^c

Clinics of
^aEar-Nose-Throat,
^bGenetics,
^cOphthalmology,
 Health Science University
 Kayseri Training and Research Hospital,
 Kayseri

Received: 10.10.2017
 Received in revised form: 28.12.2017
 Accepted: 29.12.2017
 Available online: 17.09.2018

Correspondence:
 İbrahim HIRA
 Health Science University
 Kayseri Training and Research Hospital,
 Clinic of Ear-Nose-Throat,
 Kayseri, TURKEY
 dr.ibrahimhira@gmail.com

ABSTRACT A 4-year and 7 month-old boy was admitted to our facility with the complaints of blepharophimosis, blepharoptosis, and epicanthus inversus in association with hypertelorism, cleft palate, mental deficiency, hearing loss, and craniosynostosis. The patient also had umbilical depression and small hands with bilaterally short fifth fingers. These clinical features led us to think that they are the components of a single syndrome, which may be referred to as “3MC1 syndrome.” The main characteristics of 3MC1 syndrome are the facial dysmorphic traits and include hypertelorism, blepharophimosis and blepharoptosis. Other related symptoms are cleft lip and palate, postnatal growth deficit, cognitive impairment and hearing loss, craniosynostosis, radioulnar synostosis and genital and vesicorenal anomalies. The etiological causes of 3MC1 are still unknown.

Keywords: Oculopalatoskeletal syndrome; michels syndrome; carnevale syndrome; malpuech syndrome; OSA syndrome

Michels et al. and De la Paz et al. have described three brothers and a sister with the triad of blepharophimosis, blepharoptosis, and epicanthus inversus (BPE triad), in addition to a developmental defect in the anterior segment of the eye, cleft lip-palate, and some minor skeletal abnormalities. The studies of Cunniff and Jones and Guion-Almeida and Rodini have corroborated the assumption that a similar malformative pattern represents a distinct syndrome, named Michels or oculo-palatoskeletal syndrome. The effects of an autosomal recessive inheritance have been supported in the study of Guion-Almeida and Rodini that examined the female child of unhealthy consanguineous parents. In this study, the authors examined an affected female and tried to describe the key characteristics of this syndrome and its relationships with closely related entities.¹⁻⁴

There are certain syndromes that show asymmetry of the skull, eyelid anomalies with or without the involvement of anterior chamber, cleft lip and also sometimes, cleft palate, umbilical anomalies, and/or a disturbance of growth and cognitive development. The names of these syndromes are Malpuech syndrome, Michels syndrome, Carnevale syndrome, OSA syndrome, and Mingarelli syndrome, while some authors also include Juberg-Hayward syndrome into this category. Titomanlio et al. have suggested that these syndromes are the parts of a single clinical entity, and introduced the name “3MC1 syndrome” (3MC1 for Malpuech-Michels-Mingarelli-Carnevale).⁵

The main characteristics of 3MC1 syndrome are the facial dysmorphic traits and include hypertelorism, blepharophimosis, blepharoptosis, and highly arched eyebrows, which have been observed in 70%-95% of the patients (Table 1). Other associating symptoms are cleft lip and palate, post-

TABLE 1: The 3MC syndrome-comparison of features.

Clinical features	Carnevale	Mingarelli (OSA)	Michels	Malpuech
AR Inheritance	+	+	+	+
Eyelid triad	+	+	+	±
Hypertelorism	+	+	+	+
Arched eyebrows	+	+	+	+
Hearing loss	+	+	+	+
Umbilical depression	+	+	+	-
Umbilical hernia	-	-	-	+
Diastasis recti	+	+	-	+
Radioulnar synostosis	+	+	+	+
Prominent coccyx	-	-	-	+
Mental retardation	+	-	±	±
Postnatal growth deficiency	+	-	+	+
Telechantus	-	+	+	+
Bifid tip of the nose	-	-	-	+
Dysplastic/low set ears	+	-	-	-
Down-turned corners of the mouth	+	-	-	+
Cleft/lip palate	-	-	+	+
Accessory nipple	+	-	+	-
Cryptorchid testes	+	-	-	+
Short clinodactylous fifth finger	-	+	+	-
Lordosis/scoliosis	+	+	-	-
Spina bifida occulta	+	-	+	-
Dislocations of hip	+	-	-	-

natal growth deficiency, cognitive impairment, and hearing loss, which have been observed in 40%–68% of patients. Craniosynostosis, radioulnar synostosis, and genital and vesicorenal anomalies have been reported in 20-30% of the patients. Anterior chamber defects, cardiac anomalies, caudal appendage, umbilical hernia/omphalocele, and diastasis recti are among the rare characteristic signs of the 3MC1 syndrome. To date, 22 patients from 20 families have been identified with this syndrome. However, the underlying causes for the development of 3MC1 have remained unclear.⁶⁻⁹

CASE REPORT

Our case was a 4-year and 7-month-old boy, who was the second born child in his family. First born child of the family died at the age of 3 years. The family immediately noticed the presence of a cleft

lip and palate in the child because of the feeding difficulties. He had developmental delay, which was evidenced by his walking and speaking inability. Physical examination in our unit revealed the presence of facial dysmorphism including blepharophimosis, blepharoptosis, epicanthus inversus, telecanthus, and a bilateral cleft lip and palate (Figures 1, 2). The anterior fontanelle was found to be extremely large. The patient had also low set ears and approximately 1-2 cm peculiar supra-umbilical depression (Figure 3). His hands were observed to be small with bilaterally short fifth fingers (Figure 4), while his feet were found to be broad. A severe axial hypotonia was also noticed. His psychomotor development was found to be mildly retarded, while the lingual development was determined to be completely absent. Audiometric assessment revealed a moderate and bilateral conductive hearing loss.

INFORMED CONSENT

Written consent has been obtained for the use of photographs.

DISCUSSION

The Carnevale, Mingarelli, Malpuech, and Michels syndromes are rare autosomal recessive disorders and they have recently been postulated to be the components of the same clinical entity, named “3MC1 syndrome.”¹⁰⁻¹³

A mutated gene called Mannan binding lectin serine protease-1 gene (MASP 1) encodes the MASP1 enzyme to facilitate the lectin complementation pathway by amplifying its immune reaction activation in response to threatening stimuli.⁹

This gene is located on chromosome 3q27.3 (15) and its mutation leads to anomalies in the embryonic craniofacial cartilage, heart, bronchi, kidney, and vertebral bodies, which are the clinical features of 3MC1 syndrome.^{5,7,13} The characteristic signs of Michels syndrome are the BBE (blepharophimosis, blepharoptosis, and epicanthus inversus) triad, telecanthus and highly arched eyebrows, which have been observed in up to 80% of the patients.¹³

Our proband shared these phenotypical signs with Malpuech, Carnevale, and Mingarelli syn-

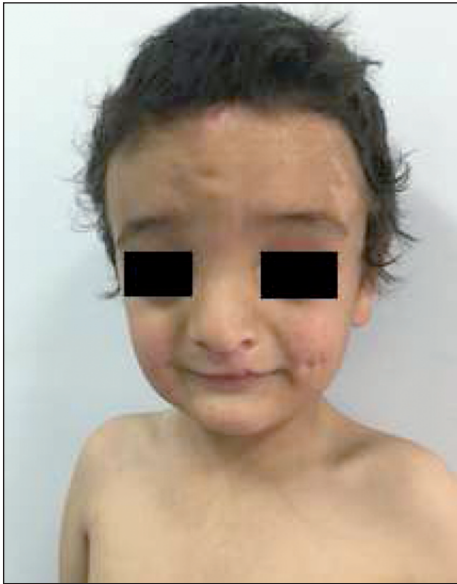

FIGURE 1: The presence of facial dysmorphism including blepharophimosis, blepharoptosis, epicanthus inversus, and telecanthus.

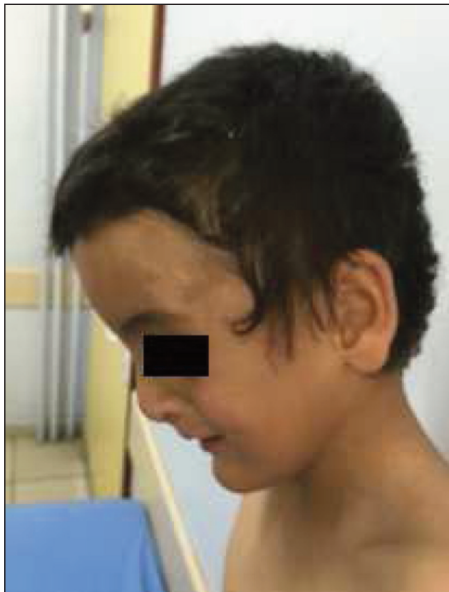

FIGURE 2: The presence of extremely large anterior fontanel and also low set ears.

dromes. On the contrary, he also had low set ears but no skeletal defects, as reported earlier by Adedayo A Adio.¹⁴

The patient had neither radioulnar synostosis nor abdominal diastases.^{2,4,6} Moreover, he had middle ear dysfunction, suggesting a certain level of hearing loss, as observed in an audiometry test (pure tone audiometry and tympanometry).¹⁴ The cleft lip and palate and the postnatal growth defi-

ciency were among the other characteristic clinical signs that have been reported in 40-68% of all the 3MC1 cases.^{6,14,15}

Some of the rare findings include anterior chamber defects, cardiac anomalies, accessory nipples, tuberous angioma of the thorax, caudal appendage, umbilical hernia (omphalocele), and diastasis recti. These findings have been reported in <20-30% of all the 3MC1 cases.^{7,13}

However, our patient displayed many phenotypical signs similar to other reported Michels syndrome cases that demonstrated all the characteristics

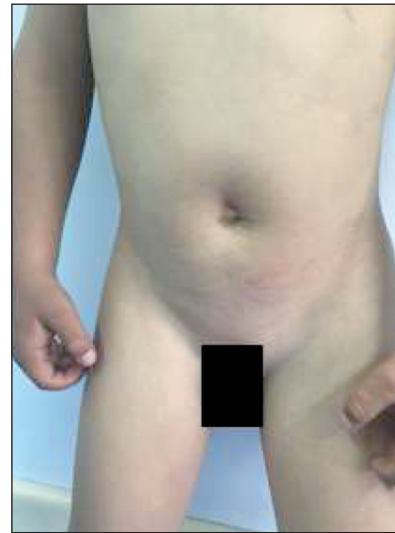

FIGURE 3: The presence of approximately 1-2 cm peculiar supra-umbilical depression.

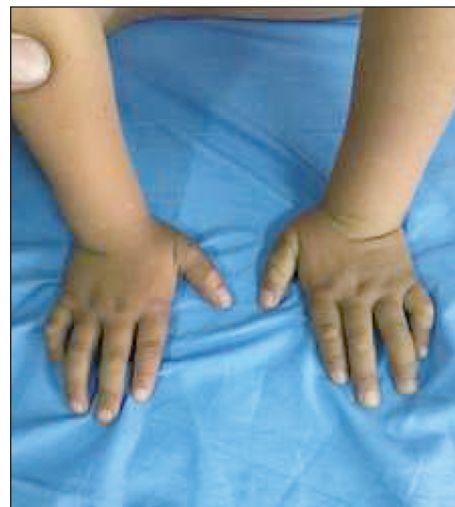

FIGURE 4: Small hands with bilaterally short fifth fingers.

except the radioulnar synostosis and anterior chamber defects.^{4,6}

All the patients (including ours) affected by 3MC1 syndrome demonstrate BBE triad in addition to the presence of a cleft lip and palate. Although in the other syndromes the ears were large and fleshy, our patient exhibited low set ears. However, the hearing was actually normal.

Sometimes, certain skeletal defects such as spina bifida occulta, cranial asymmetry, and the abnormality of the occipital bone, besides the micrognathia were reported in few cases.^{4,10} These findings were not observed in our patient. Earlier studies reported some cases with large anterior fontanelles, severe axial dystonia, poor speech, moderate psychomotor retardation and a bilateral conductive hearing loss, which were all present in our patient, at different levels.^{6,14}

Further clinical reports are still needed to determine the degree of intra-familial clinical variability of Michels syndrome, to confirm its key characteristics and to solve the nosological problem raised by phenotypic overlaps between Carnevale, OSA, and Malpuech syndromes. As long as the diagnosis remains non-molecular, the clinical boundaries of each of the four syndromes will remain a matter of subjective appraisal. We believe that the similarities between the four syndromes are higher and more significant than their differences and that the variability within a defined group of patients is even higher than the variability between them. For these reasons,

expanding Hall's proposal, we suggest that the four entities fit better into a single recessive disease spectrum than as separate disorders. We suggest referring to this clinical spectrum as "3MC1 syndrome" (for Malpuech-Michels-Mingarelli-Carnevale).

Eventually, Michels syndrome is a very rare case and is a component of the 3MC1 syndrome. These patients refer to the Ear, Nose and Throat clinic for various reasons, especially cleft palate lip pathologies. We wanted to share this rare case in order to contribute to the literature.

Source of Finance

During this study, no financial or spiritual support was received neither from any pharmaceutical company that has a direct connection with the research subject, nor from a company that provides or produces medical instruments and materials which may negatively affect the evaluation process of this study.

Conflict of Interest

No conflicts of interest between the authors and / or family members of the scientific and medical committee members or members of the potential conflicts of interest, counseling, expertise, working conditions, share holding and similar situations in any firm.

Authorship Contributions

Concept: İbrahim Hıra; **Design:** İbrahim Hıra, Murat Doğan; **Supervision:** Murat Doğan; **Data Collection and/or Processing:** Mustafa Şahin; **Analysis and/or Interpretation:** Murat Erdoğan; **Writing:** Murat Erdoğan, Murat Doğan, İbrahim Hıra; **Critical Review:** Murat Erdoğan, Arzu Karatepe Haşhaş; **Revision of the Manuscript:** Murat Doğan.

REFERENCES

1. Michels VV, Hittner HM, Beaudet AL. A clefting syndrome with ocular anterior chamber defect and lid anomalies. *J Pediatr* 1978;93(3): 444-6.
2. De La Paz MA, Lewis RA, Patrinely JR, Merin L, Greenberg F. A sibship with unusual anomalies of the eye and skeleton (Michels' syndrome). *Am J Ophthalmol* 1991;112(5): 572-80.
3. Cunniff C, Jones KL. Craniosynostosis and lid anomalies: report of a girl with Michels syndrome. *Am J Med Genet* 1990;37(1):28-30.
4. Guion-Almeida ML. Apparent Malpuech syndrome: report on three Brazilian patients with additional signs. *Am J Med Genet* 1995;58(1): 13-7.
5. Titomanlio L, Bennaceur S, Bremond-Gignac D, Baumann C, Dupuy O, Verloes A. Michels syndrome, Carnevale syndrome, OSA syndrome, and Malpuech syndrome: variable expression of a single disorder (3MC syndrome)? *Am J Med Genet A* 2005;137A(3): 332-5.
6. Al Kaissi A, Klaushofer K, Safi H, Chehida FB, Ghachem MB, Chaabouni M, et al. Asymmetrical skull, ptosis, hypertelorism, high nasal bridge, clefting, umbilical anomalies, and skeletal anomalies in sibs: is Carnevale syndrome a separate entity? *Am J Med Genet A* 2007;143(4):349-54.
7. Leal GF, Silva EO, Duarte AR, Campos JF. Blepharophimosis, blepharoptosis, defects of the anterior chamber of the eye, caudal appendage, radioulnar synostosis, hearing loss and umbilical anomalies in sibs: 3MC syndrome? *Am J Med Genet A* 2008;146A(8): 1059-62.

8. Priolo M, Ciccone R, Bova I, Campolo G, Lagana C, Zuffardi O. Malpuech syndrome: broadening the clinical spectrum and molecular analysis by array-CGH. *Eur J Med Genet* 2007;50(2):139-43.
9. Roorcyk C, Diaz-Font A, Osborn DP, Chabchoub E, Hernandez-Hernandez V, Shamseldin H, et al. Mutations in lectin complement pathway genes COLEC11 and MASP1 cause 3MC syndrome. *Nat Genet* 2011;43(3):197-203.
10. Carnevale F, Krajewska G, Fischetto R, Greco MG, Bonvino A. Ptosis of eyelids, strabismus, diastasis recti, hip defect, cryptorchidism, and developmental delay in two sibs. *Am J Med Genet* 1989;33(2):186-9.
11. Mingarelli R, Castriota Scanderbeg A, Dallapiccola B. Two sisters with a syndrome of ocular, skeletal, and abdominal abnormalities (OSA syndrome). *J Med Genet* 1996;33(10):884-6.
12. Malpuech G, Demeocq F, Palcoux JB, Vanlieferinghen P. A previously undescribed autosomal recessive multiple congenital anomalies/mental retardation (MCA/MR) syndrome with growth failure, lip/palate cleft(s), and urogenital anomalies. *Am J Med Genet* 1983;16(4):475-80.
13. Venkatraman Girija U, Furze CM, Gingras AR, Yoshizaki T, Ohtani K, Marshall JE, et al. Molecular basis of sugar recognition by collectin-K1 and the effects of mutations associated with 3MC syndrome. *BMC Biol* 2015;13:27.
14. Adio AA, Kekunnaya R, Lingappa L. Michels syndrome: the first case report from India and review of literature. *Indian J Ophthalmol* 2014;62(9):954-8.
15. Chinen Y, Naritomi K. Malpuech facial clefting syndrome in a Japanese boy with cardiac defects. *Jpn J Hum Genet* 1995;40(4):335-8.