

# An Unusual Cause of Headache: Osseous Hemangioma of the Cranium: Case Report

## Baş Ağrısının Nadir Bir Nedeni: Kafatasının Kemik Hemanjiyomu

Nurdan ÇAY, MD,<sup>a</sup>  
Ercan KARABEKİR, MD,<sup>a</sup>  
Naif ERDOĞAN, MD,<sup>a</sup>  
Hüseyin ÇETİN, MD,<sup>a</sup>  
Mustafa KARAOĞLANOĞLU, MD<sup>a</sup>

<sup>a</sup>Department of Radiology,  
Atatürk Education and  
Research Hospital, ANKARA

Geliş Tarihi/Received: 06.04.2008  
Kabul Tarihi/Accepted: 17.06.2008

Yazışma Adresi/Correspondence:  
Nurdan ÇAY, MD  
Atatürk Education and  
Research Hospital,  
Department of Radiology, ANKARA  
nurdanyigit@yahoo.com

**ABSTRACT** Primary intraosseous hemangiomas are rare benign tumors developed from the intrinsic vasculature of the osseous tissue. Cranium is one of the most involved parts of the human body. Although they are generally asymptomatic, some complications related to bleeding and mass compression might be seen. Diagnosis of osseous hemangiomas by radiological methods can be made promptly. We present a 25 years old female with resistant headache to multidrug regimen of analgesics, radiologically diagnosed as osseous hemangioma of the cranium. In addition, imaging characteristics of osseous hemangioma of the cranium were described.

**Key Words:** Hemangioma, cavernous; magnetic resonance imaging; tomography

**ÖZET** Kemik hemanjiyomları kemik dokunun kendisine ait olan damarsal yapılarından köken alan nadir görülen, iyi huylu tümöral yapılar olarak tanımlanmışlardır. Kafatası insan vücudunda en sık etkilenen yapılardan biri olarak bildirilmiştir. Genellikle herhangi bir şikâyete neden olmadan varlıklarını devam ettirseler de, kanama ve kitle basısına bağlı bazı komplikasyonlara neden olabilirler. Kemik hemanjiyomlarının tanısı radyolojik inceleme yöntemleri ile yapılabilir. Biz bu sunumda, çok sayıda analjezik ilaç tedavisine dirençli baş ağrısı yakınması olan, radyolojik yöntemler ile kafatasının kemik hemanjiyomu tanısı konan, 25 yaşında kadın olgunun bulgularını sunmaya çalıştık. Ek olarak, kafatasının kemik hemanjiyomunun bazı görüntüleme özellikleri de tartışıldı.

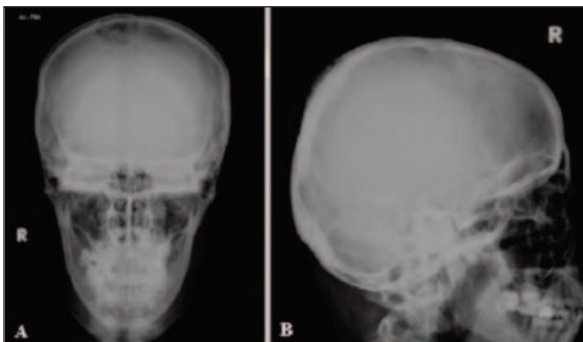
**Anahtar Kelimeler:** Hemanjiyoma; kavernöz; manyetik rezonans görüntüleme; tomografi

**Türkiye Klinikleri J Neur 2008;3(3):124-6**

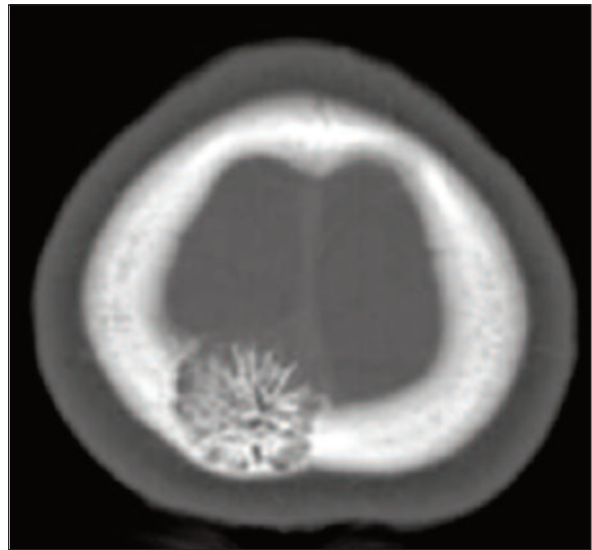
Osseous hemangiomas are benign neoplasms arising from the intrinsic vasculature of the osseous tissue.<sup>1</sup> Approximately 1% of all primary bone neoplasms consist of osseous hemangiomas. Hemangiomas of the vertebral column and the cranium are the most frequent ones. Based on the literature, these lesions occur more frequently in female patients.<sup>2</sup> Although they are generally asymptomatic, some complications related to bleeding and mass compression might be seen as in our case.<sup>3</sup> Involvement of the parietal region is relatively rare although frontal region is the most frequent site of involvement.<sup>2</sup> Diagnosis of osseous hemangiomas by various radiologic methods might be made. We present a case with resistant headache to multidrug regimen of analgesics was radiologically diagnosed as osseous hemangioma of the cranium.

## CASE REPORT

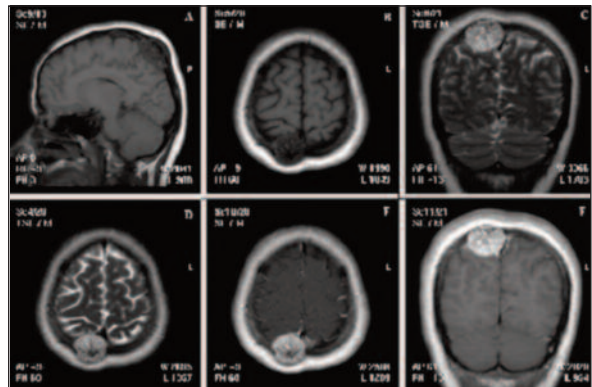
A 25 years old female was referred to the department of neurology with headache resistant to multidrug regimen of analgesics for a year. The patient had also realized a growing lump with 3 x 3 cm in size over the posterior part of parietal region during the last three months. No family history was found. No pain was complained by the patient upon examination. A firm, dome-shaped protrusion of the calvarium, covered by normal skin layer with hair was detected in physical examination. Physical examination and laboratory tests were otherwise normal. The plain X-ray films of the skull showed a well-circumscribed and radiolucent lesion with smooth contours that resembling a spoke-wheel on the posterior part of the right parietal bone (Figure 1A and B). A cranial computed tomography (CT) scan (Toshiba Aquilion 64, United States) was performed. The CT with an axial plane and bone window revealed an intraosseous lesion compressing intracranial structures in the posterior portion of the right parietal bone (Figure 2). Relationship with other cranial structures was assessed by magnetic resonance imaging (MRI) (Phillips Gyroscan Intera 1.5T, Best, The Netherlands). On T2-weighted images the lesion was predominantly hyperintense and on postcontrast T1-weighted images the lesion showed contrast enhancement. It was also observed that the lesion was originating from osseous tissue and compatible with an osseous hemangioma which was just com-



**FIGURE 1:** The plain X-ray film of the skull shows a well-circumscribed and radiolucent lesion with smooth contours that resembling a spoke-wheel with trabeculations radiating from a common center on the posterior part of the right parietal bone on anterior-posterior (A) and the right lateral projections (B).



**FIGURE 2:** Cranial computed tomography (CT) scan of the skull shows the same spoke-wheel like lesion originating from the intradiploic area of the cranium and compressing the intracranial structures on the posterior part of the right parietal bone.



**FIGURE 3:** Magnetic resonance imaging (MRI) of the cranium shows the same spoke-wheel like lesion with 3 x 3.5 cm in size located in the intradiploic area and shifting the posterior part of the right parietal lobe on sagittal T1-weighted (A), axial T1-weighted (B), coronal T2-weighted (C), axial T2-weighted (D), contrast-enhanced axial T1-weighted (E), and contrast-enhanced coronal T1-weighted (F) images.

pressing, not involving the parietal region of the brain (Figure 3A, B, C, D, E, and F).

## DISCUSSION

Intraosseous hemangiomas are rare benign neoplasms of vascular tissue, most commonly observed in the vertebral column followed by the skull. They develop from the diploic space of the calvarium, with preferential involvement of the outer layer.

The symptoms are generally pain and visible and/or palpable bony firm mass covered by normal skin tissue.<sup>4</sup> Neurological signs and symptoms are unusual because these neoplasms tend to grow externally. However, expansion into the cranial space has been reported as in our case.<sup>5</sup> Neurological deficits are usually due to compressive effect, with cranial nerve palsies, especially the seventh cranial one, facial nerve. Other complications such as localized pain, the sensation of mass effect and even epileptic episodes might occur. Histopathological feature of intraosseous hemangioma is endothelium-lined vascular channels surrounded by myxoid tissue interspersed between bony trabeculae resulting from osteoclastic remodeling and osteoblastic reinforcement by the growing vascular neoplasm. Plain radiography of the cranium is one of the most sensitive tools to identify intraosseous hemangioma as an intradiploic, well-circumscribed area of radiolucency with a spoke-wheel or sunburst pattern of trabeculations radiating from a common center. This characteristic appearance is due to thickening of pre-existing trabeculae, secondary to intramembranous bone tissue affected by the vascular channels. Further radiological tool, the CT scan shows an intradiploic lytic area with rarefaction and a honey-

comb pattern. The signal characteristics on MRI are variable. The lesion generally appears mottled and heterogeneous with both increased and decreased signal intensities on both T1- and T2-weighted images. The received signals depend on the quantity of slow-moving blood tissue and on the ratio of marrow tissue to fatty tissue within the lesion. Lesions with more fatty tissue demonstrate increased signal intensity on T1-weighted images.<sup>5</sup> Osseous hemangiomas typically enhance after administration of gadolinium. High signal intensity on T2-weighted images might be caused by pooling of blood. These features are radiological characteristics of intraosseous hemangiomas.<sup>5,6</sup> The differential diagnosis includes osteoma, aneurysmal bone cyst, giant cell tumor, fibrous dysplasia, sarcoma, meningioma, metastatic disease, Paget disease, dermoid and epidermoid cysts. Hemangiomas are typically angiographically occult lesions. Therefore, angiography is not a diagnostic method for the diagnosis.

In conclusion, the feature of osseous spicule formation resulting in a radiating sunburst pattern is perhaps more sensitive and specific for osseous hemangioma, particularly when combined with lesion hypervascularity on CT and contrast-enhanced MRI (CEMRI).

## REFERENCES

1. Khanam H, Lipper MH, Wolff CL, Lopes MB. Calvarial hemangiomas: report of two cases and review of the literature. *Surg Neurol* 2001;55:63-7.
2. Heckl S, Aschoff A, Kunze S. Cavernomas of the skull: review of the literature 1975-2000. *Neurosurg Rev* 2002;25:56-62.
3. Kaleem Z, Kyriakos M, Totty WG. Solitary skeletal hemangioma of the extremities. *Skeletal Radiol* 2000;29:502-13.
4. Ajja A, Oukacha N, Gazzaz M, Akhaddar A, Elmostarchid B, Kadir B, et al. Cavernous hemangioma of the parietal bone. A case report. *J Neurosurg Sci* 2005 ;49:159-62.
5. Liu JK, Burger PC, Harnsberger HR, Couldwell WT. Primary Intraosseous Skull Base Cavernous Hemangioma: Case Report. *Skull Base* 2003;13:219-28.
6. Dogan S, Kocaeli H, Sahin S, Korfali E, Saraydaroglu O. Large cavernous hemangioma of the frontal bone. *Neurol Med Chir (Tokyo)*. 2005;45:264-7.