

A Mortal Hypereosinophilic Syndrome Case Report Representing A Large Skin Necrosis

Geniş Deri Nekrozu Gösteren Mortal Hipereozinofilik Sendrom

İrfan ÖZYAZGAN, MD,^a
Teoman ESKİTAŞÇIOĞLU, MD,^a
Halit BAYKAN, MD,^a
Bülent TOKGÖZ, MD^b

^aDepartment of Plastic and
Reconstructive Surgery,
^bDepartment of Nephrology,
Erciyes University Faculty of Medicine,
Kayseri

Geliş Tarihi/Received: 15.07.2008
Kabul Tarihi/Accepted: 12.11.2008

Yazışma Adresi/Correspondence:
Teoman ESKİTAŞÇIOĞLU, MD
Erciyes University Faculty of Medicine,
Department of Plastic and
Reconstructive Surgery, Kayseri
TÜRKİYE/TURKEY
teoman@erciyes.edu.tr

ÖZET Hipereozinofilik sendrom nadir görülen bir lökoproliferatif sistem hastalığıdır. Hastalığın primer semptomları kardiyovasküler ve nörolojik sistemlere aittir. Sık görülen cilt lezyonları genellikle kaşıntılı eritematöz plak veya papüller şeklindedir. Steroid tedavisi ile hastalık başarılı şekilde tedavi edilmektedir. Bu çalışmada, hastalığın geç döneminde sağ inguinal bölgede geniş deri nekrozu nedeni ile kliniğimize başvuran, klinik ve laboratuvar muayeneler ve histopatolojik inceleme sonucu hipereozinofilik sendrom tanısı konan bir olgu sunulmuştur.

Anahtar Kelimeler: Hipereozinofilik sendrom; deri; nekroz

ABSTRACT Hypereosinophilic syndrome is a rare leukoproliferative system disease. Primary symptoms mainly belong to cardiovascular and neurological system. Common clinical skin lesions are pruritic and erythematous plaques and papules. Steroids have been sufficiently used to treat the disease. In this report, we describe a case who admitted to our clinic due to a large skin necrosis placed on right inguinal region in the late period of the disease and diagnosed as hypereosinophilic syndrome according to histopathological analysis of the biopsy specimen and clinical and laboratory examinations.

Key Words: Hypereosinophilic syndrome; skin; necrosis

Türkiye Klinikleri J Dermatol 2009;19(1):40-2

Idiopathic hypereosinophilic syndrome (HES) is a clinical entity that is classified in leukoproliferative disease group and characterized by prolonged eosinophilia and specific organ involvements; its etiology and pathogenesis is still unclear.¹ HES mainly affects middle-aged males and is fairly rare. The primary symptoms belong to cardiac and neurological involvement. The other dominant symptoms are hepatosplenomegaly, generalized lymphadenomegaly, myalgia, angioedema, skin rashes, fever and retinal lesions.^{1,2} Although skin involvement occurs in the majority of the patients (27-73%), onset with cutaneous lesions is very rare. Common clinical skin lesions are pruritic and erythematous plaques and papules.^{1,3} Several tests and further examinations are necessary for diagnosis. Possible tumorigenic causes, parasitic infestations, drug reactions and allergic statements should be explored. Chusid et al have defined three findings of the disease:

1. Eosinophilia more than 1500/mm³ in peripheral blood sample in the last six months,
2. Clinically absence of parasitic, allergic and other causes for eosinophilia, and
3. The presence of signs or symptoms of multi-organ involvement.⁴

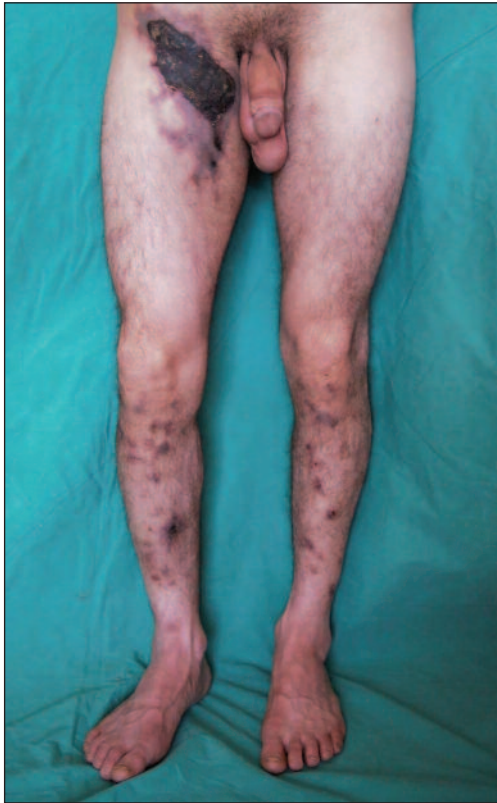

FIGURE 1: Appearance of skin necrosis in the right groin.

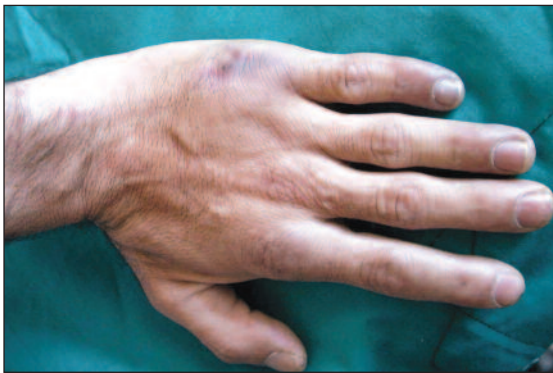

FIGURE 2: Appearance of fifth finger of the left hand.

CASE REPORT

A twenty eight years old male was admitted to our clinic with a discolored region in the right groin. The disease had begun with pruritic eruptions in lower extremities a month ago and spread to whole lower extremities. Finally the discolored region in the inguinal site widened despite several medications. The patient was a heavy smoker and had been using diphenylhydantoin for four years

due to epileptic attacks. In physical examination, a 13 x 10 cm-sized eschar that surrounded with 3-4 cm width blue-purple discoloration in right inguinal region extending inferiorly was noted (Figure 1). In addition, multiple purple rashes, some of them including centric 1 cm-sized eschar in both lower extremities and purple colored fifth finger of the left hand, were also detected (Figure 2).

The patient was preliminary diagnosed as an allergic vasculitis, because of using diphenylhydantoin for four years and had begun to use prednisolon (500 mg/day iv for first three days and than 60 mg/day po). A few days later the large eschar was excised and biopsy from normal skin was obtained. The underside of the eschar was not vital, so the co-

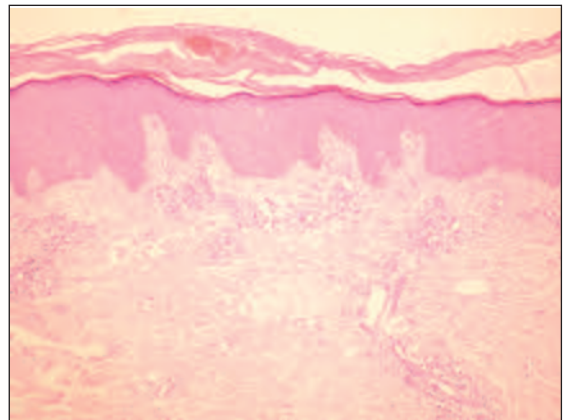


FIGURE 3A: Panoramic view of the upper part of the lesion. There are some hyperkeratosis, irregular acanthosis and a few mononuclear cells around the capillaries (HE x 100).

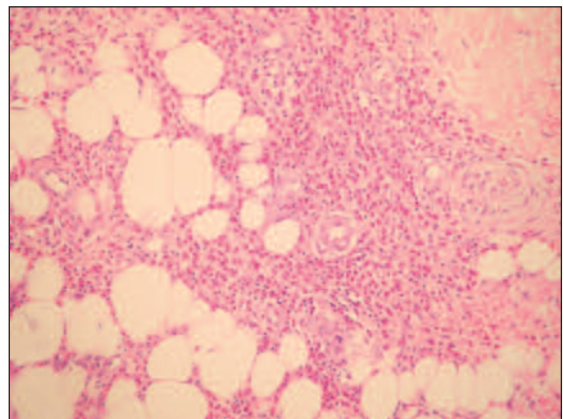


FIGURE 3B: Eosinophilic panniculitis. Lots of eosinophils and macrophages infiltrate the subcutaneous fat and interlobular septa. There is a mixed inflammatory infiltrate of macrophages and numerous eosinophils in the subcutis. Inflammatory cells infiltrate both fat lobules and septa. Eosinophils are cytologically typical appearance (HE x 400).

verage of the defect was postponed. In histopathological examination of the biopsy specimens, endothelial proliferation of all vessels, thrombosis in some vessels and eosinophilic infiltration around the vessels and within the subcutaneous tissue were observed. The eosinophils were cytologically typical in appearance. The specimens were reported as eosinophilic panniculitis (Figure 3A, B).

CBC analysis of peripheral blood was; leukocyte= 16.200/mm³, Hb= 14.7g/dL, platelet= 250.000/mm³, eosinophils= 3700/mm³, PNL= 35.7%, lymphocyte= 15.2%. *Toxoplasma*, Rubella, HBV, HCV, HIV tests were negative, HAV was positive, ASO= 86 TODD, CRP= 84, RF positive, and VDRL was negative. Stool examination for parasitosis did not reveal any positive finding.

The defect was covered with skin graft after developing healthy granulation tissue. The patient died in the post-operative ninth day the reason was not clear and the patient's relatives refused autopsy.

DISCUSSION

The presented case has the majority of the characteristic signs of HES. The main skin manifestations of the disease were pruritic, erythematous purpuric lesions and eschars surrounded by circular erythema, that were placed mainly in lower extremities. There was an eosinophil predominant necrotising vasculitis that effects small dermal vessels. The widespread cutaneous lesions on the lower extremities were possible secondary to dermal vessel involvement.

The HES case that was reported by Barna et al⁵ had antiepileptic drug (carbamazepin and clobasam) taking story of 13 years. A similar drug (diphenylhydantoin) take for epilepsy was also reported in our case. It is well known that anticonvulsive drugs have a potential of hypersensitivity reactions and skin eruptions.⁶ So, we think that

there may be an association between anticonvulsive drug take and HES.

There were fibrinoid changes in the vessel wall in the dermis and subdermis during eosinophilic infiltration in HES.⁷ Endothelial proliferation in all vessels and, thrombosis and surrounding bleeding in some vessels with perivascular intense eosinophilic infiltration were noted in the skin biopsy specimen. The initial peripheral blood eosinophil count was 3700/mm³ in our case, fitting to the criteria for HES of being more than 1500 mm³. It is well known that HES responds very well to systemic steroid treatment.¹ The peripheral blood eosinophil count dramatically decreased and skin lesions regressed after systemic steroid treatment in our case too. Eosinophilia could not be explained through laboratory and clinical examinations. This confirms to the first two criteria for the HES diagnosis. In our opinion, acquired and unexplained epileptic attacks had to be secondary to central nervous system (CNS) involvement of the disease. The skin lesions as well as convulsions that represents the CNS involvement provide the last criteria for the diagnosis of the disease.

The patient died 19 days after hospitalization, during convalescence without any symptoms of mortality. We could not get the opportunity for autopsy to explain the exact reason of death, but we think that the reason might be cardiac arrest or thromboembolic cerebral infarct that are frequently seen secondary to cardiac involvement, which is characterized by endomyocardial fibrosis as the main cause of morbidity and mortality in the HES.¹

In conclusion, HES has a very rare occurrence and may be treated easily. HES can very rarely be identified through skin necrosis, however, we suggest that HES should be taken into consideration in the cases of unexplained skin necrosis so, mortality and morbidity may be decreased.

REFERENCES

1. Weller PF, Buble GJ. The idiopathic hypereosinophilic syndrome. *Blood* 1994;83(10): 2759-79.
2. Baykal Y, Pay F, Sağlam K, Koç B, Odabaşı E, Celasun B, Karaayvaz B, et al. [The idiopathic hypereosinophilic syndrome (case report)]. *Turkiye Klinikleri J Med Sci* 1996;16: 168-71.
3. De Vriese AS, Kips JC, Vogelaers DP, Vandewoude KH, Cuvelier CA, Colardyn FA. Pitfalls in the diagnosis of hypereosinophilic syndrome: a report of two cases. *J Intern Med* 1997;241(2):165-70.
4. Chusid MJ, Dale DC, West BC, Wolff SM. The hypereosinophilic syndrome: analysis of 14 cases with review of the literature. *Medicine (Baltimore)*. 1975;54(1):1-27.
5. Barna M, Kemény L, Dobozy A. Skin lesions as the only manifestation of the hypereosinophilic syndrome. *Br J Dermatol* 1997; 136(4):646-7.
6. Verrotti A, Trotta D, Salladin C, Chiarelli F. Anticonvulsant hypersensitivity syndrome in children. *CNS Drugs* 2002;16(3):197-205.
7. Jang KA, Lim YS, Choi JH, Sung KJ, Moon KC, Koh JK. Hypereosinophilic syndrome presenting as cutaneous necrotizing eosinophilic vasculitis and Raynaud's phenomenon complicated by digital gangrene. *Br J Dermatol* 2000;143(3):641-4.