

# Surgical Excision Can be a Management Option in Riedel Thyroiditis: Case Report with Long Term Follow up

## Cerrahi Eksizyon Riedel Tiroiditi İçin Bir Tedavi Seçeneği Olabilir: Uzun Takip Süreli Olgu Sunumu

Hakan KORKMAZ,<sup>a</sup>  
Meltem TULĞAR,<sup>a</sup>  
Güleser SAYLAM,<sup>b</sup>  
Engin DURSUN,<sup>c</sup>  
Adil ERYILMAZ<sup>d</sup>

<sup>a</sup>Department of Ear, Nose and  
Throat Diseases,  
Yıldırım Beyazıt University  
Faculty of Medicine,

<sup>b</sup>Clinic of Ear, Nose and Throat Diseases,  
Ankara Dışkapı Yıldırım Beyazıt Training  
and Research Hospital,  
Ankara

<sup>c</sup>Department of Ear, Nose and  
Throat Diseases,  
Recep Tayyip Erdoğan University  
Faculty of Medicine,  
Rize

<sup>d</sup>Clinic of Ear, Nose and Throat Diseases,  
Ankara Numune Training and  
Research Hospital,  
Ankara

Geliş Tarihi/Received: 22.04.2016  
Kabul Tarihi/Accepted: 14.11.2016

Yazışma Adresi/Correspondence:  
Meltem TULĞAR  
Yıldırım Beyazıt University  
Faculty of Medicine,  
Department of Ear, Nose and  
Throat Diseases, Ankara,  
TÜRKİYE/TURKEY  
tulgarmeltem@gmail.com

doi: 10.5336/caserep.2016-51834

Copyright © 2016 by Türkiye Klinikleri

**ABSTRACT** Riedel's thyroiditis is a rare chronic inflammatory disease of unknown etiology characterized by a dense fibrosis that replaces normal thyroid parenchyma and often involves surrounding tissues. Riedel's thyroiditis presentation is complex, including a thyroid mass associated with local symptoms, characteristic biochemical abnormalities as well as the involvement of a wide range of other organ systems. It is important to distinguish Riedel's thyroiditis from thyroid carcinoma. Because it mimics the carcinoma, diagnosis of Riedel's thyroiditis requires histopathological confirmation. A case of Riedel's thyroiditis; who presented with a firm thyroid mass, symptoms of esophageal and tracheal compression; was reported in this article. Surgery was performed to obtain a definitive diagnosis and safe airway and it was successful to arrest the enlargement. After long follow up the patient has no recurrences and any complications.

**Key Words:** Thyroid gland; thyroiditis; surgery

**ÖZET** Riedel tiroiditi, nadir görülen, etyolojisi bilinmeyen, normal tiroid parankimi ve çevresindeki dokuların yoğun fibrozisi ile seyreden kronik inflamatuvar bir hastalıktır. Riedel tiroiditinin kliniği; lokal semptomlara yol açan tiroid kitlesi, karakteristik biyokimyasal anormallikler, ve diğer organlarda olabilecek tutulumlarla kompleks olabilir. Riedel tiroiditinin tiroid karsinomundan ayırımının yapılması önemlidir. Tiroid karsinomunu taklit ettiği için kesin tanı histopatolojik değerlendirme ile desteklenmelidir. Bu yazımızda tiroide sert kitlesi olan ve özofageal ve trakeal baskı semptomları ile başvuran Riedel tiroiditi olgu sunulmuştur. Olguya cerrahi işlem uygulanarak kesin tanı konulmasının yanında yeterli ve güvenli bir havayolu sağlanarak kitlenin büyümesi durduruldu. Uzun dönem takibi olan hastada rekürrens ve herhangi başka bir sıkıntı görülmedi.

**Anahtar Kelimeler:** Tiroid bezi; tiroidit; cerrahi

**Türkiye Klinikleri J Case Rep 2016;24(4):365-8**

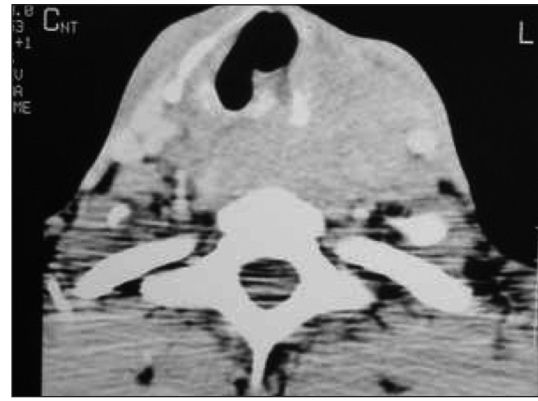
**R**iedel's thyroiditis (RT) is a rare form of chronic thyroiditis, characterized by a dense fibroinflammatory process. The etiology is unknown, but one theory postulates that RT results from an autoimmune process. A second theory holds RT to be a primary fibrotic disorder. Some experts consider that RT is not primarily a thyroid disease but rather it is a manifestation of a systemic disorder of multifocal fibrosclerosis. The fibrotic process invades adjacent structures of the neck and extends beyond the thyroid capsule, and forms the stone-hard consistency. This feature differentiates RT from other inflammatory or fibrotic disorders of the thyroid. Sometimes patients may present with extracervical manifestations of multifocal fibrosclerosis (e.g. retroperitoneal fibrosis, mediastinal

fibrosis, sclerosing cholangitis). RT is most often seen in women and the clinical features closely resemble those of anaplastic carcinoma of the thyroid. Patients note a painless, rapidly growing stony thyroid mass. Direct extension causes compression of the trachea and the oesophagus, resulting in dyspnoea and dysphagia. Hypothyroidism is present in 30% of cases. The natural history of Riedel's thyroiditis is most likely self-limiting; however, treatment can include steroids, as well as surgical excision of all or part of the gland to alleviate compressive symptoms.

## CASE REPORT

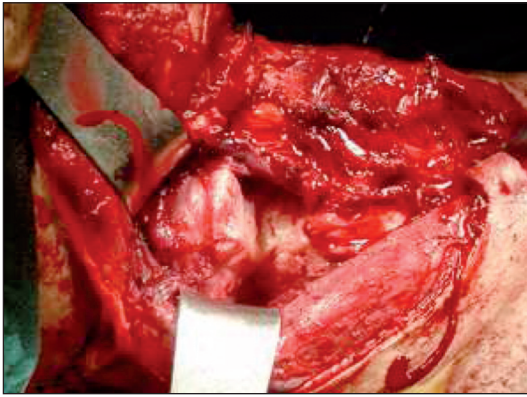
Thirty years old male patient applied with the complaint of progressive neck mass of 4 years duration. He had an history of thyroidectomy in another center 3 years ago which ended up as a partial surgery due to the dense fibrotic structure of the thyroid. The histopathological examination was consistent with RT. After the operation the neck mass enlarged in size with progressive signs of respiratory difficulty, dysphagia. During this course he had intermittent oral steroid treatments, which yielded almost no response. When he applied to us he had a large midline neck mass (15x20 cm), which was fixed and was very firm. Telescopic examination revealed a retropharyngeal submucosal mass and the larynx was pushed forward significantly, which was compromising both the airway and esophageal inlet. The neck CT revealed a 15x15 cm retroesophageal solid neck mass with well defined borders which was extending from the level of oropharynx to the level of thoracic inlet (Figure 1). The mass was also involving the paratracheal thyroid bed in the lower neck. His thyroid function was normal. Fine needle cytology was non-diagnostic, and no sign of malignancy. The patient had significant weight loss and his body mass index was 17.2.

We planned a surgical excision to improve the respiration and swallowing. Under general anesthesia the neck was explored through an apron incision. The mass was almost totally retroesophageal, and there was also similar mass in the thyroid bed. The common carotid arteries and in-

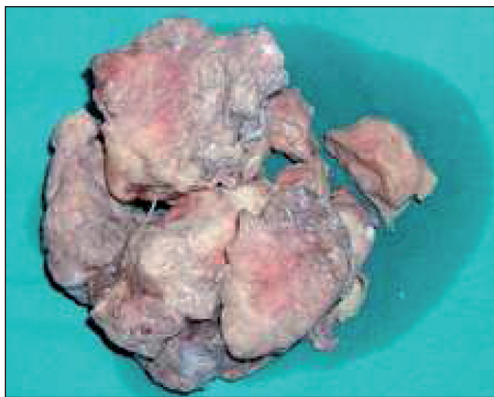

**FIGURE 1:** Neck CT sections of the patient demonstrates 15x15 cm retroesophageal solid neck mass with well defined borders which was extending from the level of oropharynx to the level of thoracic inlet.

ternal jugular veins were dissected bilaterally and was separated from the mass. Prevertebral muscles were reached and dissection plan was formed in between the mass and fascia. The mass was very adherent to the posterior wall of esophagus. The mass was grayish to white coloured and firm in consistency, mainly located between the two common carotid arteries and behind esophagus (Figure 2). During the dissection the esophagus was entered and then it was repaired by 3/0 absorbable suture. On the left site recurrent laryngeal nerve was explored and preserved while dissecting the mass off the nerve. On the right site the nerve was explored but some of the mass was left along the nerve tractus. Then the mass was resected from the oropharynx level to the level of thoracic inlet where some of the mass was left in order to avoid any complication. Almost 90% of the mass was resected (Figure 3), and tracheotomy was performed and nasogastric feeding tube was inserted. The postoperative period was uneventful but the patient had significant aspiration of fluids. Therefore, the patient was discharged on the 7<sup>th</sup> day with tracheotomy and feeding tube. He started swallowing solid foods within 3 months, and was decannulated 6 months later. He had paralysis of left vocal cord but the right was mobile, so he had sufficient airway and some hoarseness. At the 6<sup>th</sup> month the patient underwent laparotomy for gastrostomy. He swallowed the solid foods orally while the liquids by the gastrostomy. At the fifth year the gastrostomy was pulled out and he was having his whole



**FIGURE 2:** The mass was grayish to white coloured and firm in consistency, mainly located between the two common carotid arteries and behind esophagus.



**FIGURE 3:** Almost 90% of the mass was resected.

diet orally. He gained weight and his BMI was 22, he was happy with his respiration and voice. He had no significant neck mass. However, some mass was still persisting at the thoracic inlet, which was asymptomatic at all.

## DISCUSSION

Riedel's thyroiditis is a rare form of thyroiditis. Patients with RT usually present with a sudden inflammation of the thyroid gland, dyspnea or dysphagia due to compression of trachea or esophagus by a firm and fixed mass in the anterior neck. Although local compression symptoms are common, RT unusually can present asymptomatic, and can be in association with follicular adenoma, as reported by Ozgur et al. Fibrosis characteristically invades and encloses the adjacent structures in the neck extending beyond the limits of thyroid cap-

sule. Its major clinical significance lies in its ability to mimic sclerosing variant of papillary carcinoma, fibrous Hashimoto's thyroiditis and undifferentiated thyroid carcinoma.

However, it is almost impossible to make an absolute diagnosis clinically; therefore surgical biopsy and/or excision is commonly used. Fine needle cytology of our case was non-diagnostic, as there were only fibrotic cells but no sign of malignancy. The disease is bilateral in most cases, and the function of the thyroid can be normal (65%) or decreased (30%) but thyrotoxicosis is rare. In our case thyroid function was normal. A CT scan would be very helpful to demonstrate the extension and borders of the mass. Our patient's neck CT revealed a 15x15 cm retroesophageal solid neck mass with well defined borders which was extending from the level of oropharynx to the level of thoracic inlet.

Riedel's thyroiditis is generally a self-limited disease, death to airway compromise is very rare. In the patients with multifocal fibrosclerosis, prognosis essentially becomes that of extracervical fibrosclerosis. Therefore when RT is diagnosed, it is essential to perform abdominal and chest imaging studies to exclude concomitant, extracervical entities from multifocal fibrosclerosis. Our patients abdominal CT revealed retroperitoneal fibrosis, which was asymptomatic.

The rarity of Riedel's thyroiditis makes controlled studies of RT therapy impractical. Currently corticosteroid therapy is the medical treatment of choice for patients with RT. All studies advocate an initially high dose to alleviate compressive symptoms, followed by gradual tapering over months to a lower maintenance dose. Many patients can be weaned from corticosteroid therapy but others require more prolonged treatment. During the course of the disease our patient also had intermittent oral steroid treatments, which yielded almost no response. Tamoxifen has been used in some RT patients as a first-line therapy, but it has also been applied after the failure of corticosteroid treatment. Although some reports have described some success with tamoxifen, estrogen receptors

have not been demonstrated in RT tissues. Therefore the mechanism of action was not proposed to be due the antiestrogenic activity of tamoxifens.

Surgery for patients with RT serves the dual purpose of establishing the diagnosis and relieving tracheal compression. A wedge resection of thyroid isthmus remains the preferred method for accomplishing these ends. Surgery is indicated when tissue is needed for diagnosis, medical treatment shows no benefit, or compressive symptoms are very severe. Open surgical biopsy is essential for the definitive establishment of the diagnosis of RT and for the exclusion of carcinoma. A wedge resection of the isthmus relieves tracheal compression. More extensive thyroid surgery is generally discouraged because extrathyroid fibrosclerosis alters the anatomy and obliterates surgical planes. Our case had an history of thyroidectomy in another center 3 years ago which ended up as a partial surgery due to the dense fibrotic structure of

the thyroid. The histopathological examination was consistent with Riedel's thyroiditis. Although the surgery has an increased risk for iatrogenic surgical damage to the trachea, esophagus, carotids, recurrent laryngeal nerves or parathyroid glands we planned a surgical excision, because compressive symptoms were severe and there was no response to corticosteroid therapy. After the surgery, the patient showed a favorable outcome. The surgery was successful to get a sufficient airway and swallowing so that his BMI was improved. Except unilateral vocal cord paralysis there was no further complication, and in spite of the paralysis he has an acceptable voice. In his five year follow-up no progression of the remnant mass was observed, however, some mass was still persisting at the thoracic inlet, which was asymptomatic at all. We consider that surgical excision can be applied in Riedel's thyroiditis if the local symptoms are severe, in order to improve the quality of life.

## REFERENCES

- Schwaegerle SM, Bauer TW, Esseltyn CB Jr. Riedel's thyroiditis. *Am J Clin Pathol* 1988; 90(6):715-22.
- Lorenz K, Gimm O, Holzhausen HJ, Kittel S, Ukkat J, Thanh PN, et al. Riedel's thyroiditis: impact and strategy of a challenging surgery. *Langenbecks Arch Surg* 2007;392(4):405-12.
- Oguz KK, Kiratlı H, Oguz O, Cila A, Oto A, Gokoz A. Multifocal fibrosclerosis: a new case report and review of the literature. *Eur Radiol* 2002;12(5):1134-8.
- Stone JH, Zen Y, Deshpande V. IgG4-related disease. *N Engl J Med* 2012;366:539-51.
- Cho MH, Kim CS, Park JS, Kang ES, Ahn CW, Cha BS, et al. Riedel's thyroiditis in a patient with recurrent subacute thyroiditis: a case report and review of the literature. *Endocr J* 2007;54(4):559-62.
- Ozgur T, Gokce H, Ustun I, Yaldiz M, Akin MM, Gokce C. A case of asymptomatic riedel thyroiditis with follicular adenoma in a patient with a multinodular goiter: an unusual association. *Eur Thyroid J* 2012;1(3): 204-7.
- Shahi N, Abdelhamid MF, Jindall M, Awad RW. Riedel's thyroiditis masquerading as anaplastic thyroid carcinoma: a case report. *J Med Case Rep* 2010;4:15.
- Vaidya B, Harris PE, Barrett P, Kendall-Taylor P. Corticosteroid therapy in Riedel's thyroiditis. *Postgrad Med J* 1997;73(866):817-9.
- De M, Jaap A, Dempster J. Tamoxifen therapy in steroid resistant Riedel's thyroiditis. *Scott Med J* 2001;46(2):56-7.
- Lorenz K, Gimm O, Holzhausen HJ, Kittel S, Ukkat J, Thanh PN, et al. Riedel's thyroiditis: impact and strategy of a challenging surgery. *Langenbecks Arch Surg* 2007;392(4):405-12.