

Stenting of Superior Mesenteric Artery Stenosis: Case Report

Superior Mezenterik Artere Başarılı Stent Yerleştirilmesi

Ramazan AKDEMİR, MD,^a
Cemil BİLİR, MD,^b
Şemsi Mustafa AKSOY, MD,^c
Özlem KARAKURT, MD^a

Departments of
^aCardiology,
^cAnesthesiology,
Dışkapı Yıldırım Beyazıt Training and
Research Hospital, Ankara
^bDepartment of Internal Medicine,
Düzce University,
Düzce Faculty of Medicine, Düzce

Geliş Tarihi/Received: 04.11.2008
Kabul Tarihi/Accepted: 14.01.2009

*This case report was presented as a
oral presentation in EuroPCR2007
(22-25 May 2007, Barcelona, Spain).
(www.europcronline.com)*

Yazışma Adresi/Correspondence:
Ramazan AKDEMİR, MD
Dışkapı Yıldırım Beyazıt Research and
Education Hospital,
Department of Cardiology, Ankara
TÜRKİYE/TURKEY
rakdemir@yahoo.com

ABSTRACT Acute mesenteric ischemia has a high morbidity and mortality rate. Early diagnosis and appropriate treatment are the most important factors. A 70-year-old woman with history of hypertension has admitted to our hospital because of abdominal angina. Electrocardiography (ECG) showed normal findings. Transthoracic and transesophageal echocardiography was normal. Coronary arteries were normal on coronary angiography. A critical superior mesenteric artery (SMA) stenosis has been demonstrated successfully by mesenteric angiography. For this stenosis, 3.0 x 15 mm coronary stent was implanted after predilatation. Abdominal pain dissolved, after meals and the patient was discharged in a good healthy conditions. The patient was asymptomatic in 6 months' control. In this paper, the catheter based treatment of atherosclerotic SMA stenosis was discussed.

Key Words: Mesenteric vascular occlusion; angiography; mesenteric artery, superior

ÖZET Akut mezenter iskemisinin yüksek ölüm ve sakatlık oranı vardır. Erken tanı ve uygun tedavi en önemli faktörlerdir. Yetmiş yaşında hipertansiyon öyküsü olan bir kadın hasta, karın ağrısıyla hastanemize başvurdu. Elektrokardiyografi (EKG)'de anormal bir bulgu yoktu. Transözofageal ve transtorasik ekokardiyografi ile koroner arterler koroner anjiyografide normaldi. Süperior mezenterik arterde (SMA) mesenterik anjiyografide ciddi bir darlık saptandı. Bu lezyona 3.0 x 15 mm koroner stent ön dilatasyon sonrası başarılı bir şekilde yerleştirildi. Yemeklerden sonra gelen karın ağrısı kayboldu ve hasta sağlıklı bir şekilde taburcu edildi. Hastan 6 ay sonraki kontrolünde asemptomatik idi. Bu yazıda, aterosklerotik SMA darlığının katetere dayalı tedavisi tartışıldı.

Anahtar Kelimeler: Mezenterik damarsal tıkanma; anjiyografi; süperior mezenterik arter

Türkiye Klinikleri J Cardiovasc Sci 2009;21(1):114-7

Mesenteric arterial ischemia is an uncommon condition associated with a high morbidity and mortality. Acute ischemia has a reported mortality rate of 70-90%. and the chronic form will eventually lead to death from intestinal infarction or starvation if left untreated.¹⁻⁷ Such patients are often older age and have many coexisting disease, which makes them a group at high-risk of open surgery. Surgical revascularization and resection of the necrotic bowel has until recently been the main treatment of both acute and chronic mesenteric ischemia (CMI). Surgery is still the method of choice in the acute setting, especially if signs indicating bowel infarction are present; also some new therapeutic options are being

tried.¹⁻⁶ In chronic cases, however, percutaneous transluminal angioplasty (PTA) of stenotic mesenteric arteries has become an option.⁷⁻⁹ This paper presents a case of superior mesenteric artery with severe stenosis, which was treated successfully with stent implantation

CASE REPORT

A 70-year-old woman with history of chronic pulmonary disease and hypertension was admitted to our hospital because of abdominal pain. She has been suffering from intermittent constipation and chest pain for three hours. In her medical history she was describing severe weight loss and abdominal pain, nausea and cold sweating for 6 months. On clinical examination, his blood pressure was 180/100 mmHg and her temperature 37.3°C. Cardiac examination was normal, peripheral pulses were normal and there was nor murmur on abdominal auscultation. There was generalized non-specific abdominal pain on examination. Chest and abdominal radiography, ultrasound investigations were within normal limits. ECG showed non-specific ST-T changes in anterior leads. Echocardiography showed findings describe chronic cor-pulmonale. All the blood tests were within normal limits, except white blood cell count was 13.000/L. The patient was evaluated before for acute abdomen by general surgery. There was not any specific diagnosis, but surgical exploration operation was planned by surgical team. We have suspected coronary artery disease and decided coronary angiography before the non-cardiac surgery upon cardiological. Coronary arteries were normal, non-selective and selective abdominal aortography was also performed. After this finding, we re-checked the patient's history, symptoms and increased white blood cell counts. The patient had been suufering from typical abdominal angina described as increases when eating foods. So, performing of mesenteric angiography was decided. Celiac artery and brunches, renal arteries were normal. Inferior mesenteric artery was normal. But, there was sub-total occlusive lesion located in the mid portion of SMA (Figure 1). After the completion of surgical and gastroenterological consul-

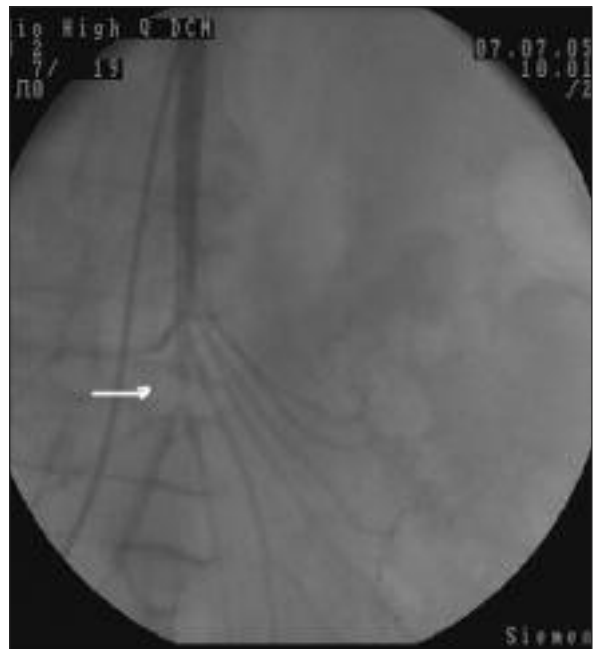


FIGURE 1: Superior mesenteric artery arteriography before the treatment. The arrow shows the severe stenosis.

tations, angioplasty and stenting was chosen. Patient consent was also taken. Medications included 100 IU/kg body weight of intra arterial heparin and oral clopidogrel 600 mg were given. Lesion was crossed by 0.014" guide wire and dilated 3.0 x 20 mm balloon by 18 mmHg atmosphere pressure. After balloon dilatation recoil occurred and stenting was performed with balloon-expandable 3.0 x 15 mm coronary stent (Ephesos stent, Nemed corp., Istanbul, Turkey) by 18 atmosphere pressure. Control angiography showed excellent distal flow without any side branch occlusion (Figure 2). After procedure, the patient was free of abdominal pain after meals and generally in a well condition. Homocysteine, protein C and protein S levels of the patient were in normal limits and antiphospholipid antibody was negative. Transesophageal echocardiography was normal for exclusion of the thrombotic origin. The patient was discharged at 5th day of admission, by the treatment of aspirin (325 mg/day), clopidogrel (75 mg/day), and diltiazem 120 mg oral for one month. After 6 years, she is asymptomatic and being followed by aspirin (325 mg/day).

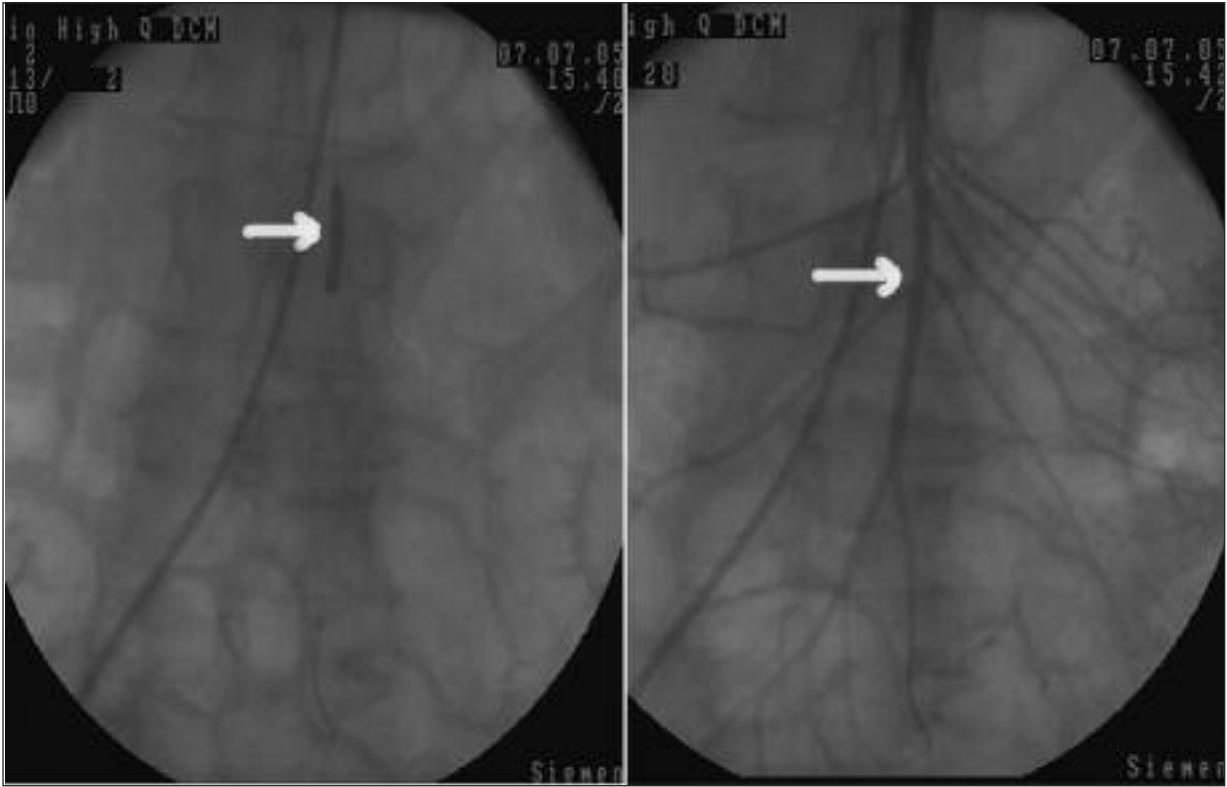


FIGURE 2A, B: Superior mesenteric artery arteriography after the stent implantation. The arrow shows the location of the stenosis.

DISCUSSION

This case describes a successfully treated abdominal angina caused by a SMA stenosis. The technique for this procedure was same as coronary angioplasty cases and it was also successful. We have chosen Judkins right guiding catheter and successfully cannulated the SMA in anterior-posterior projections and made deep intubation in lateal projection. An other important issue is the usage of 0.14 inch guidewire because it is extremely difficult situation to use 0.35 inch guide wire because of vertical angle between the aorta and SMA. Quantitative angiography results have led us to use a coronary balloon expandable stent, but in general SMA has larger luminal diameter than present case.

In this case, the lesion was located in the proximal part 5-6 cm just distal to the origin and there was not any angiographically visible thrombus. When we looked the patient's medical history we have assumed that she has suffering from chronic mesenteric ischemia for 6 months. But, by the time,

stenosis has progressed and become subtotal occlusion. The other issue is the location of stenosis in the SMA. Contrary to the knowledge, stenosis was very unusual location. Because almost all reported SMA lesions were located proximal or ostial parts of the artery. This was an extraordinary situation because etiology of this stenosis may be other than atherosclerosis. But, angiographic images were similar to atherosclerotic stenosis. We were unable to make intravascular ultrasound evaluation.

Acute abdominal ischaemia is usually caused by an embolus mostly from the left atrium, non-occlusive arterial disease and mesenteric venous embolism.³⁻⁵ CMI depends of the atherosclerotic disease of the mesenteric arteries.

Although atherosclerotic lesions of the mesenteric vessels are common in elderly patients, the clinical syndrome of CMI is uncommon. A recent population-based study using duplex ultrasound imaging found 17.5% of persons 65 years old had a critical stenosis of at least one mesenteric vessel. The exact incidence of CMI is unknown,

but is estimated at only a few cases per 100,000 population. CMI is a debilitating disease leading to significant weight loss and inanition. Left unrecognized or untreated, CMI may progress to intestinal infarction and death. Unfortunately, the first symptom related to atherosclerotic mesenteric occlusive disease in many patients is acute intestinal infarction. Open surgical repair (OR) has been the gold standard treatment for CMI. Because the incidence of CMI is quite low, few surgeons and institutions have extensive experience in its management. Currently, there is no consensus on the optimal means of revascularization (open vs endovascular), by-pass route (antegrade vs retrograde), conduit (prosthetic vs vein), number of vessels revascularized, or even the management of asymptomatic three-vessel mesenteric occlusive disease.⁷⁻⁹

The Cleveland Clinic group also reported their series of 28 patients (32 vessels) treated by

PTA/Stent and compared the group with a historical series of 85 OR cases. They concluded that the results of PTA/Stent and OR were similar with respect to morbidity, mortality, and recurrent stenosis. They found that the PTA/Stent group had a significantly higher incidence of recurrent symptoms and recommended that OR should be preferentially offered to patients fit for open mesenteric reconstruction. Recurrent symptoms developed in 11 (39%) of 28 PTA/Stent patients during the study interval.⁹

As conclusion, this case is an example of endovascular therapy of CMI. When we summarize the current knowledge; PTA/Stent was associated with decreased primary patency rates, initial hospital stay is shorter when compared with OR. Mortality and major morbidity in patients undergoing PTA/Stent was similar compared with OR. Patient's preference and anatomical issues must take into account in decision making.

REFERENCES

1. Tüzüner A, Bengisun U. [Mesenteric vascular diseases]. *Turkiye Klinikleri J Surg Med Sci* 2003;8(1):54-66.
2. Nyman U, Ivancev K, Lindh M, Uher P. Endovascular treatment of chronic mesenteric ischemia: report of five cases. *Cardiovasc Intervent Radiol* 1998;21(4):305-13.
3. Mellander S, Hellberg R, Karlqvist PA, Svahn M. Local fibrinolysis in acute thromboembolism of the superior mesenteric artery. *Eur J Surg* 2001;167(4):308-11.
4. Batellier J, Kieny R. Superior mesenteric artery embolism: eighty-two cases. *Ann Vasc Surg* 1990;4(2):112-6.
5. Turégano Fuentes F, Simó Muerza G, Echezagusia Belda A, Fiuza Marco C, Palacios JT, Pérez Díaz D. Successful intraarterial fragmentation and urokinase therapy in superior mesenteric artery embolisms. *Surgery* 1995; 117(6):712-4.
6. Kurtoğlu M, Yanar H. [Acute mesenteric ischemia]. *Turkiye Klinikleri J Surg Med Sci* 2005;1(4):17-23.
7. Marín Manzano E, Haurie Girelli J, González de Olano D, Sánchez Del Corral J, Redondo López S, Núñez de Arenas Baeza G, et al. [Endovascular therapy as an alternative treatment in chronic mesenteric ischemia]. *Gastroenterol Hepatol* 2007;30(6): 340-2.
8. Kasirajan K, O'Hara PJ, Gray BH, Hertzner NR, Clair DG, Greenberg RK, et al. Chronic mesenteric ischemia: open surgery versus percutaneous angioplasty and stenting. *J Vasc Surg* 2001;33(1):63-71.
9. Atkins MD, Kwolek CJ, LaMuraglia GM, Brewster DC, Chung TK, Cambria RP. Surgical revascularization versus endovascular therapy for chronic mesenteric ischemia: a comparative experience. *J Vasc Surg* 2007;45(6): 1162-71.