

## Acetabular Metastasis as Initial Presentation of Endometrial Cancer

Ghanim KHATIB,<sup>a</sup>  
 Ercan CÖMERT,<sup>a</sup>  
 Ümran KÜÇÜKGÖZ GÜLEÇ,<sup>a</sup>  
 Ahmet Barış GÜZEL,<sup>a</sup>  
 Mehmet Ali VARDAR,<sup>a</sup>  
 Emine BAĞIR,<sup>b</sup>  
 Semra PAYDAŞ<sup>b</sup>

Departments of  
<sup>a</sup>Obstetrics and Gynecology,  
<sup>b</sup>Pathology,  
 Çukurova University Faculty of Medicine,  
 Adana

Received: 11.05.2016  
 Received in revised form: 11.07.2016  
 Accepted: 14.07.2016  
 Available online: 15.02.2018

Correspondence:  
 Ghanim KHATIB  
 Çukurova University Faculty of Medicine,  
 Department of Obstetrics and Gynecology,  
 Adana, TURKEY  
 ghanim.khatib@gmail.com

**ABSTRACT** Acetabulum is uncommon extraordinary place for endometrial cancer metastasis. Here we report a case of primary bone metastasis as initial presentation of the endometrial cancer. A 67 years old nulliparous Turkish woman admitted to the hospital with right hip pain. Magnetic resonance imaging was realized and a mass in size of 40x66 mm was reported in the posterior of the right acetabulum. Biopsy of the mass was taken and the result was recorded as metastatic adenocarcinoma. PET CT revealed that a mass of approximately 78x63 mm on the right acetabulum and a heterogeneous increase of F-18 FDG uptake (SUVmax: 11.8) was noticed. Further, irregular enlarged endometrial cavity and increased F-18 FDG involvement (SUVmax:13,4) were observed. Endometrial biopsy was applied and the result was reported as endometrial adenocarcinoma FIGO grade 2. In conclusion, endometrial biopsy should be included in the women patient's screening when investigated for metastatic bone adenocarcinoma.

**Keywords:** Endometrial neoplasms; acetabulum; biopsy; neoplasm metastasis

Endometrial cancer (EC) is the most common gynecological cancer, especially in the Western countries. Vaginal bleeding is the major symptom in 90% of the patients. About 75% of the cases are confined to the uterus (FIGO stage I).<sup>1-3</sup> Bone metastases are encountered in 5-6% of the cases and generally with abdominopelvic recurrences and/or other distant metastases. However, bone metastases as initial symptom for the EC are an extremely rare condition.<sup>2</sup> Although hematologic dissemination is the probable pathway for bone metastasis, the mechanism of initial presentation as bone metastasis in the EC is not clearly understood.<sup>1</sup> Here we report a case of acetabular metastasis as primary presentation of the EC after an informed consent was obtained from the patient.

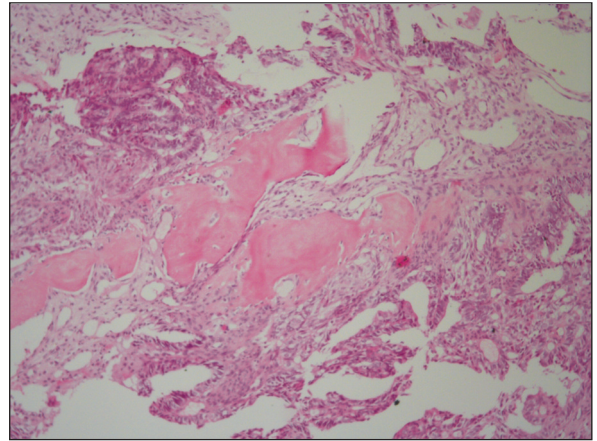
### CASE REPORT

A 67 years old nulliparous Turkish woman admitted to the hospital with right hip pain. Left salpingo-oophorectomy was performed in the past because of benign ovarian cyst. No systemic disease other than hypertension and no significant familial history was noted. Magnetic resonance imaging was realized and a mass in size of 40x66 mm was reported in the posterior of the right acetabulum. Biopsy of the mass was taken and the result was recorded as metastatic adenocarcinoma (Figure 1). In order to determine the primary focus PET CT was carried out. PET CT revealed that a mass of approximately 78x63 mm causing significant destruction of bone on the

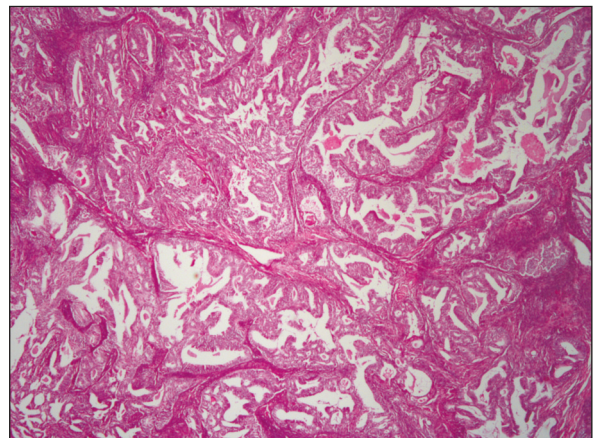
right acetabulum and a heterogeneous increase of F-18 FDG uptake (SUVmax: 11.8) was noticed. Further, irregular enlarged endometrial cavity and increased F-18 FDG involvement (SUVmax:13,4) were observed. Hence, gynecological consultation was requested. Endometrial biopsy was applied and the result was reported as endometrial adenocarcinoma FIGO grade 2 (Figure 2). Therefore, total abdominal hysterectomy+ right salpingo-oophorectomy + left salpingectomy + bilateral pelvic para-aortic lymphadenectomy was administered to the patient. Site-directed radiotherapy was performed to the involved bone region. Gross pathological examination's result was noted as; endometrial adenocarcinoma FIGO grade 2 with involved lymphovascular space and cervical stroma. Two right and one left pelvic lymph nodes were positive. Adjuvant radiotherapy and chemotherapy with zoledronic acid were planned to the patient by a decision of the gynecologic oncology council.

## DISCUSSION

As all gynecological cancers, bone metastases from EC are rare. EC is known to spread commonly by direct extension to the adjacent tissues or lymphatic dissemination. Hematogenous metastasis in EC is less frequent and usually seen in the lung and liver. Brain and bone metastases are less common.<sup>4</sup> While, bone involvement is reported to be less than 15% in EC patients with metastatic disease, it is estimated to be about 5-6% in all EC patients and generally in cases with recurrences and/or other distant metastases.<sup>2,4</sup> On the other hand, autopsy based studies suggest an incidence up to 25% for bone metastases originated from EC.<sup>5,6</sup> However, bone metastases as initial symptom are an extremely rare entity for the EC.<sup>2,6</sup> The incidence of stage IV endometrial cancer is mentioned as 5-10% with less than 10% of 5-years survival rate.<sup>6</sup> Bone metastases are associated with poor prognosis. Nevertheless, prognosis of the isolated metastasis is favorable compared with the multiple ones.<sup>1</sup> Kehoe et al. described 21 EC patients with bone metastasis in their retrospective study.<sup>7</sup> Whereas, 6 patients (29%) presented with a synchronous bone metas-



**FIGURE 1:** Tumor islands consisting of atypical epithelial cells between bone fragments are monitored in samples taken from a mass in the right acetabular region (H&Ex40).



**FIGURE 2:** FIGO grade 2 endometrioid adenocarcinoma Consisting of atypical glandular cells (H&Ex 100).

tasis, 15 patients (71%) had a bone recurrence and the overall survival of these patients was 17 and 32 months, respectively.<sup>7</sup> Myriokefalitaki et al. suggested that EC patients with single bone metastasis should be evaluated as different entity from those with multiple site metastases.<sup>6</sup> They found that the mean survival for patients with single site bone metastasis was 85.7 months which was significantly better than the estimated mean survival of patients with multiple metastases, which was 22.9 months.<sup>6</sup> Single site bone metastasis (acetabulum) was detected in the current study, which was the initial presentation of the case. In the latter study, a review of the literature was made and 29 cases of EC presenting with bone metastases were assessed. Patients' mean age was 61.3 years. Bone

pain, swelling, discomfort and/or pathological fracture without post-menopausal bleeding were the initial symptoms of these cases. Our patient was 67 years old and her admission complaint was bone pain.

The rarity of the EC with bone metastases and therefore limited number of studies with small cases in the medical literature had precluded finding out the standard treatment for these patients.<sup>1,8,9</sup> Current treatment modalities include primary cytoreductive surgery, radiotherapy, chemotherapy, hormonal therapy or combinations of these treatment options. Bone metastases can be treated by surgical resection especially the isolated ones. Stereotaxic or palliative radiotherapy, radiofrequency with cementoplasty, and systemic chemotherapy or hormone therapy are the other options. Sites and number of metastatic bones, concomitant extra-osseous metastasis, type of previous treatments and patients' performance status are the important criteria which affect the selection of the management.<sup>1</sup> Our case was treated with a combination of directed radiotherapy for the involved acetabulum, primary surgery, chemotherapy and hormonal therapy.

In conclusion endometrial biopsy should be included in the women patient's screening

when investigated for metastatic bone adenocarcinoma.

### Source of Finance

*During this study, no financial or spiritual support was received neither from any pharmaceutical company that has a direct connection with the research subject, nor from a company that provides or produces medical instruments and materials which may negatively affect the evaluation process of this study.*

### Conflict of Interest

*No conflicts of interest between the authors and / or family members of the scientific and medical committee members or members of the potential conflicts of interest, counseling, expertise, working conditions, share holding and similar situations in any firm.*

### Authorship Contributions

**Idea/Concept:** Semra Paydaş, Mehmet Ali Vardar, Ghanim Khatib; **Design:** Ghanim Khatib, Ercan Cömert; **Control/Supervision:** Mehmet Ali Vardar, Semra Paydaş; **Data Collection and/or Processing:** Emine Bağır, Ercan Cömert; **Analysis and/or Interpretation:** Ahmet Barış Güzel, Ümran Küçükgöz Güleç, Ghanim Khatib; **Literature Review:** Ghanim Khatib, Ahmet Barış Güzel, Ümran Küçükgöz Güleç; **Writing the Article:** Ghanim Khatib; **Critical Review:** Mehmet Ali Vardar, Ghanim Khatib; **References and Findings:** Ghanim Khatib; **Materials:** Ahmet Barış Güzel, Ercan Cömert, Ümran Küçükgöz Güleç, Emine Bağır.

## REFERENCES

1. Yoon A, Choi CH, Kim TH, Choi JK, Park JY, Lee YY, et al. Bone metastasis in primary endometrial carcinoma: features, outcomes, and predictors. *Int J Gynecol Cancer* 2014;24(1): 107-12.
2. Uharcek P, Mlyncek M, Ravinger J. Endometrial adenocarcinoma presenting with an osseous metastasis. *Gynecol Obstet Invest* 2006;61(4):200-2.
3. Güçer F, Okçu M, Arıkan MG, Lahousen M. [Bone metastase in endometrial carcinoma]. *Turkiye Klinikleri J Gynecol Obst* 1997;7(1): 48-50.
4. Dursun P, Gültekin M, Yüce K, Ayhan A.
5. Abdul-Karim FW, Kida M, Wentz WB, Carter JR, Sorensen K, Macfee M, et al. Bone metastasis from gynecologic carcinomas: a clinicopathologic study. *Gynecol Oncol* 1990;39(2):108-14.
6. Myriokefalitaki E, D'Costa D, Smith M, Ahmed AS. Primary bone metastasis as initial presentation of endometrial cancer (stage IVb). *Arch Gynecol Obstet* 2013;288(4):739-46.
7. Kehoe SM, Zivanovic O, Ferguson SE, Barakat RR, Soslow RA. Clinicopathologic features of bone metastases and outcomes in patients with primary endometrial cancer. *Gynecol Oncol* 2010;117(2):229-33.
8. Longo R, Gamelon-Benichou C, Elias-Matta C, Platini C, Eid N, Yacoubi M, et al. An unusual solitary metatarsal metastasis from an endometrioid endometrial adenocarcinoma. *Am J Case Rep* 2015;16:473-7.
9. Nguyen ML, Lafargue CJ, Pua TL, Tedjarati SS. Grade 1 endometrioid endometrial carcinoma presenting with pelvic bone metastasis: a case report and review of the literature. *Case Rep Obstet Gynecol* 2013;2013:807205.