



## An Advanced Achilles Tendon Rupture During Multidrug Use

 Tuba ERDEM SULTANOĞLU,<sup>a</sup>  
 Hasan SULTANOĞLU<sup>b</sup>

<sup>a</sup>Clinic of Physical Therapy and Rehabilitation,  
Gaziantep Şehitkamil State Hospital,

<sup>b</sup>Clinic of Emergency Medicine,  
Gaziantep Dr. Ersin Arslan Training and Research Hospital,  
Gaziantep

Received: 09.11.2017

Received in revised form: 02.01.2018

Accepted: 03.01.2018

Available online: 17.09.2018

### Correspondence:

Tuba ERDEM SULTANOĞLU  
Gaziantep Şehitkamil State Hospital,  
Clinic of Physical Therapy and Rehabilitation,  
Gaziantep, TURKEY  
drtubaerdem@gmail.com

This study was presented as a poster at  
PM&R Course Days, 28 April-1 May 2016,  
Izmir, Turkey.

**ABSTRACT** Achilles tendon is the strongest and largest tendon in the body. Since its vascularity toward the 2-6 cm proximal to its insertion on the calcaneus is poor, this area is vulnerable to degeneration and injury. In patients with advanced age and comorbid diseases, acute partial or total ruptures may occur in the achilles tendon weakened due to drugs used. A 68-year-old male patient was admitted to department of emergency medicine with the complaints of pain and swelling in the left heel, and inability to stand up on his foot. The patient was considered to have achilles tendinopathy induced by polypharmacy, and acute achilles tendon rupture associated with the use of an oral anticoagulant. Due to the age and accompanying comorbid diseases of the patient and the presence of partial rupture in the tendon, a conservative treatment was used. In patients with polypharmacy due to advanced age and comorbid diseases, avoidance of use of fluoroquinolones unless really needed is very important to prevent achilles tendon ruptures. Predisposition to hemorrhage which is a complication of commonly used oral anticoagulants may cause, albeit rarely, rupture in a weakened achilles tendon.

**Keywords:** Achilles tendon; fluoroquinolone; corticosteroid; anticoagulant

**A**chilles tendon is the strongest and largest tendon in the body. Representing the conjoined tendons of the gastrocnemius and soleus muscles, achilles tendon is involved in knee flexion, foot plantar flexion and hindfoot inversion.<sup>1</sup> Achilles tendon rupture is a common injury in athletes. It often presents with sudden onset of pain associated with a snapping sound in the lower leg. Patients often describe this sensation as having been kicked or shot in the lower leg. The injury is often disabling, and ambulation is difficult. Since its vascularity toward the 2-6 cm proximal to its insertion on the calcaneus is poor, this area is vulnerable to degeneration and injury. Achilles tendon injury often occurs due to causes including intrinsic and extrinsic factors. Biomechanical abnormalities such as length differences of lower limbs, and systemic causes such as hyperpronation, varus deformity of the forefoot, pes cavus, limited movement of subtalar joint, advanced age, inflammatory arthropathy, use of corticosteroids, diabetes mellitus, hypertension, obesity, gout, hyperlipidemia, use of aromatase inhibitors and quinolone group antibiotics constitute the intrinsic factors.<sup>2-6</sup> It is known that the achilles tendon weakens, tendinitis develops and the risk for tendon rupture increases with the use of fluoroquinolones and corticosteroids (oral and inhaler).<sup>7</sup> The risk for development of achilles tendon pathology with these drugs increases especially after 60 years of age.<sup>8</sup> In the literature, spontaneous bilateral achilles tendon rupture was reported in patients with long-term corticosteroid use for chronic obstructive pulmonary disease.<sup>9</sup> In this case report, we aimed to

present an achilles tendon rupture developed after initiation of oral anticoagulant therapy in our patient who had used fluoroquinolone and long-term inhaled corticosteroid for his comorbid diseases.

## CASE REPORT

A 68-year-old male patient was admitted to department of emergency medicine with the complaints of pain and swelling in the left heel, and inability to stand up on his foot. It was learned from his history that, without any history of trauma, swelling had occurred in the dorsal left ankle and a sharp, breakthrough pain had occurred in his left leg causing inability to put weight on his foot. His personal history included chronic obstructive pulmonary disease and hypertension for 15 years, newly diagnosed atrial fibrillation; coronary artery bypass surgery 5 years ago, and smoking of 55packs/year. He was taking theophylline, inhaler steroid, angiotensin-converting enzyme inhibitor, beta-blocker, anti-thrombolytic and oral anticoagulant therapies for his comorbidities. It was learned that he had received two courses of fluoroquinolone therapy during the last three months due to frequently recurring respiratory tract infection. No features were seen in his family history. The patient's height was 1,80 centimetre and weight was 80 kg. The body mass index was 24,7.

On physical examination the patient was alert, afebrile, and well oriented, with stable vital signs. The neurological exam and the patient's reflexes were normal. The physical examination revealed an ecchymosis on the left side on the achilles tendon. The patient could not pick his heel up by putting weight on toetips. Palpation revealed tenderness and a non-pitting swelling in this area of the tendon. Thompson's test was positive.

There were no features in the laboratory results. Direct radiography of the foot and ankle were normal. Ultrasonographic examination revealed hematoma in the achilles tendon area, and loss of integrity of the achilles tendon. Magnetik resonance imaging revealed Hungland's deformity, marked thinning and increased signaling of the achilles tendon, partial rupture, and effusion in the surrounding fat planes (Figures 1 and 2).

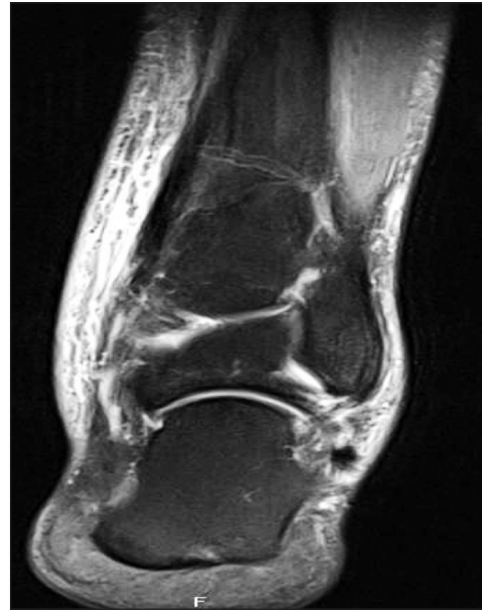

FIGURE 1: Magnetik resonance imaging of the achilles tendon with partial rupture and effusion.

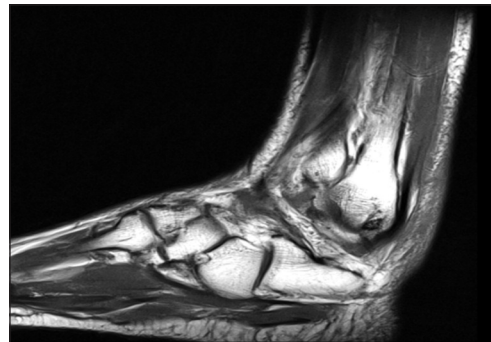


FIGURE 2: Magnetik resonance imaging of the achilles tendon.

Our patient was considered to have achilles tendinopathy induced by polypharmacy, and acute achilles tendon rupture associated with the use of an oral anticoagulant. Due to the age and accompanying comorbid diseases of the patient and the presence of partial rupture in the tendon, a conservative treatment was used. In the conservative approach, a six-week immobilization at 20-degree plantar flexion was applied, and the plantar flexion degree was gradually reduced thereafter. The patient required physical and orthotic therapy to help strengthen the muscles and improve range of motion of the ankle. Rehabilitation is critical to regaining maximal ankle function. Therefore following removal of the plaster gentle ROM and stretching

exercises were initiated, progressive resistive exercises were initiated after the eighth week, and transfer of weight bearing with a heel wedge for three months.

Written informed consent was obtained from the patient for publishing the individual medical records.

## DISCUSSION

Achilles tendon is one of the most functional tendons in the body, playing an important role in ambulation and daily activities. A damaged achilles tendon causes a significantly debilitating effect on activities.<sup>1</sup> Acute achilles tendon rupture is the most common tendon injury in adult population, seen especially in males during the third and fourth decades. Factors such as aging process, comorbid diseases and use of some commonly prescribed drugs lead to tendinopathy possibly causing increased risk of tendon rupture.<sup>10</sup> In the literature, fluoroquinolone-induced tendinopathy was firstly reported in 1982, and more than 100 cases were presented there after.<sup>11</sup> The studies concluded that the risk for tendon diseases increase in the population using quinolone antibiotics being mostly in the form of achilles tendon rupture and the use of quinolones and other drugs may facilitate rupture.<sup>12,13</sup> Several risk factors were described in fluoroquinolone-induced tendinopathy. Long-term systemic or inhaler steroid use is the most important risk factor.<sup>14</sup> The other risk factors are male sex, advanced age (>60 years), hemodialysis, renal transplantation, sports activities and history of rheumatoid disease.<sup>15</sup> The pathophysiology of drug-induced tendinopathy is not clear. The possible mechanisms are increased extracellular matrix breakdown, affected metabolism of fibroblasts involven in collagen synthesis, and increased apoptosis of tenocytes. Similarly with the cases reported in the literature, our patient was a 68-year-old male, and had been continuously

used inhaler steroid for 15 years due to chronic obstructive pulmonary disease. He had received two courses of fluoroquinolone therapy during the last three months due to respiratory tract infection. Although many risk factors were described in the literature relating to achilles tendinopathy and acute achilles tendon rupture, there are no reports relating to tendon rupture following use of oral anticoagulants. According to the literature, an improved rupture during the use of quinolones, but other medicines may have contributed to this phenomenon. Our patient was admitted to the emergency department due to swelling in the dorsal left ankle and a sharp, breakthrough pain in his left leg after initiation of anticoagulant therapy for newly diagnosed atrial fibrillation.

In conclusion, in patients with polypharmacy due to advanced age and comorbid diseases, avoidance of use of fluoroquinolones unless really needed is very important to prevent achilles tendon ruptures.

### Source of Finance

*During this study, no financial or spiritual support was received neither from any pharmaceutical company that has a direct connection with the research subject, nor from a company that provides or produces medical instruments and materials which may negatively affect the evaluation process of this study.*

### Conflict of Interest

*No conflicts of interest between the authors and / or family members of the scientific and medical committee members or members of the potential conflicts of interest, counseling, expertise, working conditions, share holding and similar situations in any firm.*

### Authorship Contributions

**Idea/Concept:** Tuba Erdem Sultanoğlu; **Design:** Hasan Sultanoğlu; **Control/Supervision:** Tuba Erdem Sultanoğlu; **Data Collection and/or Processing:** Hasan Sultanoğlu; **Analysis and/or Interpretation:** Hasan Sultanoğlu; **Literature Review:** Tuba Erdem Sultanoğlu; **Writing the Article:** Tuba Erdem Sultanoğlu, Hasan Sultanoğlu.

## REFERENCES

1. Egger AC, Berkowitz MJ. Achilles tendon injuries. *Curr Rev Musculoskelet Med* 2017; 10(1):72-80.
2. Irwin TA. Current concepts review: insertional achilles tendinopathy. *Foot Ankle Int* 2010;31(10):933-9.
3. Strocchi R, De Pasquale V, Guizzardi S, Govoni P, Facchini A, Raspanti M, et al. Human achilles tendon: morphological and morphometric variations as a function of age. *Foot Ankle* 1999;12(2):100-4.
4. Tuite DJ, Renström PA, O'Brien M. The aging tendon. *Scand J Med Sci Sports* 1997;7(2):72-7.
5. Fahlström M, Lorentzon R, Alfredson H. Painful conditions in the achilles tendon region: a common problem in middle-aged competitive badminton players. *Knee Surg Sports Traumatol Arthrosc* 2002;10(1):57-60.
6. Kirchgessner T, Larbi A, Omoumi P, Malghem J, Zamali N, Manefte J, et al. Drug-induced tendinopathy: from physiology to clinical applications. *Joint Bone Spine* 2014;81(6):485-92.
7. Sode J, Obel N, Hallas J, Lassen A. Use of fluoroquinolone and risk of achilles tendon rupture: a population-based cohort study. *Eur J Clin Pharmacol* 2007;63(5):499-503.
8. van der Linden PD, van Puijenbroek EP, Feenstra J, Veld BA, Sturkenboom MC, Herings RM, et al. Tendon disorders attributed to fluoroquinolones: a study on 42 spontaneous reports in the period 1988 to 1998. *Arthritis Rheum* 2001;45(3):235-9.
9. Khurana R, Torzillo PJ, Horsley M, Mahoney J. Spontaneous bilateral rupture of the achilles tendon in a patient with chronic obstructive pulmonary disease. *Respirology* 2002;7(2):161-3.
10. Kingsley P. Achilles tendon rupture in atypical patient populations. *Emerg Nurse* 2016;23(10):34-6.
11. Bailey RR, Kirk JA, Peddie BA. Norfloxacin-induced rheumatic disease. *N Z Med J* 1983;96(736):590.
12. Corrao G, Zambon A, Bertù L, Mauri A, Paleari V, Rossi C, et al. Evidence of tendinitis provoked by fluoroquinolone treatment: a case-control study. *Drug Saf* 2006;29(10):889-96.
13. van der Linden PD, Sturkenboom MC, Herings RM, Leufkens HG, Stricker BH. Fluoroquinolones and risk of achilles tendon disorders: case-control study. *BMJ* 2002;324(7349):1306-7.
14. Schwald N, Debray-Meignan S. Suspected role of ofloxacin in a case of arthralgia, myalgia, and multiple tendinopathy. *Rev Rhum Engl Ed* 1999;66(7-9):419-21.
15. Tsai WC, Yang YM. Fluoroquinolone-associated tendinopathy. *Chang Gung Med J* 2011;34(5):461-7.