

Optic Disc and Choroidal Metastasis from Laryngeal Squamous Cell Carcinoma

Larinks Skuamöz Hücreli Karsinom Kökenli Optik Disk ve Koroid Metastazlı Bir Olgu

^{ID} Murat OKUTUCU^a, ^{ID} Ünal ŞAHİN^a, ^{ID} Erkan DUMAN^b,
^{ID} Mehmet Gökhan ASLAN^a, ^{ID} Hüseyin FINDIK^a

^aDepartment of Ophthalmology, Recep Tayyip Erdoğan University Faculty of Medicine, Rize, TURKEY

^bDepartment of Ophthalmology, Ordu University Faculty of Medicine, Ordu, TURKEY

ABSTRACT A 67-year-old male patient was presented with loss of vision, which he noticed in his left eye one week ago. He had undergone total laryngectomy due to laryngeal squamous cell carcinoma 3 years ago. His fundus examination revealed an elevated yellow mass on the optic disc. Magnetic resonance imaging (MRI) and computed tomography (CT) were performed with suspicion of laryngeal cancer metastasis. The MRI showed metastatic lesions in the brain, optic disc, and the surrounding choroid. The CT demonstrated diffuse metastasis in both lungs. The patient received radiotherapy for the brain, optic disc, and choroidal metastases. Unfortunately, the patient died within 2.5 months after the diagnosis because of systemic complications that developed due to extraocular causes. Metastasis of laryngeal cancer to the optic disc and choroid is rare. Although the majority of optic disc tumors are primary, a systemic investigation should be performed in cases of a mass on the disc with the suspicion of distant organ metastasis, albeit rare.

Keywords: Laryngeal neoplasms; neoplasm metastasis; optic disc; choroid

ÖZET Altmış yedi yaşında erkek hasta, 1 hafta önce sol gözünde fark ettiği görme kaybı şikâyeti ile başvurdu. Üç yıl önce laringeal skuamöz hücreli karsinom nedeniyle total larenjektomi geçirdiği öğrenildi. Fundus muayenesinde, optik diskte sarı bir kitle görüldü. Larinks kanseri metastazı şüphesi ile manyetik rezonans görüntüleme (MRG) ve bilgisayarlı tomografi (BT) yapıldı. MRG’de beyin, optik disk ve çevreleyen koroidde, metastatik lezyonlar tespit edildi. BT’de her iki akciğerde yaygın metastaz saptandı. Hasta beyin, optik disk ve koroid metastazları için radyoterapi aldı. Ekstraoküler nedenlere bağlı gelişen sistemik komplikasyonlar nedeniyle tanı konulduktan sonraki 2,5 ay içinde ne yazık ki hasta kaybedildi. Larinks kanserinin, optik disk ve koroide metastazı nadirdir. Optik disk tümörlerinin çoğunluğu primer olmakla birlikte, nadir de olsa uzak organ metastazı şüphesi ile diskte kitle olması durumunda sistemik inceleme yapılmalıdır.

Anahtar Kelimeler: Larinks neoplazileri; tümör metastazı; optik disk; koroid

Most of the diagnosed tumors of the optic disc are primary and benign.¹ Metastasis to the optic disc is rare and most of the metastatic cancers seen in the intraocular structures are detected in the uveal tissues.²⁻⁵ Optic disc metastases account for 5% of all intraocular metastases. Unlike the optic disc, the choroid is the most common ocular site affected by metastases.² The primary origin of most metastatic

tumors of the optic disc and choroid are breast and lung cancers. Adachi et al. have reported that intraocular metastases of laryngeal carcinomas are extremely rare (representing 0.2% of intraocular metastases).⁶ To our knowledge, two cases of laryngeal carcinoma metastasized to both the optic disc and choroid have been described to date.^{6,7} In the current study, we presented a case of primary laryngeal

Correspondence: Murat OKUTUCU

Department of Ophthalmology, Recep Tayyip Erdoğan University Faculty of Medicine, Rize, TURKEY/TÜRKİYE

E-mail: muratokutucu83@gmail.com



Peer review under responsibility of Türkiye Klinikleri Journal of Ophthalmology.

Received: 26 Sep 2020

Received in revised form: 10 Jan 2021

Accepted: 03 Feb 2021

Available online: 18 Feb 2021

2146-9008 / Copyright © 2021 by Türkiye Klinikleri. This is an open access article under the CC BY-NC-ND license (<http://creativecommons.org/licenses/by-nc-nd/4.0/>).

squamous cell carcinoma metastasized to the lung and brain in addition to the optic disc and choroid.

CASE REPORT

Written informed consent was obtained from the patient for publication of his case details and for images that were obtained via the medical imaging techniques. A 67-year-old male patient presented with a complaint of loss of vision in his left eye, persisting for 1 week. His medical history included that he had undergone total laryngectomy for laryngeal squamous cell carcinoma 3 years ago and not received any additional chemotherapy or radiotherapy.

On ocular examination, the best-corrected visual acuity was 6/10 in the right eye and counting fingers at 1 meter in the left eye. While the direct light reflex was normal in the right eye, the indirect light reflex was weak. And while the direct light reflex was very weak in the left eye, the indirect light reflex was normal. A relative afferent pupillary defect was detected in the left eye. The eye movements were normal in both eyes and no proptosis was observed. The patient did not describe any pain with or without eye movements.

His biomicroscopic examination revealed a corticonuclear cataract in both eyes. The intraocular pressure was within normal limits in both eyes. On dilated fundus examination, the right eye was normal (Figure 1A), a yellow mass, anteriorly protruding in the form of 3 lobules with spaces and stereoscopically appearing to be swollen, was observed in the optic disc of the left eye (Figure 2A). The mass caused an approximately 2.5-fold increase in the optic disc diameter and the ratio of the mass diameter to the optic disc diameter was around 9/10 (Figure 2A). Elevation caused by

choroidal metastasis with borders of 2 times the normal optic disc distance from the optic disc margin were noted in the retina surrounding the optic disc (Figure 2A). There was also venous stasis. Since the patient had fixation loss due to severe loss of vision, optical coherence tomography evaluation could not be performed. On fundus fluorescein angiography (FFA), hyperfluorescence, which started in the arterial phase due to the vascularization of the mass, gradually increased until the late arteriovenous phase, and intense staining was observed in the late phase (Figures 2B-D).

In the differential diagnosis of the mass, a metastatic lesion was considered primarily due to the history of primary optic disc tumor and laryngeal carcinoma. Neuroimage should be performed for lesions with suspected cancer in the optic disc. Neuroimaging provides information about the extension of the mass beyond the optic disc, the pathological changes it has caused in the optic nerve, and whether there are metastatic lesions in the brain. Orbital and cranial magnetic resonance imaging (MRI) performed further confirmed the presence of a mass lesion (19×16 mm) consisting of hemorrhagic foci in the brain (Figure 3A). Diffuse edematous signal changes were observed around the mass in the parafalcine region of the left frontal vertex (Figure 3A). A few millimetric signal changes consistent with the presence of micrometastases were noted in the peri-supraventricular cerebral white matter. Contrast enhancement has visualized the infiltration in the optic disc and the surrounding choroid (Figure 3C). Abdominal and axial contrast-enhanced thoracic computed tomography (CT) was performed to address the suspicion of an-

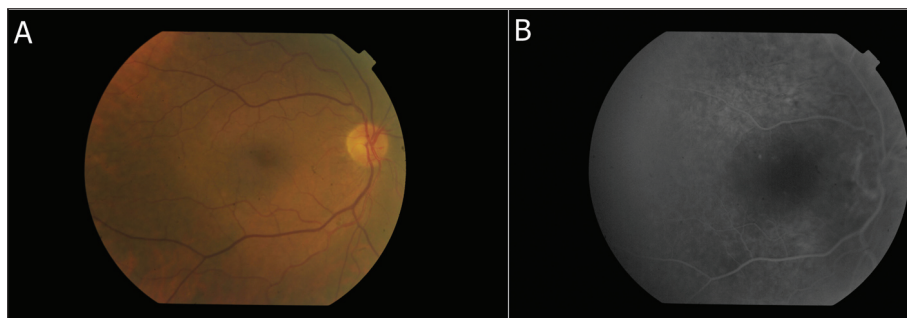


FIGURE 1: The color fundus photograph and fundus fluorescein angiography of the right eye were unremarkable (A, B).

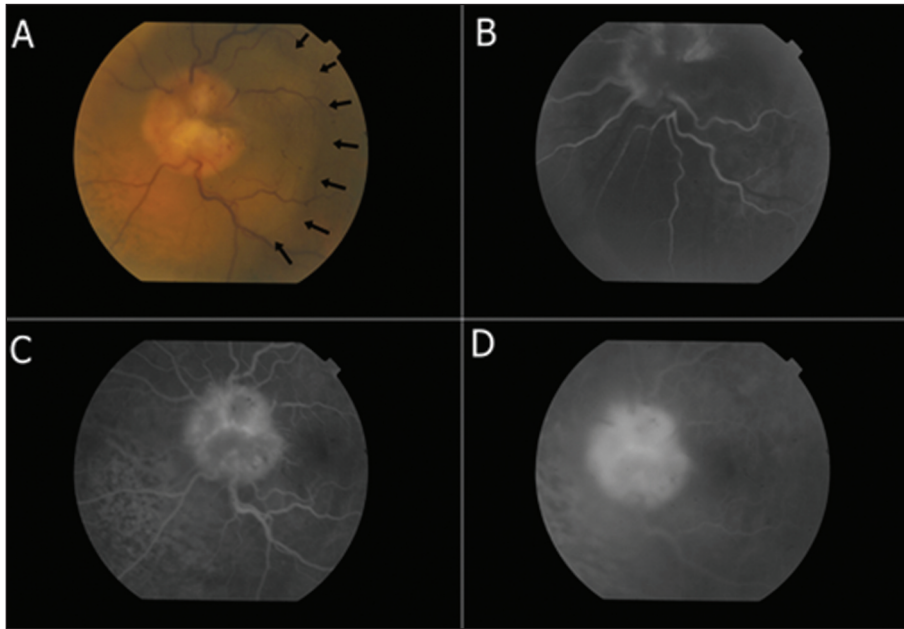


FIGURE 2: A color fundus photograph of the left eye. Diffuse yellow thickening marks the central portion of the optic disc. Thickening in the surrounding choroid due to the tumor is also observed (indicated with black arrow) (A). In fundus fluorescein angiography, hyperfluorescence that started in the arterial phase increased gradually until the late arteriovenous phase, and intense staining was observed in the late phase (B, C, D).

other systemic metastasis. Multiple round nodules and masses of varying sizes were detected in both lungs, consistent with diffuse metastasis (Figure 3D). The patient refused subsequent tests and treatment recommended for lung metastasis, yet accepted radiotherapy recommended for the brain, optic disc, and choroid metastasis.

The patient received 30 Gy total radiotherapy in three-Gy fractions for 10 days. During this treatment course, 32 mg prednisolone acetate and 750 mg acetazolamide were divided into three equal doses and administered orally three times a day. After 10 days, fundus examination showed a reduction in the size of the mass lesion, while FFA detected decreased vascularization on the optic disc (Figure 4A, B). Control cranial MRI demonstrated that the hemorrhage within the metastatic lesion in the brain was resorbed, while the tumor and surrounding edema were remained unchanged (Figure 3B). The patient died due to diffuse metastasis in the lung after two months.

DISCUSSION

The optic nerve can be infiltrated by primary or secondary tumors. Primary tumors of the optic nerve are

benign and malignant optic nerve glioma, ganglioglioma, medulloepithelioma, hemangioblastoma, and primary lymphoma.⁸ Primary optic nerve sheath tumors are meningioma, schwannoma, and hemangiopericytoma.⁸ In most of these tumors, proptosis, and infiltration are observed in the optic nerve behind the optic disc.⁸ In the present case, we ruled out primary optic nerve tumors in the differential diagnosis due to the absence of proptosis and optic nerve infiltration in the optic nerve, and most importantly, due to the detection of brain and lung metastases.

Metastases to the optic nerve can occur through the direct hematogenous spread, orbital invasion, and the central nervous system.⁵ If a hematogenous metastasis localizes anteriorly in the optic disc, it manifests as an elevated optic nerve head lesion.⁵ In the present case, there was a metastasis localized in the anterior portion of the optic nerve, presenting as an elevated optic nerve head lesion.

Affected patients often have a history of cancer, and systemic metastasis further suggests a diagnosis of optic disc metastasis.⁵ Thus, the presence of lung and brain metastasis in the present case further confirmed the diagnosis. Most metastases to the optic

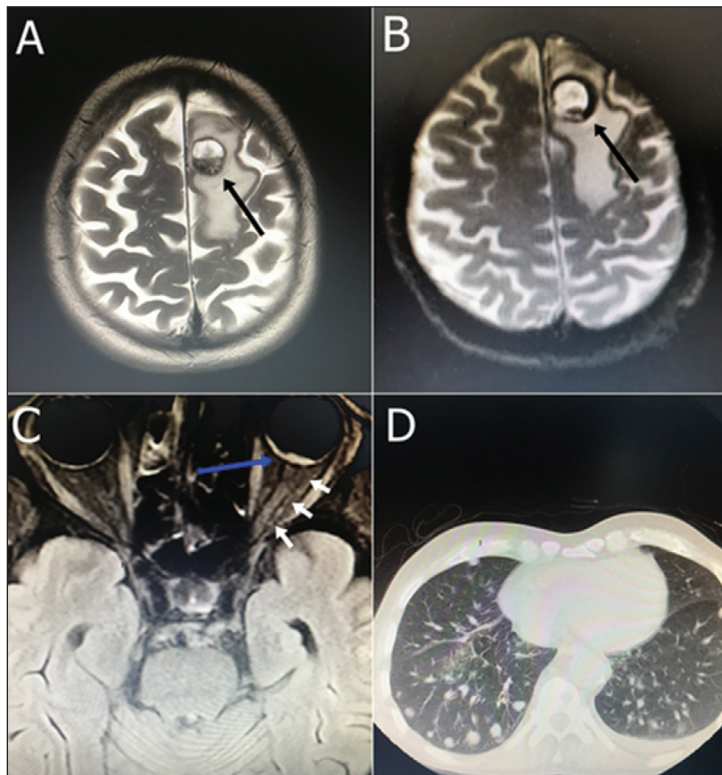


FIGURE 3: Cranial magnetic resonance imaging (MRI), shows the mass lesion and surrounding diffuse edematous signal changes consistent with hemorrhagic metastasis at the level of the left frontal vertex (indicated with black arrow) (A). Cranial MRI was performed 15 days after external beam radiation treatment. Hemorrhage within the metastatic lesion in the brain is resorbed, while tumor size and surrounding edema remain unchanged (indicated with black arrow) (B). Orbital MRI shows contrast enhancement in the optic disc and surrounding choroid (indicated with blue arrow) consistent with metastasis. No contrast enhancement was observed in the optic nerve behind the optic disc (indicated with white arrows) (C). Axial computed tomography shows multiple round nodules and masses of varying sizes consistent with diffuse metastasis in both lungs (D).

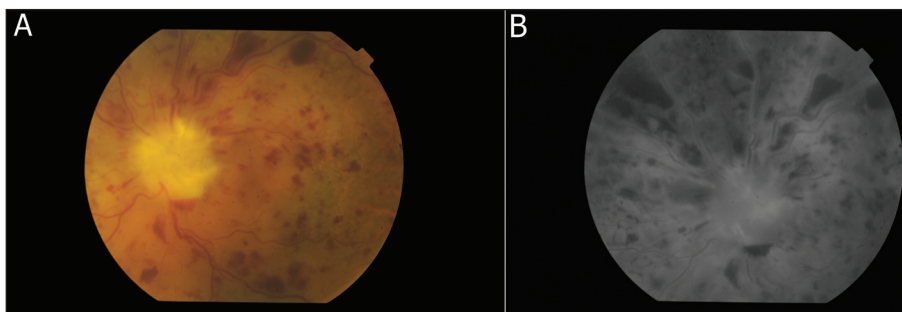


FIGURE 4: The appearance of the affected eye 15 days after external beam irradiation. Marked regression of the tumor in the central portion of the optic disc is observed. Residual tumor masses on the boundaries of the optic disc are also noted. Diffuse retinal hemorrhage due to decreased venous congestion and radiation retinopathy in the retina caused by external beam irradiation is observed (A). A marked decrease in intense hyperfluorescence of the mass is observed with fundus fluorescein angiography 15 days after external beam radiation treatment. Minimal hyperfluorescence is also observed for residual tumor masses on the boundaries of the optic disc (B).

disc occur during adulthood at a median age of 55 years.⁵ In the present case, the patient was 67 years old.

In FFA, most tumors show relative hypofluorescence in the arterial phase and gradually increasing hyperfluorescence in the late arteriovenous phase,

and moderate staining in the late phase.⁵ In the present case, however, hyperfluorescence that started in the arterial phase increased gradually until the late arteriovenous phase, and intense staining was observed in the late phase.

The preferred treatment for these lesions is external radiotherapy.⁵ Visual acuity is preserved in 40% of patients after radiotherapy, while tumor regression is observed in 45% of patients.⁵ The visual acuity of our patient was the same before and after treatment, yet the tumor was considerably reduced. After the detection of an optic disc metastasis, the average life expectancy is 8 months.⁵

Unfortunately, our patient died approximately 2.5 months after his diagnosis. To the best of our knowledge, this is the first case of a primary laryngeal squamous cell carcinoma metastasizing to both the lung and the brain in addition to the optic disc and the choroid. Thus, the potential for optic disc swelling to be associated with metastatic cancer should be considered. A careful medical history of both the primary site and metastasis to other organs should be made to obtain a differential diagnosis.

Source of Finance

During this study, no financial or spiritual support was received neither from any pharmaceutical company that has a direct connection with the research subject, nor from a company that provides or produces medical instruments and materials which may negatively affect the evaluation process of this study.

Conflict of Interest

No conflicts of interest between the authors and / or family members of the scientific and medical committee members or members of the potential conflicts of interest, counseling, expertise, working conditions, share holding and similar situations in any firm.

Authorship Contributions

Idea/Concept: Murat Okutucu; **Design:** Murat Okutucu; **Control/Supervision:** Ünal Şahin; **Data Collection and/or Processing:** Murat Okutucu, Mehmet Gökhan Aslan; **Analysis and/or Interpretation:** Ünal Şahin, Murat Okutucu; **Literature Review:** Murat Okutucu, Erkan Duman, Hüseyin Fındık; **Writing the Article:** Murat Okutucu, Ünal Şahin, Erkan Duman; **Critical Review:** Murat Okutucu, Ünal Şahin, Erkan Duman; **Materials:** Murat Okutucu, Hüseyin Fındık.

REFERENCES

1. Miller NR. Primary tumours of the optic nerve and its sheath. *Eye (Lond)*. 2004;18(11):1026-37. [[Crossref](#)] [[PubMed](#)]
2. Shields CL, Shields JA, Gross NE, Schwartz GP, Lally SE. Survey of 520 eyes with uveal metastases. *Ophthalmology*. 1997;104(8):1265-76. [[Crossref](#)] [[PubMed](#)]
3. Shields JA, Shields CL. Metastatic tumors to the intraocular structures. *Intraocular Tumors: A Text and Atlas*. Shields JA, Shields CL, ed. Philadelphia: Saunders; 1992. p.207-38.
4. Brown GC, Shields JA. Tumors of the optic nerve head. *Surv Ophthalmol*. 1985;29(4):239-64. [[Crossref](#)] [[PubMed](#)]
5. Shields JA, Shields CL, Singh AD. Metastatic neoplasms in the optic disc: the 1999 Bjerrum Lecture: part 2. *Arch Ophthalmol*. 2000;118(2):217-24. [[Crossref](#)] [[PubMed](#)]
6. Adachi N, Tsuyama Y, Mizota A, Fujimoto N, Suehiro S, Adachi-Usami E. Optic disc metastasis presenting as an initial sign of recurrence of adenoid cystic carcinoma of the larynx. *Eye (Lond)*. 2003;17(2):270-2. [[Crossref](#)] [[PubMed](#)]
7. Garcia-Martin E, Pinilla I, Alias EG, Idoipe M. Choroidal and optic disk metastases of a laryngeal carcinoma. *Retin Cases Brief Rep*. 2011;5(1):30-2. [[Crossref](#)] [[PubMed](#)]
8. Miller NR. Chapter 9 primary and secondary tumors of the optic nerve and its sheath. *Blue Books of Neurology*. 2008;32:206-37. [[Crossref](#)]