

Diagnosis and Evaluation of Stafne's Bone Defect Using Computerized Tomography: Case Report

Stafne Kemik Defekti'nin Bilgisayarlı Tomografi ile Teşhisi ve Değerlendirilmesi

Ahmet Ercan ŞEKERCİ,^a
Yıldıray ŞİŞMAN,^a
Elif TARIM ERTAŞ^a

^aDepartment of Oral Diagnosis and Radiology,
Erciyes University Faculty of Dentistry,
Kayseri

Geliş Tarihi/Received: 28.04.2010
Kabul Tarihi/Accepted: 31.05.2010

Yazışma Adresi/Correspondence:
Ahmet Ercan ŞEKERCİ
Erciyes University Faculty of Dentistry,
Department of Oral Diagnosis and Radiology, Kayseri,
TÜRKİYE/TURKEY
aercansekerci@hotmail.com

ABSTRACT Stafne's bone defects (SBDs) are asymptomatic radiolucent lingual bone lesions of the lower jaw and are frequently caused by salivary glands. These defects have a cyst like appearance on plain film radiographs. The diagnosis of this defect is incidental, since patients don't usually present clinical symptoms. The common variant of SBD exists at third molar region of the mandible below the inferior dental canal. Anterior variant of SBD is relatively uncommon and located at incisor-canine-premolar region. Salivary gland is usually responsible for SBD. Diagnosis of this lesion is important due to its similarity to other odontogenic pathologies. Advanced imaging techniques are useful in diagnosing these types of lesions in order to avoid unnecessary surgery. In this report, a case of Stafne's bone defect, diagnosed by computerized tomography scan, is presented.

Key Words: Tomography; imaging, three-dimensional; mandible; salivary glands

ÖZET Stafne kemik defektleri (SBDs) sıklıkla tükürük bezlerinin sebep olduğu alt çenenin asemptomatik radyolüsent lingual kemik lezyonlarıdır. Bu defektler klasik radyograflarda kiste benzer görünüme sahiptirler. Hastalarda genellikle klinik belirti göstermediğinden defektin teşhisi rastlantısalıdır. SBD'nin en yaygın çeşidi mandibulanın üçüncü molar bölgesinde inferior dental kanalın altında bulunur. SBD'nin daha anterior bölgedeki çeşidi nispeten daha az görülür ve kesici-kanin-premolar bölgesinde yerleşmiştir. SBD'den genellikle tükürük bezi sorumludur. Bu lezyonun tanısı, diğer odontojenik patolojilere benzerliği nedeni ile önemlidir. Gereksiz cerrahiden kaçınmak için bu lezyonların tespitinde ileri görüntüleme tekniklerinin kullanımı yararlıdır. Bu raporda bilgisayarlı tomografiyle tespit edilen bir stafne kemik defekti sunulmuştur.

Anahtar Kelimeler: Tomografi; görüntüleme, üç-boyutlu; mandibula; tükürük bezleri

Türkiye Klinikleri J Dental Sci 2013;19(1):59-64

Stafne's bone defects (SBDs) are asymptomatic, well-defined, radiolucent lingual bony defects location in the mandible. SBDs were first described in 1942 by Edward Stafne.¹ These cavities have a cyst like appearance on simple radiographs, and they appear as round or ovoid well-circumscribed unilocular radiolucencies.²⁻⁴

The most common location is within the submandibular gland fossa and often close to the inferior border of the mandible (posterior variant). Similar defects have also been described in the anterior region near the apical region of the bicuspids, associated with the sublingual glands (lingual

anterior variant), and, very rarely, on the lingual surface of the ascending ramus, associated with the parotid gland (medial ramus variant).^{4,5}

There is no universally accepted theory concerning the etiology of SBDs.⁶ Congenital or developmental origins are described as possibilities in the literature.⁷ Nevertheless some writers suggested the idea that pressure and aberration of the glandular tissue on the lingual cortex of the mandible causes a lingual bony depression.⁸ Salivary gland tissue has often been found in SBDs that have been explored surgically.⁷⁻¹⁰ SBDs have not been documented in children below the age of 11; they are most common in males in their 5th to 7th decades of life. The posterior variant of SBD is quite rare (0.1-0.48%)^{11,12} in general population. When diagnosed radiographically anterior variant of SBD (ASBD) is comparatively uncommon (less than 0.009%)¹³ compared with the posterior variant and is located in the premolar region. Since SBDs produce no symptoms and generally do not progress, they are often left untreated.⁶ The use of 3-dimensional computerized tomography imaging in diagnosing SBD has been reported only rarely.

The purpose of this report is to describe a case of SBD occurring in the body of the mandible and to focus on the role of CT imaging in establishing of the final diagnosis.

CASE REPORT

A 42 year-old otherwise healthy man was referred to our clinic for a routine dental examination and periodontal management. A panoramic radiograph revealed a unilateral, well-defined unilocular radiolucent lesion in the right third molar region below the inferior alveolar canal slightly above the basis mandible (Figure 1).

The lesion was asymptomatic, and no history of expansion was recorded. The patient's medical history was unremarkable. The patient was informed about possible odontogenic pathologies and surgical interventions. The patient was also informed about the advanced imaging techniques and their advantages and disadvantages. An informed consent was taken from the patient. Be-

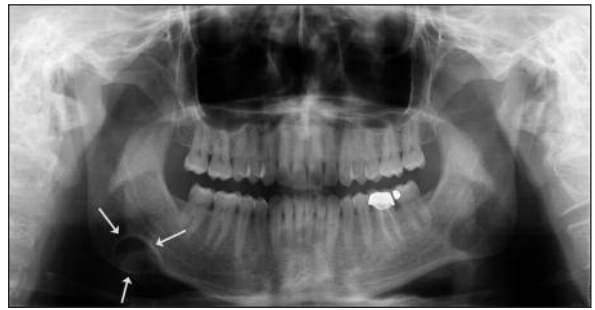

FIGURE 1: Panoramic radiography reveals a large radiolucent lesion on the right side of the mandible.

cause CT is more specific to bone lesions of the jaws CT scanning was performed to attain a definitive diagnosis. CT scans (Siemens Somatom Definition AS 64-slice, 120 kVp, 226 mA) obtained from the patient showed a corticated defect on the lingual surface in right side of the mandible. Using a soft tissue window, the axial CT images showed that the radiographic content of the cavity consisted of submandibular gland and fat tissue (Figure 2). Buccolingual CT images displayed a characteristic opening of the defect in the lingual mandibular cortex (Figure 3). The three-dimensional (3D) CT volume rendering reconstructed image showed it was a cortical bone defect located in the lingual area of the mandible (Figure 4).

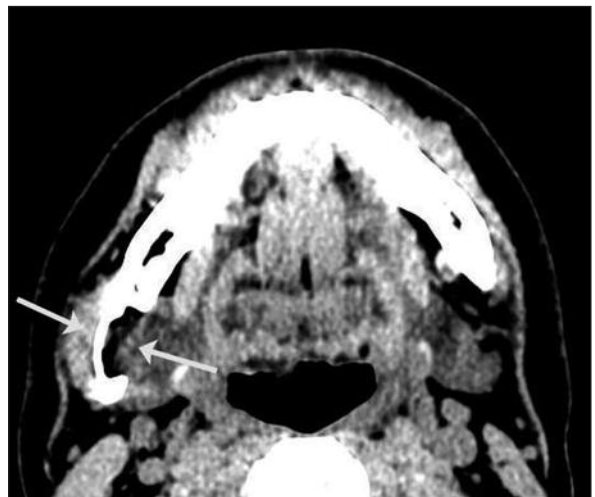


FIGURE 2: Axial CT scans, using soft tissue window, showing soft tissue mass (arrowed) on the lingual cortex of the mandible. Mesiodistal location of the defect; the long black line shows Mylohyoid muscle. Dental CT showed submandibular gland and fat tissue of low attenuation in the cavity of the mandible.

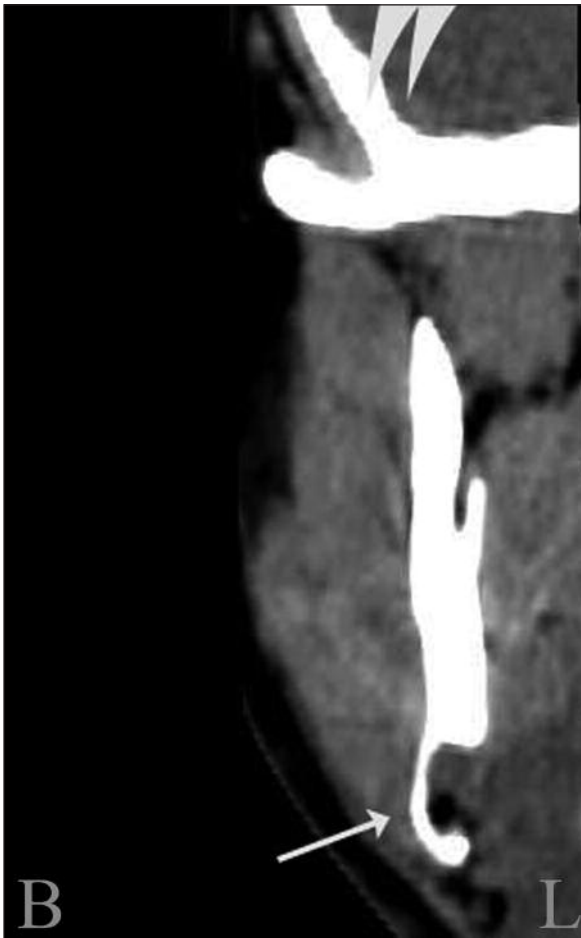

FIGURE 3: Axial CT scan of the mandible with bucco-lingual reconstruction program showing the sharply demarcated lesion, affecting the lingual surface of the mandible.

L: lingual, B: buccal.

The lesion was diagnosed as SBD. The patient was informed about the lesion and follow-up was recommended. After 4 years of follow-up, no change was observed in the panoramic view.

DISCUSSION

The characteristic radiographic appearance of a Stafne's bone cavity is that of an oval, homogeneous radiolucency with a well-defined border located below the inferior alveolar canal between the premolars and the angle of the mandible, often staging the lower border of the mandible.¹⁴⁻¹⁸ This lesion has also been defined as a lingual mandibular bone depression, Stafne's bone cavity, a static bone cyst and idiopathic bone cavity.^{11,12}

In spite of numerous theories regarding the etiology of SBD, its cause is controversial. Stafne suggested that the occurrence of lingual cavities is developmental, and, as a result, the defect is filled with cartilaginous tissue because of bone deposition deficiency.¹ However, some authors have suggested that glandular tissue pressure on the lingual cortex of the mandible causes a lingual bony depression.⁸ According to this extensively accepted theory, the submandibular salivary gland is responsible for the posterior variant SBDs whereas the sublingual gland causes anterior SBDs.¹⁹ Thus, many researchers have found glandular tissue within the defects either during surgical exploration or on magnetic resonance imaging (MRI).²⁰

Histological study revealed normal salivary gland tissue which suggested a developmental origin during which a part of the submandibular gland was inveigled in the lingual mandibular cortex.²² During surgery, the cavity has been found to

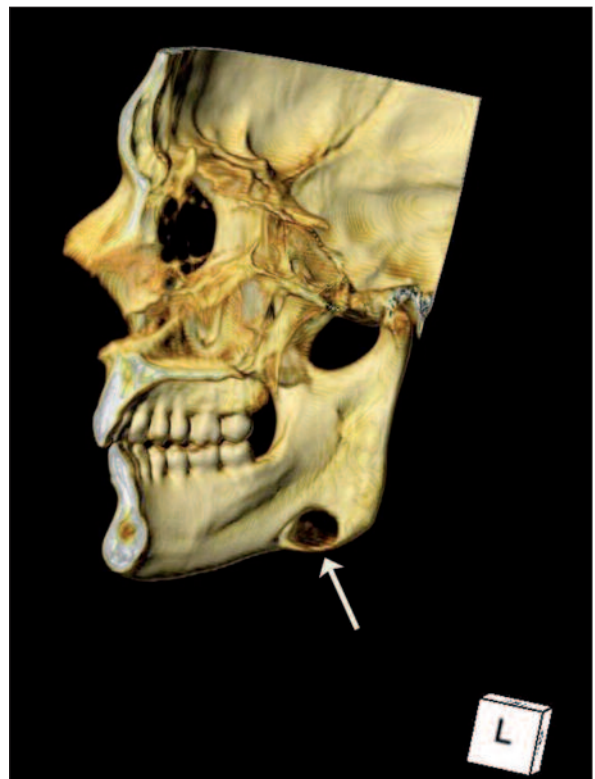


FIGURE 4: Three-dimensional reconstruction of a CT. The bone depression (Stafne's cavity) can be seen in the lingual area of the mandible.

(See for colored form <http://dishekimligi.turkiyeklinikleri.com/>)

contain salivary glands, lymphoid tissue, fibrous connective tissue, fat, muscle or blood vessels.⁷ However, empty cavities have also been recorded.²³ In addition, Shibata et al. reported cavity healing after removal of the glandular tissue inside the cavity.²⁴

Drage et al. reported that SBD is unlikely to be a developmental abnormality since it is very rarely found in children and is commonest in middle-aged and elderly individuals.²¹ The lesions do not appear to enlarge with age. In this case report, no expansion in the cavity was seen in our patient from the panoramic film which was taken at the four year follow-up. However, extension of the cavity above the position of the inferior dental nerve has been reported.^{16,17}

Shimizu et al. reported that SBDs which are located above the base of mandible generally include fat tissue.²⁵ According to their study, these types of defects usually settle anteriorly from the distal border of the mylohyoid muscle. Our findings support their results.

SBD is commonly encountered incidentally in plain radiographs, and differential diagnosis includes odontogenic cyst and tumor-like lesions such as ameloblastoma, metastasis, traumatic bone cyst, giant cell tumor, vascular malformation, focal osteoporotic bone marrow defect, periapical cyst, residual cyst, dentigerous cyst, odontogenic keratocyst, nonossifying fibroma, fibrous dysplasia, basal cell nevus syndrome, and the brown tumor of hyperparathyroidism.^{8,19,26} Review of the literature reveals that residual cysts, radicular cysts and noninflammatory odontogenic cysts are the most frequent diagnoses included in differential diagnoses.²⁷

As a result, in some cases more confirmatory diagnostic tools are mandatory. In some cases, conventional radiographs may be inadequate for diagnostic confirmation of the lesions. Advanced techniques such as CT, cone-beam tomography, MRI and sialography may be needed to form a final diagnosis of SBD.²⁰ Gomez et al. recommended that CT scanning be a complementary di-

agnostic procedure for SBD.²⁰ The presence of other cystic lesions can also be detected using this technique. Smith et al. found the possible disadvantages of CT scanning to be increased ionized radiation exposure and possible contrast allergy.²⁸ Also they concluded that MRI is the most useful diagnostic tool for detecting the content and extent of SBD. Segev et al. agreed that detection of SBD with CT is easier than MRI, but they also declared that MRI should be considered in order to identify the content of the cavity.² The most important advantage of MRI is its superior soft tissue characterization and discrimination. The superior soft tissue contrast of MR imaging should be sufficient to make a diagnosis of SBC, even without using intravenous contrast material. The major disadvantage of MRI imaging is its high cost, long scan times, and the distortion artifacts produced by dental material.² MRI is suggested for the definitive diagnosis of SBC.²⁹ Sialography is also a diagnostic technique used to determine the glandular tissue contents in the cavity. However, this procedure is invasive and uncomfortable for patients.³¹ Moreover, sialographic evaluation of anterior SBDs is relatively hard to perform owing to the multiple ducts in the sublingual gland. The use of cone-beam computed tomography is non-invasive, easy to perform, and enables both diagnosis and follow-up.¹² CBCT offers several advantages over medical CT such as rapid scan time, limitation of the beam to the head and neck, and lower radiation doses. Dolanmaz et al. reported that dental CBCT imaging is an effective diagnostic tool due to its low level radiation of exposure and detailed visualization.³⁰

In this report, we used axial and coronal CT images using both soft and bone window settings and we found that the content of the cavity was consistent with fat and submandibular tissue. Axial and coronal CT scans using soft tissue window as well as 3-dimensional reconstruction images showed that the lesion was a lingual bone defect with irregular borders. Interpretation of CT images with both soft and bone tissue window settings may be sufficient to exclude possible diagnosis of

other pathologies, to achieve final diagnosis of SBD, and to identify the content of the cavity. Most studies agree that surgery is not indicated.^{22,32} The literature contains a number of reports describing surgical findings, but surgical exploration or biopsy should not be necessary, as in this case, it is rarely performed.^{25,33,34} Consequently, radiographic follow-up is recommended. Reformatted CT images are ideal in that they, allow good contrast as regards size and extent over a period of time.²⁷ CT scans obtain detailed information in the definitive diagnosis of SBD.

In summary, we recommend asymptomatic radiolucent lesions in the mandible should be evaluated with advanced imaging techniques to differentiate between possible cysts and tumor-like lesions. In addition, clinicians should be aware of suspicious radiolucent lesions of the mandible and should apply multiple imaging procedures in order to avoid unnecessary surgery.

Acknowledgement

We thanks to Prof. Lous Bradt for her help on proof-reading.

REFERENCES

1. Stafne E. Bone cavities situated near the angle of the mandible. *J Am Dent Assoc* 1942;29:1969-72.
2. Segev Y, Puterman M, Bodner L. Stafne bone cavity--magnetic resonance imaging. *Med Oral Patol Oral Cir Bucal* 2006;11(4):E345-7.
3. de Courten A, Küffer R, Samson J, Lombardi T. Anterior lingual mandibular salivary gland defect (Stafne defect) presenting as a residual cyst. *Oral Surg Oral Med Oral Pathol Oral Radiol Endod* 2002;94(4):460-4.
4. Şahin M, Görgün S, Güven O. [Stafne's bone cavity]. *Türkiye Klinikleri J Dental Sci* 2005; 11(2):39-42.
5. White SC, Pharoah MJ. Developmental Disturbances of the Face and Jaws. *Oral Radiology, Principles and Interpretation*. 5th ed. St. Louis: Mosby-Year Book; 2004. p.639-57.
6. Minowa K, Inoue N, Sawamura T, Matsuda A, Totsuka Y, Nakamura M. Evaluation of static bone cavities with CT and MRI. *Dentomaxillofac Radiol* 2003;32(1):2-7.
7. Gorab GN, Brahney C, Aria AA. Unusual presentation of a Stafne bone cyst. *Oral Surg Oral Med Oral Pathol* 1986;61(3):213-5.
8. Tsui SH, Chan FF. Lingual mandibular bone defect: case report and review of the Literature. *Aust Dent J* 1994;39(6):368-71.
9. Choukas NC. Developmental submandibular gland defect of the mandible: review of the literature and report of two cases. *J Oral Surg* 1973;31(3):209-11.
10. Shiratsuchi Y, Tashiro H, Yuasa K, Kanda S. Posterior lingual mandibular bone depression. *Int J Oral Maxillofac Surg* 1986;15(1): 98-101.
11. Philipsen HP, Takata T, Reichart PA, Sato S, Suei Y. Lingual and buccal mandibular bone depressions: a review based on 583 cases from a world-wide literature survey, including 69 new cases from Japan. *Dentomaxillofac Radiol* 2002;31(5):281-90.
12. Slasky BS, Bar-Ziv J. Lingual mandibular bony defects: CT in the buccolingual plane. *J Comput Assist Tomogr* 1996;20(3):439-43.
13. Belmonte-Caro R, Vélez-Gutiérrez MJ, García De La Vega-Sosa FJ, García-Perla-García A, Infante-Cossío PA, Díaz-Fernández JM, et al. A Stafne's cavity with unusual location in the mandibular anterior area. *Med Oral Patol Oral Cir Bucal* 2005;10(2):173-9.
14. Palladino VS, Rose SA, Curran T. Salivary gland tissue in the mandible and Stafne's mandibular 'cysts'. *J Am Dent Assoc* 1965; 70:388-93.
15. Reuter I. An unusual case of Stafne bone cavity with extra-osseous course of the mandibular neurovascular bundle. *Dentomaxillofac Radiol* 1998;27(3):189-91.
16. Kay LW. Some anthropologic investigations of interest to oral surgeons. *Int J Oral Surg* 1974;3(6):363-79.
17. Langlais RP, Cottone J, Kastle MJ. Anterior and posterior lingual depressions of the mandible. *J Oral Surg* 1976;34(6):502-9.
18. Lello GE, Makek M. Stafne's mandibular lingual cortical defect. Discussion of aetiology. *J Maxillofac Surg* 1985;13(4):172-6.
19. de Courten A, Küffer R, Samson J, Lombardi T. Anterior lingual mandibular salivary gland defect (Stafne defect) presenting as a residual cyst. *Oral Surg Oral Med Oral Pathol Oral Radiol Endod* 2002;94(4):460-4.
20. Quesada-Gómez C, Valmasada-Castellón E, Berini-Aytés L, Gay-Escoda C. Stafne bone cavity: a retrospective study of 11 cases. *Med Oral Patol Oral Cir Bucal* 2006;11(3): E277-80.
21. Drage NA, Renton T, Odell EW. Atypical Stafne bone cavity. *Clinical Radiology Extra* 2003;58(7):51-3.
22. Buchner A, Carpenter WM, Merrell PW, Leider AS. Anterior lingual mandibular salivary gland defect. Evaluation of twenty-four cases. *Oral Surg Oral Med Oral Pathol* 1991;71(2): 131-6.
23. Olech E, Arora BK. Lingual mandibular bone cavity. *Oral Surg Oral Med Oral Pathol* 1961;14:1360-6.
24. Shibata H, Yoshizawa N, Shibata T. Developmental lingual defect of the mandible: report of a case. *Int J Oral Maxillofac Surg* 1991; 20(6):328-9.
25. Shimizu M, Osa N, Okamura K, Yoshiura K. CT analysis of the Stafne's bone defects of the mandible. *Dentomaxillofac Radiol* 2006;35(2): 95-102.
26. Barrer G. Xeroradiography in relation to a Stafne bone cavity. *Br J Oral Maxillofac Surg* 1988;26(1):32-5.
27. Katz J, Chaushu G, Rotstein I. Stafne's bone cavity in the anterior mandible: a possible diagnostic challenge. *J Endod* 200;27(4):304-7.
28. Smith MH, Brooks SL, Eldevik OP, Helman JI. Anterior mandibular lingual salivary gland defect: a report of a case diagnosed with cone-beam computed tomography and magnetic resonance imaging. *Oral Surg Oral Med Oral Pathol Oral Radiol Endod* 2007;103(5): 71-8.
29. Branstetter BF, Weissman JL, Kaplan SB. Imaging of a Stafne bone cavity: what MR adds and why a new name is needed. *Am J Neuro-radiol* 1999;20(4):587-9.

30. Dolanmaz D, Etöz OA, Pampu AA, Kılıç E, Sisman Y. Diagnosis of Stafne's bone cavity with dental computerized tomography. *Eur J Gen Med* 2009;6(1):42-5.
31. Oikarinen VJ, Wolf J, Julku M. A stereosialographic study of developmental mandibular bone defects (Stafne's idiopathic bone cavities). *Int J Oral Surg* 1975;4(2):51-4.
32. Apruzzese D, Longoni S. Stafne cyst in an anterior location. *J Oral Maxillofac Surg* 1999; 57(3):333-8.
33. Arijji E, Fujiwara N, Tabata O, Nakayama E, Kanda S, Shiratsuchi Y, et al. Stafne's bone cavity. Classification based on outline and content determined by computed tomography. *Oral Surg Oral Med Oral Pathol* 1993;76(3): 375-80.
34. Grau Cases J, Gay Escoda C, Hernández Al-faro F. [Stafne's cavity. Review and apropos of 6 cases]. *Av Odontostomatol* 1991;7(2):83-7.