

Isaacs' Syndrome with Androgen Insensitivity: Case Report

Androjen İnsensitivitesi Olan Bir Isaacs Sendromu Olgusu

Aslı KÖŞKDERELİOĞLU,^a
Serap MÜLAYİM,^b
Burhanettin ULUDAĞ,^c
Ayhan ZENGİ^d

^aClinic of Neurology,
Bozyaka Training and Research Hospital,
İzmir

^bDepartment of Neurology,
Kocaeli University Faculty of Medicine,
Kocaeli

Departments of
^cNeurology,

^dInternal Medicine,
Endocrine and Metabolism Unit,
Ege University Faculty of Medicine,
İzmir

Geliş Tarihi/Received: 03.07.2013
Kabul Tarihi/Accepted: 26.03.2014

Yazışma Adresi/Correspondence:
Aslı KÖŞKDERELİOĞLU
Bozyaka Training and Research Hospital,
Clinic of Neurology, İzmir,
TÜRKİYE/TURKEY
copura@gmail.com

ABSTRACT Isaacs' syndrome, also known as acquired neuromyotonia, is characterised by hyperexcitability of the motor nerves. This syndrome was first described in 1961 and represents the peripheral nerve hyperexcitability producing muscle stiffness, cramps, fasciculations, myokymia and pseudomyotonia. In idiopathic forms of neuromyotonia, autoantibodies against voltage gated potassium channels are responsible for the pathogenesis. Secondary forms are mostly related with paraneoplastic conditions. Isaacs' syndrome tends to associate with some autoimmune diseases. In this case report, we present a 30 year old male patient with muscle twitching and leg cramps due to Isaacs syndrome. Here, the association of polyneuropathy and acquired neuromyotonia occurrence in a patient with androgen insensitivity and vitiligo is discussed.

Key Words: Isaacs syndrome; vitiligo; infertility; androgen-insensitivity syndrome

ÖZET Edinsel nöromiyotoni olarak da bilinen Isaacs' sendromu, motor sinirlerin hipereksitabilitesi ile karakterizedir. Bu sendrom ilk olarak 1961 yılında tanımlanmıştır ve kas sertliği, kramp, faskülasyonlar, miyokimi ve psödomiyotoniye neden olan periferik sinir hipereksitabilitesini belirtmektedir. İdiyopatik formlarında, voltaj bağımlı potasyum kanal antikorları patogeneze sorumludur. Sekonder formları daha çok paraneoplastik durumlar ile ilişkilidir. Isaacs sendromu bazı otoimmün hastalıklar ile birliktelik gösterme eğilimindedir. Bu olgu sunumunda, Isaacs sendromuna bağlı kas seğirmesi ve bacak krampları olan 30 yaşında bir erkek hastayı bildiriyoruz. Burada, androjen insensitivitesi ve vitiligosu olan hastada polinöropati ve edinsel nöromiyotoni ile ilişkisi tartışılmaktadır.

Anahtar Kelimeler: Isaacs sendromu; vitiligo; infertilite; androjen duyarsızlığı sendromu

Türkiye Klinikleri J Neur 2014;9(3):113-7

Isaacs' syndrome is a rare condition of spontaneous and continuous muscle fiber activity often associated with autoantibodies against voltage gated potassium channels (VGKC). Hyperexcitability of the peripheral nerves results in muscle stiffness, cramps, fasciculations, spasms, myokymia and pseudomyotonia. The electrophysiologic hallmark is the neuromyotonic discharges with spontaneous firing of single motor units as doublet, triplet or multiplet discharges with unregular intervals of 1 to 30 seconds. Autoantibodies against VGKC are strongly implicated in the pathogenesis and neuromyotonia may also be associated with other immune mediated diseases. We report a patient with acquired neuromyotonia presented with

systemic manifestations like vitiligo and endocrine abnormalities. There have been no previous reports regarding neuromyotonia in association with vitiligo and androgen insensitivity syndrome. As neuromyotonia and several autoimmune diseases including vitiligo are frequently together, we suggest that neuromyotonia may also have an autoimmune association with some endocrine abnormalities.

CASE REPORT

In May 2008, a 30-year-old man was referred to our electrophysiology unit for evaluation of leg cramps. Painful muscle cramps and spasms involving both legs and bilateral muscle twitching of the proximal leg muscles were present since childhood. Similar symptoms were present also in his father, but his brothers were asymptomatic. He had impotence and infertility problem that hasn't been evaluated yet.

Physical examination revealed a continuous, painful muscle spasm with cramps affecting both legs and bilaterally twitching of the quadriceps and semitendinosus muscles. Calf hypertrophy and hypopigmented skin lesions on lower extremities and abdominal region were also observed. Hypopigmented areas in his hair were noted.

Neurologic examination showed muscle stiffness and myokymia in gastrocnemius and fasciculations in quadriceps femoris muscles. No muscle weakness was observed. Deep tendon reflexes were decreased. The plantar reflex was flexor. Cerebellar system, cranial nerves and sensory system examinations were normal.

Laboratory blood tests including blood count, serum glucose, blood electrolytes, liver enzymes, creatine kinase, vitamin B12, erythrocyte sedimentation rate, thyroid stimulating hormone, free T3 and T4, anti-T and anti-M antibodies revealed normal results. In addition, anti-nuclear antibody (ANA) and anti-neutrophil cytoplasmic antibodies (ANCA) were negative and anti double stranded DNA (anti-ds DNA) antibody and rheumatoid factor were within normal limits. Tumor markers including carcinoembryonic antigen, alpha-fetoprotein,

free prostatic specific antigen, CA 15-3, CA 19-9 and CA 125 were within normal limits. Protein electrophoresis and serum immunoglobulin levels (Ig G, Ig A, Ig M) were within normal limits. Free testosterone, dihydro epiandrostenadion and cortisol levels in serum were normal. Total testosterone, adrenocorticotrophic hormone, follicle stimulating hormone, luteinizing hormone and prolactin levels were elevated. Serology testing for VGKC antibodies was negative.

Oligoazospermia was noted in sperm analysis whereas abdominal ultrasound and computed tomography (CT) scan of the pelvis were normal. Thyroid Ultrasound, CT scan of the chest and hypophyseal magnetic resonance imaging (MRI) were normal. His electroencephalography testing showed no abnormalities.

Histologic examination of the depigmented area established the absence of melanin using Fontana-Masson stain and the absence of melanocytes in epidermis which demonstrated vitiligo.

Electromyography (EMG) revealed polyphasic motor unit potentials with prolonged latency, short duration and lower amplitudes. Nerve conduction studies showed axonal peripheral neuropathy, the results were shown in Table 1. Conduction block was not detected. Needle EMG showed a few fibrillation potentials and sporadic, spontaneous myokymic discharges in gastrocnemius, anterior tibialis and quadriceps femoris muscles. Several motor units were seen to fire spontaneously and irregularly as doublets, triplets and multiplets (Figure 1). Continuous EMG recordings illustrated varying partial motor unit size occurring with high frequency bursts of neuromyotonia in gastrocnemius and anterior tibialis muscles. Caryotype analysis showed 46 XY genotype. Androgen receptor (AR) gene with 26 CAG repeats was noted. IQ test showed mild mental retardation. The patient was treated with lamotrigine (400 mg/day) and carbamazepine therapy (400 mg/day).

DISCUSSION

We described the consecutive occurrence of acquired neuromyotonia and mild androgen insensi-

TABLE 1: Nerve conduction studies performed on nerves in the right arm and leg.

| Nerve | Normal range | Latency (ms) | Normal range | CMAP (mv) | | NCV (m/s) |
|----------------|--------------|--------------|--------------|-----------------|--------------|-----------|
| | | | | SNAP (μ v) | Normal range | |
| Median motor | ≤ 4.0 | 3,2 | >5.0 | 3 | >50 | 51 |
| Median sensory | $\leq 4,6$ | 2,6 | >10.0 | 7 | >43 | 55 |
| Ulnar motor | $\leq 3,3$ | 2,8 | >5.0 | 2 | >50 | 57 |
| Ulnar sensory | $\leq 4,6$ | 2,3 | >10.0 | 8 | >42 | 52 |
| Peroneal motor | $\leq 5,6$ | 4,2 | >3.0 | 1,5 | >40 | 44 |
| Tibial motor | $\leq 5,1$ | 4,5 | >5.0 | 2 | >40 | 45 |
| Sural sensory | $\leq 4,5$ | 2,7 | >8.0 | 4 | >40 | 48 |

CMAP: Compound muscle action potential; SNAP: Sensory nerve action potential; NCV: Nerve conduction velocity. Normal ranges were taken from our laboratory.

tivity syndrome in a patient with idiopathic axonal polyneuropathy and vitiligo. The rare combination of neuromyotonia and androgen insensitivity syndrome has not been reported in the literature before.

We report a patient with acquired neuromyotonia who had muscle stiffness, cramps and myokymias progressing with muscle twitching on proximal lower extremities that exists since childhood. The patient was admitted to our electrophysiology department suffering from myokymias and cramps. Electrophysiologic studies showed decreased recruitment at maximal muscle contraction. Needle EMG showed neuromyotonic discharges in the lower extremity muscles. Our patient's clinical and electrophysiologic data revealed neuromyotonia with idiopathic subclinical axonal polyneuropathy. Hart reported that nerve conduction studies show evidence of a polyneuropathy in only one third of patients with acquired neuromyotonia.¹ In most cases in the literature, the neuropathy accompanying neuromyotonia was idiopathic, axonal and subclinical.^{2,3} On the other hand, a number of disorders of peripheral nerve including Guillain-Barre syndrome, chronic inflammatory demyelinating polyneuropathy, hereditary sensory and motor neuropathy have been associated with neuromyotonia. We made the differential diagnosis due to neurological examination, history, clinical and electrophysiologic findings in our patient.

Despite clinical and electrophysiologic evidence of neuromyotonia, antibodies against VGKC

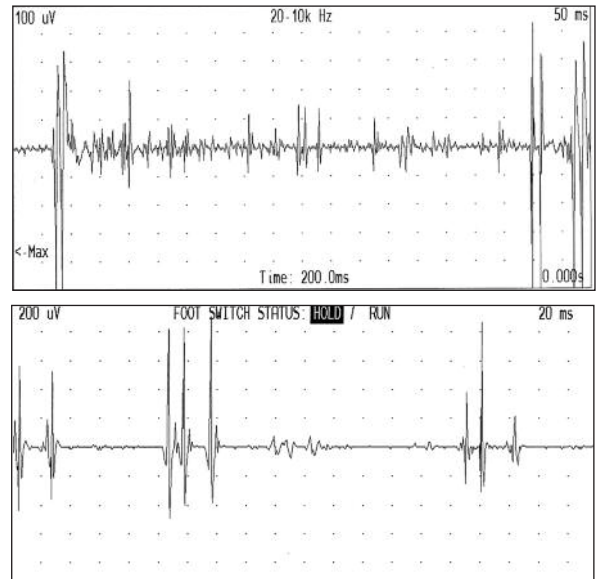


FIGURE 1: Upper trace is a continuous needle EMG recording from right medial gastrocnemius. Below, several different motor units fire spontaneously and irregularly as doublets and triplets.

were negative. It has been suggested that involvement of the immune system in the pathogenesis of acquired neuromyotonia can not be excluded by negative antibody tests.⁴ Moreover, despite of negative testing for VGKC antibodies, acquired neuromyotonia can coexist with axonal neuropathy.²

Skin biopsy from hypopigmented lesions demonstrated vitiligo. He also had piebaldism on his hair. Neuromyotonia associated with vitiligo is present in the literature and there are some case reports presented with localized scleroderma.⁵⁻⁷

Our patient has depressed spermatogenesis without any abnormalities in secondary male sex-

ual characteristics. Mild androgen insensitivity syndrome (MAIS) diagnosis was made due to impaired spermatogenesis, male external genitalia on physical examination with normal karyotype analysis, 46 XY and laboratory findings including elevated testosterone and luteinizing hormone levels. Molecular genetic testing for AR gene in blood revealed no mutations. Gottlieb and coworkers reported that somatic mosaicism of the AR gene mutations could result in mutations present in DNA in genital skin and not in blood.⁸ In addition, they also stated that in some cases with MAIS, only observed abnormality is male infertility.⁹

Although our patient has no mutations in AR gene and presented with neuromyotonia, it is known that Kennedy disease is characterised by CAG repeat expansion in AR gene is accompanying some symptoms of MAIS.¹⁰ Furthermore, CAG repeat expansion may contribute up to 35% of male infertility.¹¹⁻¹³ We suggest that AR dysfunction which appears to be the only observed abnormality in our patient is leading to infertility. AR gene mutations have been related with some cancers whereas neuromyotonia is related with paraneoplastic conditions and immune mediated disorders.¹⁴ Neuromyotonia with autoimmune etiology is frequently associated with myasthenia gravis, vitiligo, diabetes mellitus, peripheral neuropathy, pernicious anaemia, rheumatoid arthritis and Hashimoto's thyroiditis.¹⁵ We searched for possible underlying cancers such as lung cancer, thymoma and hematologic malignancies and immune medi-

ated diseases. First, paraneoplastic conditions were investigated. Tumor markers, protein electrophoresis, serum immunoglobulin levels, serum biochemistry, erythrocyte sedimentation rate analysis, abdominal and thoracic CT examinations were found to be all normal. Secondly, our patient had a negative autoantibody screen including anti-thyroid, ANCA, anti- ds DNA, ANA antibodies and rheumatoid factor, plus serum glucose and thyroid function tests were within normal limits.

A few patients with mental retardation and testicular feminization due to AR gene mutations were reported in the literature.^{16,17} There is one report of three brothers with mental retardation who have the shortest CAG repeat in AR gene.¹⁸

Treatment of neuromyotonia is with anticonvulsant agents such as phenytoin, sodium valproate, lamotrigine and carbamazepine.¹⁵ After we started carbamazepine and lamotrigine in combination, his muscle cramps and spasms improved moderately.

The present case report with acquired neuromyotonia and idiopathic sensorimotor axonal polyneuropathy accompanied with androgen insensitivity syndrome and vitiligo may provide further information about immune system related disorders and endocrine system abnormalities. However, it is still challenging to claim an association between neuromyotonia and endocrine abnormalities without further investigations and studies in the field.

REFERENCES

- Hart IK. Acquired neuromyotonia: a new autoantibody-mediated neuronal potassium channelopathy. *Am J Med Sci* 2000;319(4): 209-16.
- Hart IK, Maddison P, Newsom-Davis J, Vincent A, Mills KR. Phenotypic variants of autoimmune peripheral nerve hyperexcitability. *Brain* 2002;125(Pt 8):1887-95.
- Arimura K, Sonoda Y, Watanabe O, Nagado T, Kurono A, Tomimitsu H, et al. Isaacs' syndrome as a potassium channelopathy of the nerve. *Muscle Nerve Suppl* 2002;11:S558.
- Lahrmann H, Albrecht G, Drlicek M, Oberndorfer S, Urbanits S, Wanschitz J, et al. Acquired neuromyotonia and peripheral neuropathy in a patient with Hodgkin's disease. *Muscle Nerve* 2001;24(6):834-8.
- Kumar A, Jain R, Daga J. Simultaneous occurrence of neuromyotonia and morphea: a cause-effect relationship? *J Neurol Neurosurg Psychiatry* 2006;77(6):802.
- Papadimitriou A, Chroni E, Anastasopoulos I, Avramidis T, Hadjigeorgiou G, Koutroumanidis M. Continuous muscle fiber activity associated with morphea (localized scleroderma). *Neurology* 1998;51(6):1763-4.
- Zivkovic SA, Lacomis D, Medsger TA Jr. Muscle cramps associated with localized scleroderma skin lesions: focal dystonia, neuromyotonia, or nerve entrapment? *J Rheumatol* 2006;33(12):2549.
- Gottlieb B, Beitel LK, Trifiro MA. Somatic mosaicism and variable expressivity. *Trends Genet* 2001;17(2):79-82.
- Gottlieb B, Lombroso R, Beitel LK, Trifiro MA. Molecular pathology of the androgen receptor in male (in)fertility. *Reprod Biomed Online* 2005;10(1):42-8.

10. Gottlieb B, Beitel LK, Wu JH, Trifiro M. The androgen receptor gene mutations database (ARDB): 2004 update. *Hum Mutat* 2004;23(6): 527-33.
11. Tut TG, Ghadessy FJ, Trifiro MA, Pinsky L, Yong EL. Long polyglutamine tracts in the androgen receptor are associated with reduced trans-activation, impaired sperm production, and male infertility. *J Clin Endocrinol Metab* 1997;82(11):3777-82.
12. Yoshida KI, Yano M, Chiba K, Honda M, Kitahara S. CAG repeat length in the androgen receptor gene is enhanced in patients with idiopathic azoospermia. *Urology* 1999;54(6): 1078-81.
13. Mifsud A, Sim CK, Boettger-Tong H, Moreira S, Lamb DJ, Lipshultz LI, et al. Trinucleotide (CAG) repeat polymorphisms in the androgen receptor gene: molecular markers of risk for male infertility. *Fertil Steril* 2001;75(2):275-81.
14. Gottlieb B, Beitel LK, Wu J, Elhaji YA, Trifiro M. Nuclear receptors and disease: androgen receptor. *Essays Biochem* 2004;40:121-36.
15. Maddison P. Neuromyotonia. *Clin Neurophysiol* 2006;117(10):2118-27.
16. Davies HR, Hughes IA, Savage MO, Quigley CA, Trifiro M, Pinsky L, et al. Androgen insensitivity with mental retardation: a contiguous gene syndrome? *J Med Genet* 1997; 34(2):158-60.
17. Gottlieb B, Trifiro M, Lumbroso R, Pinsky L. The androgen receptor gene mutations database. *Nucleic Acids Res* 1997;25(1):158-62.
18. Kooy RF, Reyniers E, Storm K, Vits L, van Velzen D, de Ruiter PE, et al. CAG repeat contraction in the androgen receptor gene in three brothers with mental retardation. *Am J Med Genet* 1999;85(3):209-13.