

Prosthetic Graft Erosion Complicating an Aorto-Duodenal Fistula in a Young Patient with Behçet's Syndrome: Case Report

Behçet Sendromlu Genç Bir Hastada Prostetik Greft Erozyonu ile Gelişen Aorta Duodenal Fistül

Bennur Esen GÜLLÜ, MD,^a
Ahmet Ümit GÜLLÜ, MD,^b
Mehmet ATEŞ, MD^c

Clinics of

^aNephrology,

^bCardiovascular Surgery,
Bursa Yüksek İhtisas Training and
Research Hospital, Bursa

^cClinic of Cardiovascular Surgery,
Şifa Hospital, İzmir

Geliş Tarihi/Received: 10.11.2009

Kabul Tarihi/Accepted: 01.11.2010

*It was presented as a poster at the
10th National Rheumatology Congress,
30 October-03 November 2009, Antalya, Turkey.*

Yazışma Adresi/Correspondence:

Bennur Esen GÜLLÜ, MD
Bursa Yüksek İhtisas Training and
Research Hospital,
Clinic of Nephrology, Bursa,
TÜRKİYE/TURKEY
bennuresen@yahoo.com

ABSTRACT Behçet's Syndrome (BS) is a systemic vasculitis. It is characterized by recurrent oral and genital ulcers, relapsing uveitis, mucocutaneous, articular, neurologic, urogenital, vascular, intestinal and pulmonary manifestations. The exact etiology and pathogenesis of BS are not clear. There is a common belief that the immune-mediated inflammation in BS is a background genetic trait triggered by environmental factors. The cardiovascular manifestations of BS have attracted much attention in recent years since the major arterial and venous lesions occur in 6% to 25% of cases with BS and are the leading cause of death. Arterial complications in this group of patients are rarely seen but usually involve large arteries like the aorta and iliac arteries, and may lead to the perforation of the arterial walls and to the consequential development of aneurysms and their rupture. Morbidity and mortality are high in vascular BS with aortic aneurysm. In this study, we examine a 28 years old male with aorto-duodenal fistula following the reconstruction of an abdominal aortic aneurysm associated with BS. Moreover, we consider what additional steps could have taken to improve the chances of the patient's recovery.

Key Words: Behçet syndrome; vasculitis; aortic diseases; intestinal fistula

ÖZET Behçet Sendromu (BS) sistemik bir vaskülitir. Tekrarlayıcı oral, genital ülser ve üveit, mukokutanöz, artiküler, nörolojik, ürogenital, vasküler, intestinal ve pulmoner bulgularla karakterizedir. BS'nin kesin etiyojisi ve mekanizması net değildir. BS'de immün aracılı inflamasyonun genetik yatkınlığın olduğu bireylerde çevresel faktörlerle tetiklendiğine dair bir inanış vardır. Son zamanlarda BS'nin kardiyovasküler tutulumları dikkat çekmektedir. Olguların %6-25'inde major arteriel ve venöz lezyonlar görülmekte olup bunlar Behçet sendromundaki başlıca ölüm nedenidir. Bu grup hastalarda arteriel komplikasyonlar nadiren görülür, genellikle aorta ve iliak arter gibi büyük arterler tutulur, arteriel duvarda anevrizma gelişimi, anevrizmanın rüptürü ve arteriel duvarda perforasyon ortaya çıkabilir. Vaskülo-Bs'nin morbidite ve mortalitesi hastalığın karakteristik özelliklerinden dolayı yüksektir. Bu çalışmada, BS ile ilişkili abdominal aortik anevrizmanın rekonstrüksiyonundan sonra aorta duodenal fistül gelişen 28 yaşındaki erkek hasta sunulmuştur. Bunun yanında kötü sonuçlanan bu vakada daha fazla neler yapılabileceği irdelenmiştir.

Anahtar Kelimeler: Behçet sendromu; vaskülit; aort hastalıkları; intestinal fistül

Türkiye Klinikleri J Cardiovasc Sci 2011;23(3):283-6

Behçet's Syndrome (BS), originally described in 1937 by Hulusi Behçet is a chronic relapsing rheumatic disease; in which the body's immune system becomes overly reactive and produces unpredictable episodes of inflammation.¹ Although this disease has a worldwide distribution, individuals of Eastern Mediterranean and Japanese descent have the

highest incidence. It tends to develop in the second or third decades of life but can develop at all ages. Diagnosis is based on clinical criteria because as of yet neither pathognomonic laboratory tests nor histological findings specific to BS have been developed.² Recurrent aphthous ulcers of the mouth and genital, uveitis, recurrent hypopyon and a variety of skin lesions, such as erythema nodosum, pustules, acne and hypersensitivity to needle puncture, are the major manifestations of BS.² The cardiovascular manifestations of BS have attracted much attention in recent years. Major arterial and venous lesions occur in 6% to 25% of cases (vasculo-BS) and are the leading cause of death because of its disease characteristics.^{3,4} Large artery involvement occurs in 1.5% to 2.2% of all patients with BS.⁵ Aneurysms, which are more common than occlusions, are a major cause of death because of the risk of rupture.⁶ Both focal arterial thrombosis and aneurysm formation can occur and may coexist in a given patient. Many complications have been recognized but aortitis is one of the most severe.⁷ Surgical therapy of aneurysms has usually been unsuccessful with anastomotic aneurysms and graft occlusions .

CASE REPORT

A 28-year-old male patient admitted to the emergency room presented with severe epigastric pain and two days' history of massive hematemesis. Physical examination demonstrated tender and distended abdomen. He appeared pale, dehydrated with unstable vital signs; blood pressure 86/54 mmHg, temperature 37.2°C and heart rate 122/min, respiration rate 30/min. Hemoglobin and hematocrit levels were 5.3 g/dl, 15.8%, respectively. According to his follow-up files, he was diagnosed with BS when he was 20 years old according to the criteria established in 1990 by The International Study Group for BS.⁸ He had a history of genital ulcers, recurring mouth ulcers, uveitis and abdominal aortic aneurysm (AAA) and undergone to reconstruction of AAA with artificial woven Dacron tube graft seven years ago. For his current problem; he underwent urgent endoscopic evaluation of his upper gastrointestinal system during which an aortic-duodenal fistula between the proximal aortic

anastomotic site of the graft and the second portion of duodenum was noticed. Initially, immediate intra venous blood and colloid replacement treatment were administered to the patient. Diagnosis had been confirmed when duodenum fistulization of the aorta was observed during the operation. The grafted aortic area was dark green due to gall bladder bile contamination (Figure 1). Firstly, the fistulized graft area was repaired and bleeding was controlled. The large fistula resected at the second level of duodenum and gastro-jejunal anastomosis was performed. When peripheral pulseless were observed for both popliteal arteries, a thromboembolotomy procedure was performed to both femoral arteries. At the end of the operation the abdomen was kept open primarily due to edema of bowel but also so that other tissues would avoid compartment syndrome and enable a preferred second-look approach. The patient's bowel was deemed fit for abdominal closure on inspection on the second day of postoperation. He was mobilized after the fifth day of the first intervention. But on the seventh day after the operation, the patient had a sudden cardiac arrest and responded to resuscitation in five minutes. Abdominal distention with increased lactate levels and base excess on blood gas parameters was observed and we undertook a second-look operation to search the cause. Compart-

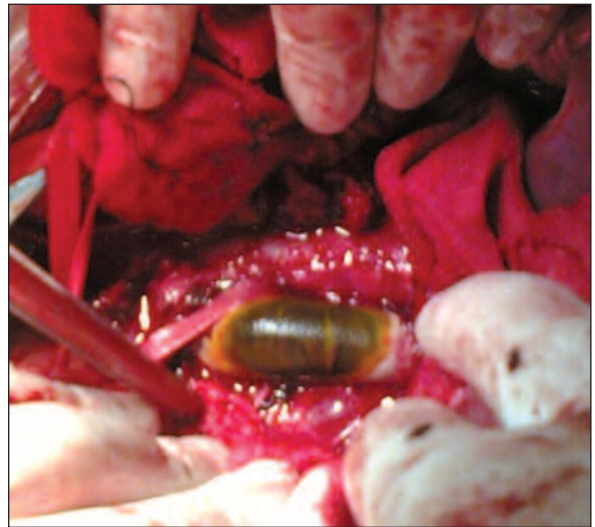


FIGURE 1: Prosthetic graft erosion complicating aorto-duodenal fistula and contamination with bile of gallbladder.

ment syndrome of the bowels was diagnosed and a total colectomy was planned. While tracking the bowels gently during the operation, the sensitive aortic graft ruptured suddenly. Despite extensive efforts to resuscitate the patient, he died on the operating table.

DISCUSSION

BS is a systemic nonspecific vasculitis of all vessel sizes.⁹ Major arterial and venous lesions (vascular BS) occur in 6% to 25% of cases with BS and are the leading cause of death. Large artery involvement occurs in 1.5% to 2.2% of all patients with BS.⁵ Arterial complications in BS are rarely seen and tend to involve large arteries like aorta and iliac arteries, and may lead to the perforation of the arterial walls, aneurysms and their rupture.¹⁰ In cases of arterial BS, it drastically alters the course of the disease and is associated with a poor prognosis. The pathogenesis of aneurysms in BS is quite different from that of atherosclerotic aneurysms. In the affected artery initial active arteritis occurs.⁵ BS can result in fistula formation in the neighboring tissues due to a necrotic process.¹¹ Surgical intervention in the active inflammatory phase is fraught with major difficulties, including suture line dehiscence, pseudoaneurysm formation, aorta-enteric fistula, graft occlusion, and thromboembolic events.¹² Despite the fact that surgical intervention should be postponed until the acute inflammation has calmed; it is not always possible to wait because of the urgency inherent in such situations, such as in our case. While performing the open surgical procedure, it is necessary to avoid selecting the affected area for reconstruction.

Aorto-enteric fistula is another serious complication seen following abdominal aortic reconstruction in patients with BS. In BS abdominal aortic aneurysms that are false, a redundant aneurysmal sac is not available. Also thick fibrotic tissue that surrounds the aorta binds a good closure of the graft with a peritoneum. Tuzun et al. recommends wrapping an omental flap around the graft, which also serves to obliterate the large false aneurysmal space behind the aorta, avoiding dead space problems and avoiding this complication.⁵

In selected emergency cases, endovascular treatment may be an important alternative treatment to surgical procedures. Initial experience suggest that stent-graft insertion may be a safe and effective alternative to surgical treatment for aortic and arterial aneurysms in patients with BS and may result in a complete regression of aneurysms.¹³ In a very recent study, Kim et al. showed 16 patients with vasculo-BS who were treated with endovascular therapy for 20 arterial aneurysm. Their follow-up was 47.6 ± 41.8 months and during this time just 4 complications in 3 patients (3/16, 18.8%) occurred (2 occluded stent-grafts and 2 access site pseudoaneurysm) without any deaths.¹⁴

Further investigation with longer-term follow-up is strongly needed to confirm that the stent-graft is not only an alternative treatment to surgery but also a definitive treatment for aortic and arterial aneurysms in this group of patients. There are still some major concerns regarding long term durability of these devices since endovascular graft replacement have only been performed since the mid 90s and no prosthesis has remained in continuous, unmodified use for long. Complications include: various kinds of endoleaks, migration of the stent-graft, and the fact that more than 20% of patients require re-intervention after a year even in normal histopathological tissue of aorta. Moreover, review of the literature revealed only case reports with short term follow-up but not clinical series in which endovascular treatment modality was used in patients with BS.¹²⁻¹⁴ The long term interaction between the diseased aortic tissue and proximal and distal fixation sites of endovascular graft is still controversial. In our case due to unstable hemodynamic condition and hemorrhagic shock, we transferred the patient directly to the operating room and opened the abdomen in order to control the bleeding.

In conclusion, when we consider the case retrospectively and consider what more could have been done for this young patient, we have the following lessons:

Patients diagnosed with BS should be followed very closely especially if they underwent to vascular intervention.

In the acute phase of the disease, after achieving control of the bleeding and hemodynamic stability during the operation, an endovascular graft could be installed, in place of new surgical sutures.

If endovascular graft replacement is not feasible due to technical impossibility at that mo-

ment, infrarenal wide spread diseased aortic segment could be ligated and extra anatomic bypass procedures at a macroscopically disease free area performed to avoid new vascular complications such as para-anastomotic pseudoaneurysm or a rupture.

REFERENCES

- Doğanavşargil E, Keser G. [Behçet's disease]. *Türkiye Klinikleri J Int Med Sci* 2005; 1(43):80-91.
- Seabrook GR, Towne JB. Non-atherosclerotic cerebrovascular disease. In: Haimovici H, ed. *Vascular Surgery*. 4th ed. Massachusetts: Blackwell Science; 1996. p.968-9.
- Plotkin GR. Cardiac, vascular, renal, and pulmonary features. In: Plotkin GR, Calabro JJ, eds. *Behçet's Disease: A Contemporary Synopsis*. 2nd ed. New York: Futura Publishing; 1988. p.203-38.
- Kuzu MA, Ozaslan C, Kóksoy C, Gürler A, Tüzüner A. Vascular involvement in Behçet's disease: 8-year audit. *World J Surg* 1994;18(6):948-53.
- Tüzün H, Beşirli K, Sayin A, Vural FS, Hamuryudan V, Hizli N, et al. Management of aneurysms in Behçet's syndrome: an analysis of 24 patients. *Surgery* 1997;121(2):150-6.
- Hamza M. Large artery involvement in Behçet's disease. *J Rheumatol* 1987;14(3):554-9.
- Okada K, Eishi K, Takamoto S, Ando M, Kosakai Y, Nakano K, et al. Surgical management of Behçet's aortitis: a report of eight patients. *Ann Thorac Surg* 1997;64(1): 116-9.
- Criteria for diagnosis of Behçet's disease. International Study Group for Behçet's Disease. *Lancet* 1990;335(8697):1078-80.
- Pay S. [Etiology and pathogenesis of Behçet's disease]. *Türkiye Klinikleri J Int Med Sci* 2005;1(25):10-8.
- Koç Y, Güllü I, Akpek G, Akpolat T, Kansu E, Kiraz S, et al. Vascular involvement in Behçet's disease. *J Rheumatol* 1992;19(3):402-10.
- Chung HJ, Goo BC, Lee JH, Bang D, Lee KH, Lee ES, et al. Behçet's disease combined with various types of fistula. *Yonsei Med J* 2005;46(5):625-8.
- Iscan ZH, Vural KM, Bayazit M. Compelling nature of arterial manifestations in Behçet disease. *J Vasc Surg* 2005;41(1):53-8.
- Park JH, Chung JW, Joh JH, Song SY, Shin SJ, Chung KS, et al. Aortic and arterial aneurysms in behçet disease: management with stent-grafts--initial experience. *Radiology* 2001;220(3):745-50.
- Kim WH, Choi D, Kim JS, Ko YG, Jang Y, Shim WH. Effectiveness and safety of endovascular aneurysm treatment in patients with vasculo-Behçet disease. *J Endovasc Ther* 2009;16(5):631-6.