

Hemorrhages Associated with the Use of Anticoagulants Due to COVID-19: Three Case Reports

COVID-19 İlişkili Antikoagülan Kullanımına Bağlı Hemorajiler: Üç Olgu Sunumu

¹ Ekrem GÜNER^a, ² Şengül AYDIN YOLDEMİR^b, ³ Hakan POLAT^a, ⁴ Halil İbrahim İVELİK^c,
⁵ Bekir ARAS^c, ⁶ Habip YILMAZ^d, ⁷ Şebnem İZMİR GÜNER^c

^aDepartment of Urology, University of Health Sciences Dr. Sadi Konuk Training and Research Hospital, İstanbul, Türkiye

^bDepartment of Internal Medicine, University of Health Sciences Cemil Taşcıoğlu City Hospital, İstanbul, Türkiye

^cDepartment of Urology, Kütahya University of Health Sciences Faculty of Medicine, Kütahya, Türkiye

^dİstanbul Provincial Health Directorate, Public Hospitals Services Presidency-1, İstanbul, Türkiye

^eDepartment of Hematology, Memorial Şişli Hospital, İstanbul, Türkiye"

ABSTRACT In the pathogenesis of severe acute respiratory syndrome-coronavirus-2 (SARS-CoV-2) infection, disseminated intravascular coagulation and venous thromboembolism are one of the causes of high morbidity and mortality. Therefore, anticoagulant drugs play an important role in treatment. One of the rare complications of anticoagulant therapy is bleeding in the retroperitoneal space. These hemorrhages require rapid diagnosis and an urgent approach. Retroperitoneal bleeding should be kept in mind among the many complications that develop in patients treated and followed-up due to coronavirus disease-2019 (COVID-19). For this purpose, we present 3 cases who developed spontaneous retroperitoneal bleeding under the treatment of COVID-19 in this article.

Keywords: SARS-CoV-2; COVID-19; retroperitoneal space; hematoma; anticoagulants

ÖZET Şiddetli akut solunum sendromu-koronavirüs-2 [severe acute respiratory syndrome-coronavirus-2 (SARS-CoV-2)] enfeksiyonu patogenezinde yaygın intravasküler pıhtılaşma ve venöz tromboembolizm olgulardaki yüksek morbidite ve mortalite nedenlerinden biridir. Bu nedenle antikoagülan ilaçlar, tedavide önemli bir yer teşkil etmektedir. Antikoagülan tedavinin nadir komplikasyonlarından biri de retroperitoneal alanda kanamalardır. Bu kanamalar, hızlı tanı ve acil yaklaşım gerektirir. Koronavirüs hastalığı-2019 [coronavirus disease-2019 (COVID-19)] nedeni ile tedavi ve takip edilen hastada gelişen birçok komplikasyon arasında retroperitoneal kanama akılda tutulmalıdır. Bu amaçla, COVID-19 tedavisi altında spontan retroperitoneal kanama gelişen 3 olguyu bu makalede sunmaktayız.

Anahtar Kelimeler: SARS-CoV-2; COVID-19; retroperitoneal boşluk; hematoma; antikoagülanlar

Spontaneous rectus sheath and retroperitoneal hematomas are considered complications of therapeutic anticoagulant use. They are rarely seen, but their mortality is high (20%).

Many patients received inpatient treatment during the pandemic due to respiratory failure secondary to coronavirus disease-2019 (COVID-19) pneumonia. Autopsy studies have shown that severe acute respiratory syndrome-coronavirus-2 (SARS-

CoV-2) infection is associated with coagulopathy.¹ Coagulopathy caused by COVID-19 appears to play an important role in the high incidence of thromboembolic events.² Therefore, the use of therapeutic anticoagulants is common in hospitalized patients with COVID-19 pneumonia. Since it is a new viral agent, randomized controlled studies determining the bleeding risks of anticoagulant therapy in addition to antiviral therapy for treating pneumonia are still lack-

Correspondence: Bekir ARAS

Department of Urology, Kütahya University of Health Sciences Faculty of Medicine, Kütahya, Türkiye

E-mail: bekiraras1@gmail.com



Peer review under responsibility of Journal of Reconstructive Urology.

Received: 17 Nov 2021

Received in revised form: 18 Jan 2022

Accepted: 21 Feb 2022

Available online: 02 Mar 2022

2587-0483 / Copyright © 2022 by Türkiye Klinikleri. This is an open access article under the CC BY-NC-ND license (<http://creativecommons.org/licenses/by-nc-nd/4.0/>).

ing. Simultaneously, some researchers suggest that there is an increased risk of bleeding secondary to direct endothelial damage by SARS-CoV-2.¹

We present 3 cases of retroperitoneal hemorrhage, which we think is associated with low molecular weight heparin (LMWH) among patients receiving inpatient treatment of COVID-19 pneumonia. Brief clinical information of the patients is as follows.

CASE REPORTS

CASE 1

A 75-year-old male patient with hypertension (HT), diabetes mellitus, coronary artery disease (CAD), and chronic obstructive pulmonary disease history, was hospitalized for COVID-19 pneumonia and his treatment was started. The COVID-19 reverse transcription-polymerase chain reaction (RT-PCR) test was positive and thorax computed tomography (CT) images were reported as moderate lung involvement. He needed oxygen support. The first laboratory data; ferritin 177 mcg/L (reference range 23-336), procalcitonin 0.2 ng/mL (reference range <0.5), international normalized ratio (INR)=1.05 (reference range 0.8-1.25); activated partial thromboplastin time (aPTT)=26.47 sec (reference range 22.5-31.3); fibrinogen=494 mg/L (reference range 180-350); D-dimer 3.7 mcg/mL (reference range <0.5), and C-reactive protein 147 mg/L (reference range 0.3-10), platelet count $170 \times 10^3 \mu\text{L}$ (reference range $150\text{--}570 \times 10^3 \mu\text{L}$) and hemoglobin (Hgb) 11.6 g/dL (reference range 11.5-17.3 g/dL) were within normal limits and creatinine value was 0.84 mg/dL (reference range was 0.7-1.2).

The patient was started on favipiravir (loading dose of 1,800 mg on day 1, then 400 mg twice a day for 9 days), daily 2×1 g ceftriaxone, $2 \times 6,000$ IU subcutaneous therapeutic dose enoxaparin, and oxygen support with a nasal cannula. Abdominal pain accompanied by severe anemia (Hgb: 7.1 g/dL) developed suddenly 9 days after hospitalization. On CT imaging of the abdomen, “a 17×13 cm hematoma filling the pelvic region anterior to the bladder” was detected (Figure 1). After transfusion of 2 units of red blood cell (pRBC) suspension, the Hgb level increased to 10.5 g/dL. An invasive procedure was performed for the

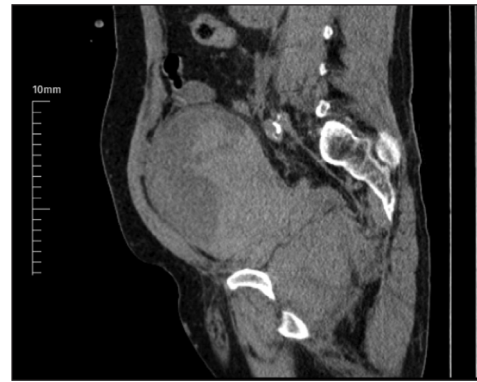


FIGURE 1: Hematoma filling the pelvic region anterior to the bladder on non-contrast abdominal computed tomography.

hematoma by interventional radiologist, but it was observed that the hematoma, which was in an organized structure, could not be aspirated and the patient was followed up closely. In the ultrasonographic examination performed on the patient who applied for follow-up in the following months, it was observed that the mass was largely resorbed. It was learned that the patient had no ongoing acute complaints.

CASE 2

A 59-year-old female patient was hospitalized for COVID-19 pneumonia and her treatment was started. She had a known diagnosis of HT and CAD. COVID-19 RT-PCR test was positive, and diffuse ground-glass densities were seen in both lung parenchyma tissues on the thorax CT. Oxygen demand was high. Her O₂ saturation was 87% on 8 liters per minute of oxygen by nasal cannula and reservoir mask. Due to the sudden onset of cardiac arrhythmia (atrial fibrillation with rapid ventricular response), the patient's general condition deteriorated and O₂ saturation decreased to 67%. She was transferred to the intensive care unit (ICU) for intubation and mechanical ventilation. In reexaminations, 2 units of erythrocyte suspension (pRBC) were transfused to the patient whose Hgb decreased to 8.1 g/dL. CT imaging was performed to detect the sudden onset of anemia and possible bleeding. CT revealed a large hematoma area with an axial dimension of approximately 19×13 cm, filling the pelvic region and the pelvic lateral wall on the left, pushing the uterus and bladder to the right (Figure 2). Interventional radiology suggested that hemorrhagic density changes at different stages

should be observed and followed without any procedure. No complications related to bleeding were observed, Hgb decrease did not continue. The patient died on the 20th day of hospitalization due to acute respiratory failure. Before bleeding, the patient had been treated with a therapeutic dose of LMWH and coagulation tests were normal except for D-dimer elevation (INR=1.1; aPTT=30.3 sec; fibrinogen=798 mg/L; D-dimer=4.2 mg/L, platelet number 286,000/ μ L).

CASE 3

A 65-year-old male patient with a previous diagnosis of CAD, who was hospitalized due to severe respiratory distress, was followed up in the ICU. He was transferred to the COVID-19 unit at the hospital after 5 days of ICU follow-up. On the 15th day of his hospitalization, it was planned to discharge since the treatment of COVID-19 was completed, but due to the continuing need for oxygen use, an oxygen concentrator device installation was organized. While procedures performed to obtain a device at home the patient developed pain in the left thigh.

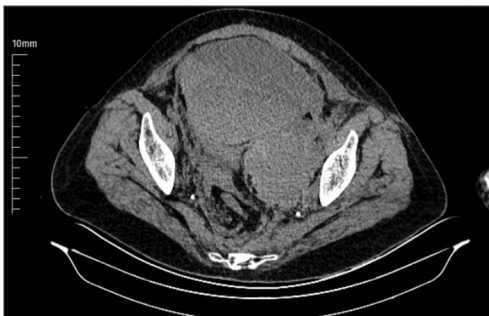


FIGURE 2: Hematoma, 19×13 cm in size, pushing the uterus and bladder to the right in abdominal computed tomography.

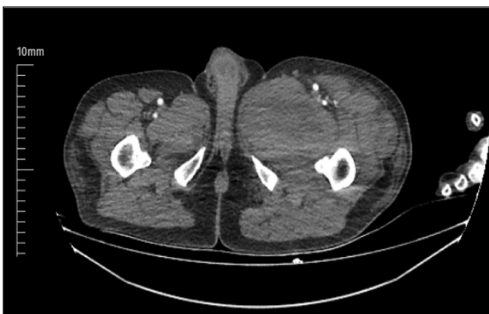

FIGURE 3: Intramuscular hematoma of 90×78 mm between the anterior muscle planes of the left femur.

Doppler ultrasound examination performed for lower extremity artery showed an appearance compatible with a hematoma of approximately 80×75×125 mm in size. Fluid-debris leveling was detected between deep muscle planes near the left femur. Additionally, CT showed a slight heterogeneous intramuscular hematoma of 90×78mm in the widest part between the muscle planes adjacent to the left femur anterior and supported the doppler ultrasound findings (Figure 3). Before the diagnosis of hematoma, the coagulation status was normal (INR=1.0; aPTT=23.2 sec; fibrinogen= 465 mg/L; D-dimer=0.9 mg/L, platelet count 319,000/ μ L). The patient was consult and evaluated for the drainage of the hematoma with the interventional radiology clinic. It was decided that drainage was not required in the patient who did not show extravasation and increase in hematoma size in control imaging. The patient, without a decrease in Hgb due to transfusion during the follow-ups, and with regressed complaints of swelling and bruising was called to the outpatient clinic and discharged. Written informed consent was obtained from all patients. Approval from the Ministry of Health was obtained for this study.

DISCUSSION

Spontaneous retroperitoneal hemorrhage is rare and its mechanism is not fully understood. It occurs due to the rupture of organs or vessels in the retroperitoneal space without a history of trauma or surgery.³ It is thought that the risk factors for spontaneous retroperitoneal hemorrhage are primarily advanced age and the use of therapeutic anticoagulants. Vascular diseases, kidney tumors, hemodialysis, hemophilia and retroperitoneal masses are also considered to be risk factors.⁴ While it may rarely be asymptomatic, there is a wide spectrum of symptoms ranging from acute flank pain, malaise, shortness of breath to cardiovascular collapse and shock.⁵

Microthrombosis events have been proven in the pathophysiology of COVID-19, and concomitant anticoagulant therapy has taken its place in routine therapy to prevent or treat thromboembolic events in patients.⁶ The most frightening complication of anti-

coagulant use is spontaneous bleeding. Spontaneous rectus sheath and retroperitoneal hematomas are rare complications of therapeutic anticoagulation therapy and carry a mortality rate of up to 20%.⁷

In a study involving 400 COVID-19 patients, the overall bleeding rate was 4.8% (7.6% in critically ill patients), and the major bleeding rate was 2.3%.⁸ Some authors have observed that major pulmonary thromboembolic events with pulmonary infarction and/or hemorrhage occurred in 5 of 23 autopsies.⁹ Two of our cases were using high-dose anticoagulants and one of them was using prophylactic anticoagulants. PTT and INR values of all our patients were within the normal range. Additionally, D-dimer was above the normal range at the time of bleeding in all patients. Based on this, we think that our patients are prone to thromboembolic events, not bleeding. Also, when bleeding occurred, patients did not have any bacterial infection or disseminated intravascular coagulation (DIC) sign to support bleeding, except in case 2.

Spontaneous retroperitoneal bleeding occurred with the use of low-dose anticoagulants in some of the previously reported cases, and in another reported case, gastrointestinal system bleeding was observed in an inpatient with COVID-19, but this was not associated with anticoagulant therapy.^{10,11} Another series of 6 cases reported in the literature clearly stated that anticoagulant therapy promoted bleeding events.¹²

The side effects of anticoagulation protocols in COVID-19 patients still seem to be neglected. However, it has been proven that the risk of thromboembolism is still high even after discharge from the

hospital. There is no consensus on how long this treatment should last and how it should be given. Since relationship between COVID-19 sepsis-induced coagulopathy and DIC has not been fully proven, many scientists consider the anticoagulation approach to be uncertain.⁶

It should be kept in mind in terms of possible hemorrhagic problems in COVID-19 patients receiving anticoagulant therapy. Rapid diagnosis, treatment, and close follow-up are critical. Further studies are needed to understand whether COVID-19 is directly related to bleeding.

Source of Finance

During this study, no financial or spiritual support was received neither from any pharmaceutical company that has a direct connection with the research subject, nor from a company that provides or produces medical instruments and materials which may negatively affect the evaluation process of this study.

Conflict of Interest

No conflicts of interest between the authors and / or family members of the scientific and medical committee members or members of the potential conflicts of interest, counseling, expertise, working conditions, share holding and similar situations in any firm.

Authorship Contributions

Idea/Concept: Ekrem Güner, Bekir Aras, Hakan Polat; **Design:** Şengül Aydın Yoldemir; **Control/Supervision:** Ekrem Güner, Bekir Aras; **Data Collection and/or Processing:** Halil İbrahim İvelik; **Analysis and/or Interpretation:** Habip Yılmaz, Şebnem İzmir Güner; **Literature Review:** Habip Yılmaz, Şebnem İzmir Güner; **Writing the Article:** Ekrem Güner, Bekir Aras, Halil İbrahim İvelik; Şengül Aydın Yoldemir; **Critical Review:** Şengül Aydın Yoldemir.

REFERENCES

1. Wichmann D, Sperhake JP, Lütgehetmann M, Steurer S, Edler C, Heinemann A, et al. Autopsy findings and venous thromboembolism in patients with COVID-19: a prospective cohort study. *Ann Intern Med.* 2020;173(4):268-77. [[Crossref](#)] [[PubMed](#)] [[PMC](#)]
2. Wang T, Chen R, Liu C, Liang W, Guan W, Tang R, et al. Attention should be paid to venous thromboembolism prophylaxis in the management of COVID-19. *Lancet Haematol.* 2020;7(5):e362-e3. [[Crossref](#)] [[PubMed](#)] [[PMC](#)]
3. Aydin Yoldemir S, Kibar Akilli I, Bilge M, Canbolat Unlu E, Izmir Guner S, Guner E, et al. COVID-19-associated retroperitoneal hemorrhage: same complication, two different treatment. *Grand J Urol.* 2021;1(3):146-9. [[Crossref](#)]
4. Daskalopoulos G, Karyotis I, Heretis I, Anezinis P, Mavromanolakis E, Delakas D. Spontaneous perirenal hemorrhage: a 10-year experience at our institution. *Int Urol Nephrol.* 2004;36(1):15-9. [[Crossref](#)] [[PubMed](#)]
5. Mrug M, Mishra PV, Lusane HC, Cunningham JM, Alpert MA. Hemothorax and retroperitoneal hematoma after anticoagulation with enoxaparin. *South Med J.* 2002;95(8):936-8. [[Crossref](#)] [[PubMed](#)]
6. Moores LK, Tritschler T, Brosnahan S, Carrier M, Collen JF, Doerschug K, et al. Prevention, diagnosis, and treatment of VTE in patients with coronavirus disease 2019: CHEST guideline and expert panel report. *Chest.* 2020;158(3):1143-63. [[PubMed](#)] [[PMC](#)]
7. González C, Penado S, Llata L, Valero C, Riancho JA. The clinical spectrum of retroperitoneal hematoma in anticoagulated patients. *Medicine (Baltimore).* 2003;82(4):257-62. [[Crossref](#)] [[PubMed](#)]
8. Al-Samkari H, Karp Leaf RS, Dzik WH, Carlson JCT, Fogerty AE, Waheed A, et al. COVID-19 and coagulation: bleeding and thrombotic manifestations of SARS-CoV-2 infection. *Blood.* 2020;136(4):489-500. [[Crossref](#)] [[PubMed](#)] [[PMC](#)]
9. Buja LM, Wolf DA, Zhao B, Akkanti B, McDonald M, Lelenwa L, et al. The emerging spectrum of cardiopulmonary pathology of the coronavirus disease 2019 (COVID-19): Report of 3 autopsies from Houston, Texas, and review of autopsy findings from other United States cities. *Cardiovasc Pathol.* 2020;48:107233. [[Crossref](#)] [[PubMed](#)] [[PMC](#)]
10. Patel I, Akoluk A, Douedi S, Upadhyaya V, Mazahir U, Costanzo E, et al. Life-threatening psoas hematoma due to retroperitoneal hemorrhage in a COVID-19 patient on enoxaparin treated with arterial embolization: a case report. *J Clin Med Res.* 2020;12(7):458-61. [[Crossref](#)] [[PubMed](#)] [[PMC](#)]
11. Conti CB, Henchi S, Coppeta GP, Testa S, Grassia R. Bleeding in COVID-19 severe pneumonia: the other side of abnormal coagulation pattern? *Eur J Intern Med.* 2020;77:147-9. [[Crossref](#)] [[PubMed](#)] [[PMC](#)]
12. Sposato B, Croci L, Di Tomassi M, Puttini C, Olivieri C, Alessandri M, et al. Spontaneous abdominal bleeding associated with SARS-CoV-2 infection: causality or coincidence? *Acta Biomed.* 2021;92(2):e2021199. [[PubMed](#)] [[PMC](#)]