

Submandibular Megalith: Case Report

Submandibuler Megalit

Mehmet Eray KOLSUZ,^a
Emine Şebnem KURŞUN,^a
Erdal ERDEM^b

Departments of
^aDentomaxillofacial Radiology,
^bDentomaxillofacial Surgery,
Ankara University Faculty of Dentistry,
Ankara

Geliş Tarihi/Received: 15.05.2014
Kabul Tarihi/Accepted: 22.10.2014

Yazışma Adresi/Correspondence:
Mehmet Eray KOLSUZ
Ankara University Faculty of Dentistry,
Department of Dentomaxillofacial
Radiology, Ankara,
TÜRKİYE/TURKEY
m_eraaykolsuz@yahoo.com.tr

ABSTRACT Sialolithiasis is the most common pathologic condition affecting the salivary glands. Stones may be seen in any of the salivary glands but mostly seen in submandibular gland and its ducts. Sialoliths larger than 15 mm in length are called giant stones or megaliths and are relatively rare in occurrence. We report such a case in a 56-year-old man who presented with a swelling in the left sublingual and submandibular area. Sialolith was detected by using cone-beam computed tomography and panoramic radiography. The sialolith was removed with intraoral surgical approach and no postoperative complications were noted.

Key Words: Salivary gland calculi; submandibular gland; cone-beam computed tomography

ÖZET Tükürük bezlerini etkileyen en yaygın patoloji tükürük bezi taşlarıdır. Tükürük bezi taşları çoğunlukla submandibuler tükürük bezi ve kanalında görülmekle birlikte, diğer tükürük bezlerinde de görülebilir. 15 mm çapından büyük olan ve nadir olarak görülen tükürük bezi taşları "dev taşlar" ya da "megalit" olarak adlandırılmaktadır. Bu yazıda sol sublingual ve submandibuler bölgede şişlik öyküsü olan 56 yaşındaki erkek hasta rapor edilmiştir. Tükürük bezi taşı konik ışınli bilgisayarlı tomografi ve panoramik radyografi ile tespit edilmiştir. Tükürük bezi taşı ağız içinden cerrahi yaklaşım ile çıkarılmış ve ameliyat sonrası herhangi bir komplikasyon gelişmemiştir.

Anahtar Kelimeler: Tükürük bezi taşı; submandibuler bez; konik ışınli bilgisayarlı tomografi

Türkiye Klinikleri J Dental Sci 2016;22(1):70-4

Sialoliths are calcium-rich crystallized minerals ovoid or round, smooth or rough with a yellowish colour.¹ 80-90% of the sialoliths develops in the submandibular gland, 5-10% develops in the parotid gland, and the remainder in the sublingual and minor salivary glands.² The reasons of the higher occurrence of sialoliths in the submandibular gland are more viscous structure of the saliva, flow against gravity, higher calcium content, existence of longer duct.³

Although sialolith may occur at any age from 6 up to 70 years old, most cases occur under the age of 40 years.^{4,5} It is uncommon in children as only 3% of all sialolithiasis cases occur in paediatric population.¹ Males are affected twice as much as females.^{4,6}

Sialoliths can range in size from a few millimeters to a few centimeters. 88% of salivary stones are less than 10 mm with the majority ranging from 3 mm to 7 mm. Sialoliths are larger than 15 mm in length and 1 g in weight are called “Giant Stones” or “Megaliths” and have been rarely reported (7.6%) in the medical literature.^{1,4,7,8}

A salivary calculus develops by continuous deposition at a rate of approximately 1 to 1.5 mm per year, and it could be hypothesized that it could take at least 10 years to obtain a stone classified as megalith.^{7,9} The ability of a calculus to grow and become a giant sialolith depends mainly on the affected duct’s reaction. When the sialolith is located in a duct able to dilate and to allow a normal secretion of salivary flow around the stone the sialolith might increase in size becoming a giant calculus and remain asymptomatic for a long period.¹⁰

In submandibular duct there are two areas where the duct makes a sharp turn: the first is around the posterior edge of the mylohyoid muscle and the second occurs before the duct empties into the oral cavity. These particular areas are therefore prone to salivary stone formation.¹¹

Submandibular gland calculi have been reported to be radiopaque in 80% and 94.7% of cases.⁴ Diagnosis is generally performed with the aid of panoramic and occlusal radiographs, but tomography, sialography, ultrasound, scintillography, and sialoendoscopy can also be used.³

This case report is deal with a submandibular megalith, its characteristics and surgical approach.

CASE REPORT

A 56-year-old male patient was admitted to Department of Dentomaxillofacial Radiology for swelling in the left sublingual and submandibular area as well as routine check-up and appealing for prosthetic restoration. His intraoral clinical examination revealed that roots of 11, 13, 22, 23, 24, 25, 27, 28, 36 were remained in the alveolar processes and decay was present in teeth 17 and 28. The extraoral and intraoral soft tissue examination included no abnormality. A panoramic radiography revealed large, unilateral, radiopaque mass between

the left mandibular second and third molar’s apical region and hyoid bone. Cephalometric radiography confirmed the cylindrical radiopaque mass (Figure 1). Medical history revealed that the patient was in good health. Patient had no pain and his salivary flow and viscosity of saliva was normal. Cone-beam computed tomography (CBCT) (Planmeca ProMax 3D Proface, Helsinki, Finland) evaluation with multiplanar and 3 dimensional reconstructed images confirmed the existence of megalith. A CBCT scan of mandibular region showed the presence of a rounded radiopaque mass measuring approximately 20 × 30 mm within the Wharton’s left duct (Figure 2 and 3).

The mass was palpable intraorally so a staged transoral sialolithotomy approach was planned and performed after induction of local anesthesia and a cylindrical, hard, yellow 30 mm long specimen was obtained (Figure 4).

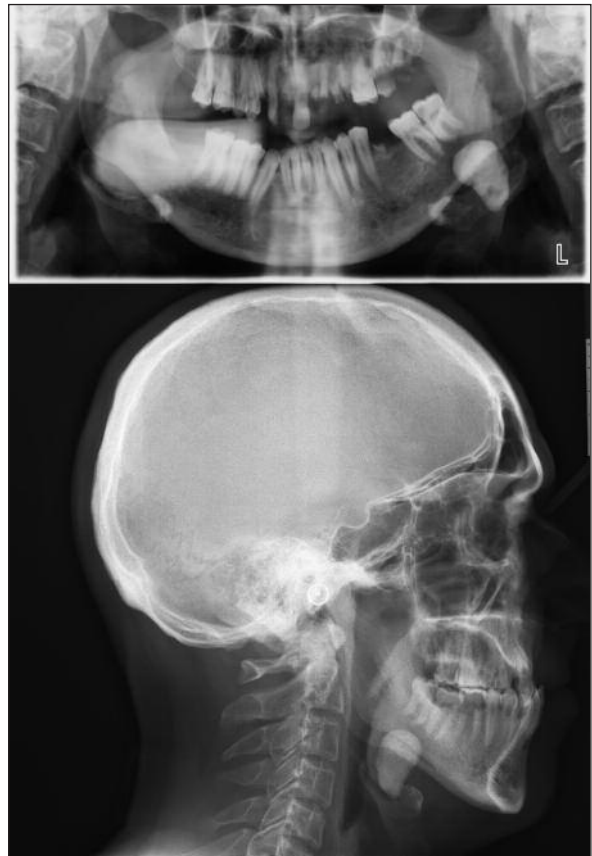


FIGURE 1: Two-dimensional cephalometric and panoramic images showing megalith.

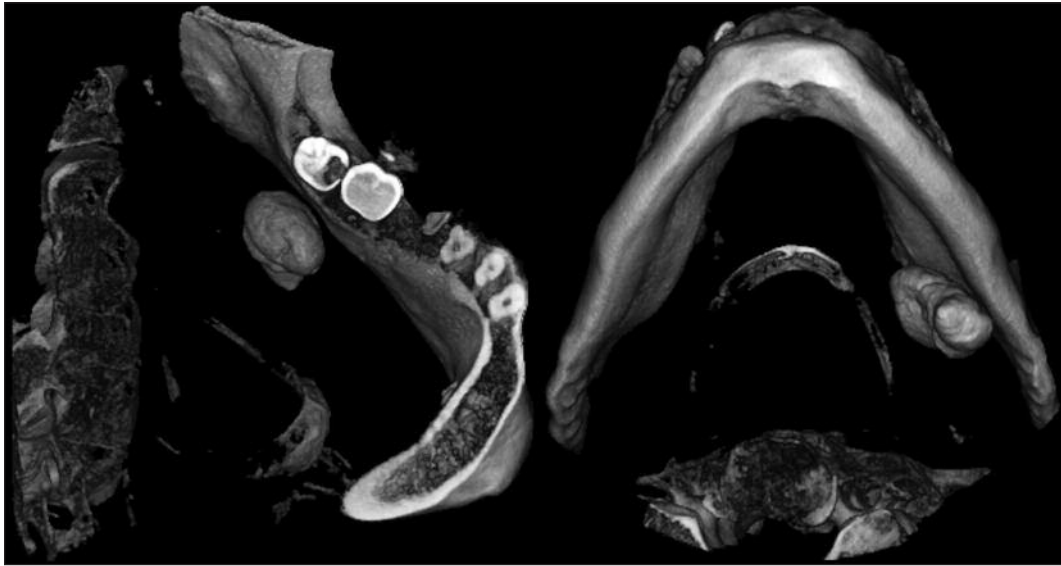

FIGURE 2: Three-dimensional reconstructed cone beam computed tomographic images from different aspects showing submandibular megalith.

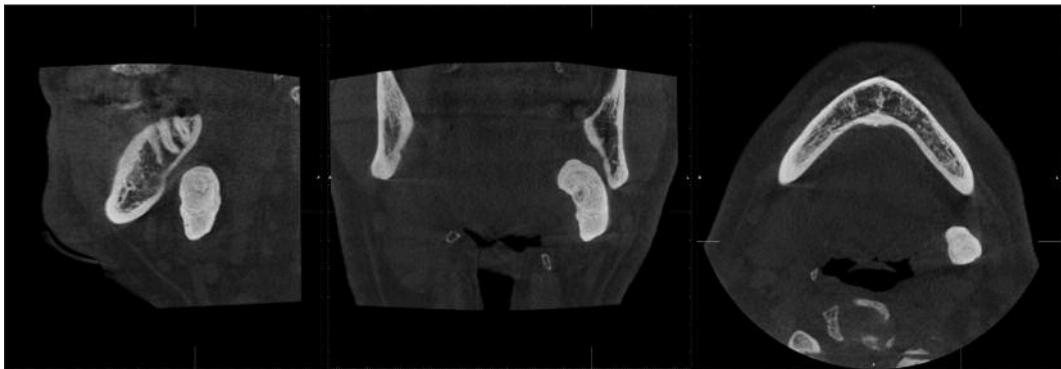


FIGURE 3: Axial, coronal and sagittal views showing submandibular megalith.

The patient was followed-up two weeks post-operatively to check salivary function of the gland.

DISCUSSION

The treatment of choice for sialolith associated with submandibular gland is directly related with its size and location as well as the history of the patient's symptoms. In case of small sialoliths, conservative methods such as proper hydration of the patient, application of moist warm heat and massaging the gland in conjunction with sialogogues may be considered.^{4,6} Submandibular gland removal is indicated only when there is a stone of substantial mass within the gland itself that is not surgically accessible intraorally and when there are small stones

present in the vertical portion of Wharton's duct from the comma area to the hilum.¹⁰ Whenever the stone can be palpated intraorally, it is best to remove it through an intraoral approach.¹² In a recent study carried out by Zhang et al.¹² 85% of patients with a sialolith larger than 10 mm in diameter, removed through intraoral access with the preservation of the gland, remained asymptomatic after a period of 42 months of follow-up. In line with Zhang et al. the megalith of our patient was palpable in the left submandibular area so intraoral approach was planned.¹²

Numerous imaging modalities has been used in the diagnosis of salivary gland stones. In the anterior floor of the mouth, an occlusal radiograph

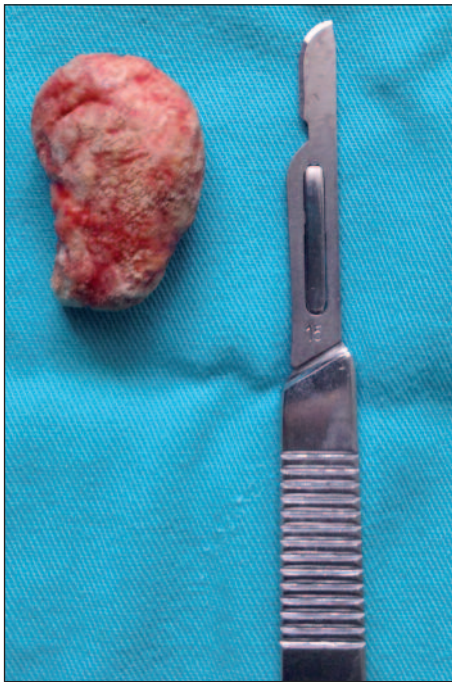

FIGURE 4: Macroscopic view of the 30 mm sized submandibular megalith.

may reveal the calculus. Ultrasonography is widely used the least invasive method and 90% of all stones larger than 2 mm in diameter can be detected as echodense spots on ultrasonography.⁴ Sialoendoscopy has been introduced as a minimally invasive surgical procedure for the diagnosis and treatment of salivary ductal diseases. With the advantages of this new technique, clinicians can visualize the duct lumen and the pathologic features, making the diagnosis according to the endoscopic findings.¹³ By injecting radiopaque dye into salivary glands, orifice sialography can display radiolucent calculi as filling defects. Application of sialography is restricted and contraindicated in acute infectious manifestations. By applying high-resolution imaging protocols with slice thicknesses of 0.2 to 0.5 mm, 3D medical CT can successfully display even the smallest or semicalcified calculi. MRI is reported to be a valuable additional diagnostic method in difficult cases, or when further soft tissue diagnosis is necessary.¹⁴ Dreiseidler et al. stated that diagnostic sensitivity and specificity levels

with CBCT are as high as or higher than those obtained with other diagnostic methods.¹⁴

CBCT is an imaging modality that has recently been used for dentomaxillofacial imaging. When compared with conventional CT scanners, CBCT units possess several advantages including cost-effective, requirement of less space, rapid scan time, limited the beam to the head and neck, low radiation doses. Also, they have interactive display modes that offer maxillofacial imaging and multi-planar reformation, making them more suitable for use in dental practices.¹⁵

As claimed by Soares et al. salivary calculus develops by continuous deposition at a rate of approximately 1 to 1.5 mm per year.⁹ The estimated time of progression in the present case may be approximately 20 to 30 years.

The patient was asymptomatic in this report contrary to other presentations.^{1,4,10} The symptoms referred by the patients during the meal times, are due to the higher stimulation of the salivary secretion and to the duct's obstruction that prevents its smooth flow. When affected by a salivary colic, the patient refers an acute pain, sense of swelling and pressure in the floor of the mouth. Oteri et al. stated that the pain didn't occur in 17% of the giant sialolith cases.¹ Large calculi may perforate the floor of the mouth by ulcerating the duct or may result in a skin fistula by causing a suppurative infection.⁴ Juul and Wagner followed-up retrospectively 42 patients who have submandibular calculi in the floor of the mouth.¹⁶ The mean size of the calculi was 10 mm (range 2-25 mm). Presurgical discomforts consisted of pain alone (14%), swelling alone (36%), or a combination of swelling and pain 47%. In 69% of the patients the discomforts were mealtime related.

As in our case salivary calculi may reach unusual sizes without any clinical symptoms. These structures have to be removed promptly for prevention of possible complications that may occur.

REFERENCES

1. Oteri G, Procopio RM, Cicciù M. Giant salivary gland calculi (GSGC): Report of two cases. *Open Dent J* 2011;5:90-5.
2. Chuangqi Y, Chi Y, Lingyan Z. Sialendoscopic findings in patients with obstructive sialadenitis: long-term experience. *Br J Oral Maxillofac Surg* 2013;51(4):337-41.
3. de Santana Santos T, da Costa Araújo FA, Frota R, Caubi AF, de Oliveira E Silva ED. Intraoral approach for removal of large sialolith in submandibular gland. *J Craniofac Surg* 2012;23(6):1845-7.
4. Singhal A, Singhal P, Ram R, Gupta R. Self-exfoliation of large submandibular stone-report of two cases. *Contemp Clin Dent* 2012;3(Suppl 2):S185-7.
5. Antoniadis D, Mendonidou L, Papanayotou P, Trigonidis G. [Clinical study of sialolithiasis. Findings from 100 cases]. *Hell Stomatol Chron* 1989;33(4):245-51.
6. Leung AK, Choi MC, Wagner GA. Multiple sialoliths and a sialolith of unusual size in the submandibular duct: a case report. *Oral Surg Oral Med Oral Pathol Oral Radiol Endod* 1999;87(3):331-3.
7. Wallace E, Tuzin M, Hagan J, Schaitkin B, Walvekar RR. Management of giant sialoliths: review of the literature and preliminary experience with interventional sialendoscopy. *Laryngoscope* 2010;120(10):1974-8.
8. Rivera-Serrano CM, Schaitkin BM. Bilateral giant submandibular sialoliths and the role for salivary endoscopy. *Am J Otolaryngol* 2011;32(1):85-7.
9. Soares EC, Costa FW, Pessoa RM, Bezerra TP. Giant salivary calculus of the submandibular gland. *Otolaryngol Head Neck Surg* 2009;140(1):128-9.
10. Rai M, Burman R. Giant submandibular sialolith of remarkable size in the comma area of Wharton's duct: a case report. *J Oral Maxillofac Surg* 2009;67(6):1329-32.
11. Baumash HD. Submandibular salivary stones: current management modalities. *J Oral Maxillofac Surg* 2004;62(3):369-78.
12. Zhang L, Escudier M, Brown J, Capaccio P, Pignataro L, McGurk M. Long-term outcome after intraoral removal of large submandibular gland calculi. *Laryngoscope* 2010;120(5):964-6.
13. Su YX, Liao GQ, Zheng GS, Liu HC, Liang YJ, Ou DM. Sialoendoscopically assisted open sialolithectomy for removal of large submandibular hilar calculi. *J Oral Maxillofac Surg* 2010;68(1):68-73.
14. Dreiseidler T, Ritter L, Rothamel D, Neugebauer J, Scheer M, Mischkowski RA. Salivary calculus diagnosis with 3-dimensional cone-beam computed tomography. *Oral Surg Oral Med Oral Pathol Oral Radiol Endod* 2010;110(1):94-100.
15. Kamburoglu K, Kursun S, Akarslan ZZ. Dental students' knowledge and attitudes towards cone beam computed tomography in Turkey. *Dentomaxillofac Radiol* 2011;40(7):439-43.
16. Juul ML, Wagner N. Objective and subjective outcome in 42 patients after treatment of sialolithiasis by transoral incision of Warthon's duct: a retrospective middle-term follow-up study. *Eur Arch Otorhinolaryngol* 2014;271(11):3059-66.