

Effects of Intraoperative Local Mitomycin and 5-Fluorouracil Application on Intraocular Pressure and Wound Healing Process in the Experimental Glaucoma Filtering Surgery in Rabbits

TAVŞANLARDA DENEYSEL FİLTRAN GLOKOM CERRAHİSİNDE İNTRAOPERATİF
LOKAL MİTOMİSİN VE 5- FLOROURASİL UYGULAMASININ GÖZİÇİ BASINCI VE
YARA İYİLEŞME SÜRECİNE ETKİSİ

Ahmet ÖZER*, Nilgün YILDIRIM*, Nevin KURTDERE**, Murat ERÇAKIR***, Firdevs GÜRER***, Reşat Nuri AŞTI**, Sumru YURDAKUL*, Attila TANYOLAÇ**, Hikmet BAŞMAK*

* Department of Ophthalmology, Medical School of Osmangazi University, Eskişehir,

** Department of Histology-Embryology, Veterinary Faculty of Ankara University, Ankara,

*** Department of Histology-Embryology, Medical School of Osmangazi University, Eskişehir, TURKEY

Summary

Purpose: The purpose of this study is to investigate the effects of intraoperative local mitomycin and 5-fluorouracil (5-FU) application on intraocular pressure and the wound healing process in the experimental glaucoma filtering surgery in rabbits.

Methods: Taking 42 eyes of 21 rabbits as a sample the effects of intraoperative local mitomycin and 5-FU application on the intraocular pressure and wound healing process in glaucoma filtering surgery were studied. Mitomycin was applied on 11 and 5-FU on the remaining 10 right eyes. All 21 left eyes served as controls. On the 32nd day after the operation, the eyes of three rabbits from both mitomycin and 5-FU groups; and on the 60th day, all remaining eyes were enucleated for histopathological examination. Ultrastructure evaluation was based on transmission electron microscopy.

Results: Intraocular pressure was found to be significantly lower in all glaucoma filtering surgery groups ($p<0.001$). Mitomycin and 5-FU application further lowered the intraocular pressure as compared to control group ($p<0.01$). While intraocular pressures were lower in the first 5 days in the mitomycin group, the difference between mitomycin and 5-FU groups was not significant after 5 days ($p>0.05$). Bleb formation was significantly higher in the mitomycin and 5-FU groups than the control group ($p<0.01$). There was no difference among groups with respect to their anterior chamber depth, corneal epithelial defects and other complications ($p>0.05$). Histopathologic examination by light and electron microscopy revealed that mitomycin and 5-FU application delayed the wound healing process; and this effect was found to be more marked with the use of mitomycin.

Conclusions: Intraoperative local mitomycin and 5-FU application further lowered the intraocular pressure and delayed the wound healing process.

Key Words: Glaucoma filtering surgery, Mitomycin, 5-fluorouracil, Wound healing

T Klin J Med Res 2001, 19:69-78

Received: Aug. 14, 2000

Correspondence: Ahmet ÖZER

Department of Ophthalmology,
Medical School of Osmangazi University,
Eskişehir, TURKEY

T Klin J Med Res 200J, 19

Özet

Amaç: Bu çalışmada tavşanlarda deneysel filtran glokom cerrahisinde intraoperatif lokal mitomisin ve 5-florourasil (5-FU) uygulamasının göziçi basıncı ve yara iyileşme sürecine etkisi incelendi

Metod: 21 tavşanın 42 gözü örnek olarak alınarak filtran glokom cerrahisinde intraoperatif lokal mitomisin ve 5-FU uygulamasının göziçi basıncı ve yara iyileşme sürecine etkileri araştırıldı. Sağ gözlerin 11'ine mitomisin, 10'una 5-FU uygulandı. Bütün sol gözler kontrol grubu olarak değerlendirildi. Operasyondan sonraki 32. günde mitomisin ve 5-FU grubundan 3'er tavşanın, 60. günde ise diğer tüm tavşanların gözleri histopatolojik çalışma için enükle edildi. Histolojik değerlendirme elektron mikroskopik ağırlıklı olarak yapıldı.

Sonuçlar: Göziçi basıncı filtran glokom cerrahisi uygulanan bütün gruplarda anlamlı düzeyde düşük olarak bulundu ($p<0.001$). Mitomisin ve 5-FU grubunda göziçi başmandaki düşüklük kontrol grubuna göre daha belirgindi ($p<0.01$). Göziçi basıncı mitomisin grubunda ilk 5 gün daha düşükken, 5. günden sonraki günlerde mitomisin ve 5-FU grubu arasında bir fark yoktu ($p>0.05$). Blep oluşumu mitomisin ve 5-FU grubunda kontrol grubundan daha fazlaydı ($p<0.01$). Gruplar arasında ön kamera derinliği, kornea epitel defekti ve diğer komplikasyonlar yönünden bir fark yoktu ($p>0.05$). Işık ve elektron mikroskopla yapılan histopatolojik muayenede mitomisin ve 5-FU grubunda yara iyileşme sürecinde gecikme olduğu ve bu etkinin mitomisin grubunda daha belirgin olduğu görüldü.

Yorum: İntraoperatif lokal mitomisin ve 5-FU uygulaması göziçibasıncını düşürmekte ve yara iyileşme sürecini geciktirmektedir.

Anahtar Kelimeler: Filtran glokom cerrahisi, Mitomisin, 5-florourasil, Yara iyileşmesi

T Klin Araştırma 2001, 19:69-78

Filtration insufficiency is one of the most important postoperative complication of trabeculectomy procedures. The scarring of conjunctiva and Tenon's capsule is the most common cause.(1) The

69

use of antimetabolites to prevent subconjunctival scarring in glaucoma surgery has recently been proposed. It has been shown in clinical trials that postoperative subconjunctival application of 5-fluorouracil (5-FU) and intraoperative application of mitomycin locally on the scleral flap increased the surgical success in high risk patients who went through glaucoma filtering surgery.(2-12)

Use of 5-FU and mitomycin in glaucoma filtering surgery have caused some complications. Intraoperative local application of mitomycin has been reported to cause conjunctivitis, local corneal oedema and corneal epithelial defect.(9-15) More serious complications such as corneal epithelial defects and weakness at the wound site has been associated with the postoperative subconjunctival use of 5-FU.(16-18) Therefore; recently, new trials, like mitomycin, are underway to apply 5-FU locally during trabeculectomy procedure¹⁹⁻²¹

The aim of this study is to investigate the effects of intraoperative local mitomycin and 5-FU on intraoperative pressure and wound healing in glaucoma surgical filtering surgery in rabbits.

Material and Methods

This study was carried out in 42 eyes of 21 albino rabbits in both sexes weighing between 2 and 3 kg. They were divided randomly into two groups: Group I was the mitomycin group and Group II was the 5-FU group. The left eyes of rabbits in both groups formed the control.

Surgical procedure

Surgical procedures were carried out with the help of a binocular loop. General anaesthesia was induced with intraperitoneal injections of Xylazine hydrochloride (Rompun®, Bayer), 10 mg/kg and ketamine hydrochloride (Ketalar®, Eczacıbaşı), 50 mg/kg. A superiorly placed limbal-based conjunctival flap was then raised. Sponges soaked in mitomycin (Mitomycin C®, Kyowa) in a concentration of 0.5 mg/ml and in 5-FU (Fluorouracil®, Roche) in a concentration of 50 mg/ml were placed between the conjunctiva and the sclera in the right eyes of the rabbits in Group I and II, respectively. On the other hand balanced salt solution (BSS Plus®, Alcon) soaked sponges were placed in all left eyes. After waiting for 5 minutes, application sites were

irrigated with BSS Plus solution. Sclerostomy was done with the help of 1.5 mm Eliot's trephine and a peripheral iridectomy was performed through the sclerostomy. The conjunctival incision was closed with 8/0 polygalactine (Vicryl®, Ethicon).

Intraocular pressure measurements

Intraocular pressures were measured using pneumotonometer (Biorad Digilab Modular One Pneumo-Tonometer) after local anaesthesia was applied with Oxibuprocain hydrochloride (Benoxinate® 0.4%, Thilo) preoperatively, on postoperative days 1, 3, 5 and 7, twice weekly for one month and once every week until 2 months.

Biomicroscopical examinations

On days 1, 7, 15, 32 and 60, biomicroscopical examinations were carried out. Bleb appearances, depths of anterior chambers, hyphaemas, epithelial defects with fluorescein, leaks from wounds, corneal pigmentation, corneal haze, pannus, rubeosis and cataract were all noted. Bleb appearances were graded according to the criteria of Kay (22) et al, and anterior chamber depths were evaluated according to the criteria of Stewart (23) et al.

Histological examination

On day 32, three rabbits randomly chosen from both mitomycin and 5-FU groups and killed by intracardiac injection of high dose sodium thiopentone BP (Pentotal® sodium, Abbott). After immediate enucleation of the eyes, corneal and scleral pieces of tissue including the bleb regions were taken vertically for histological examination. For light microscopy (Olympus BH-2), fixation with neutral formaline 10% and paraffin blocking were followed by Haematoxylin and Eosin staining. After pre-fixation with phosphate-buffered glutaraldehyde 2.5%, irrigation with phosphate buffer 0.1 N and post-fixation with phosphate-buffered osmium tetroxide 1% were carried out for electron microscopy (Zeiss EM-9). Blocks from the filtration area were prepared with araldite semi thin sections of 1 micron and stained with Toluidin blue 1% and thin sections were stained with uranyl acetate and lead citrate.

The remaining rabbits were followed up once weekly until the sixtieth day, when their eyes were enucleated and the above mentioned procedures

were applied for examinations under light and electron microscopy.

In the statistical analysis of the data, two-sided analysis of variance, t-test, X²- test and Kruskal Wallis tests were performed.

Results

This study was conducted on three groups of eyes: Mitomycin group, 11 eyes; 5-FU group, 10 eyes; control group, 21 eyes. After the measurements on day 32, the eyes of three rabbits from each of the mitomycin and 5-FU groups were enucleated for histological examination. Because of the decrease in the number of subjects (8 eyes in the mitomycin; 7 eyes in the 5-FU and 15 eyes in the controls), each group was evaluated for their preoperative values, and follow-up measurements for postoperative values until day 32.

Mean intraocular pressure (IOP) values for three groups are shown in Figure 1.

In the comparison of the IOP values of the three groups, there was no difference in the preoperative values ($p>0.05$). For the values of the first 5 days postoperatively, although there was no difference between the 5-FU and control groups and 5-FU and mitomycin ($p>0.05$), values for the mitomycin group were found to be significantly lower

than the control group ($p<0.01$). In the comparison of the IOP values for postoperative days 5-32, values for the mitomycin and 5-FU groups were found to be significantly lower than the control group ($p<0.001$). There was no statistical difference between the mitomycin and 5-FU groups ($p>0.05$).

The IOP values in all three groups measured on postoperative day 32 and were found to be significantly lower than the preoperative values ($p<0.001$). There were no differences among groups themselves ($p>0.05$).

Figure 2 shows the mean IOP values in all three groups measured preoperatively and postoperative day 32 and after.

There was no statistical difference in the preoperative IOP values of mitomycin, 5-FU and control groups. While there was no difference between the mitomycin and 5-FU groups in the measurements postoperative day 32 and after, IOP values of both groups were significantly lower than the control group ($p<0.001$).

The appearances of blebs in three groups on postoperative day 60 were as follows: 7/8 (87.50%) in the mitomycin, 5/7 (71.43%) in the 5-FU and 4/15 (26.67%) in the controls. When the mitomycin and the 5-FU groups were compared in this respect to the controls, the difference was statistically sig-

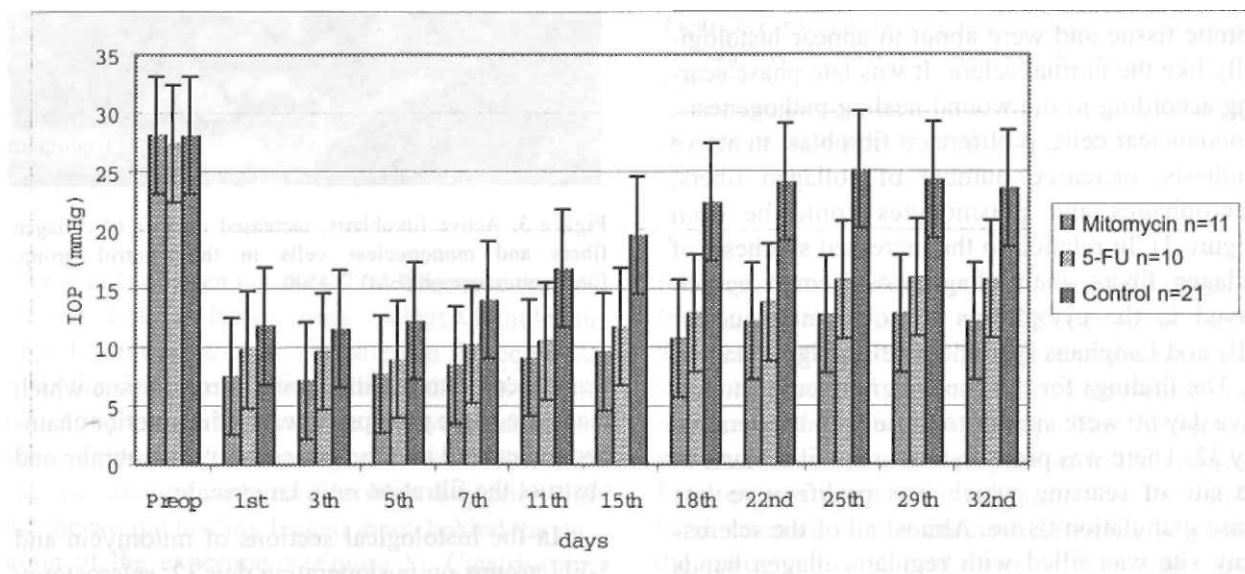


Figure 1. Comparison of intraocular pressure values from preoperative to postoperative day 32 in mitomycin, 5-FU and control groups.

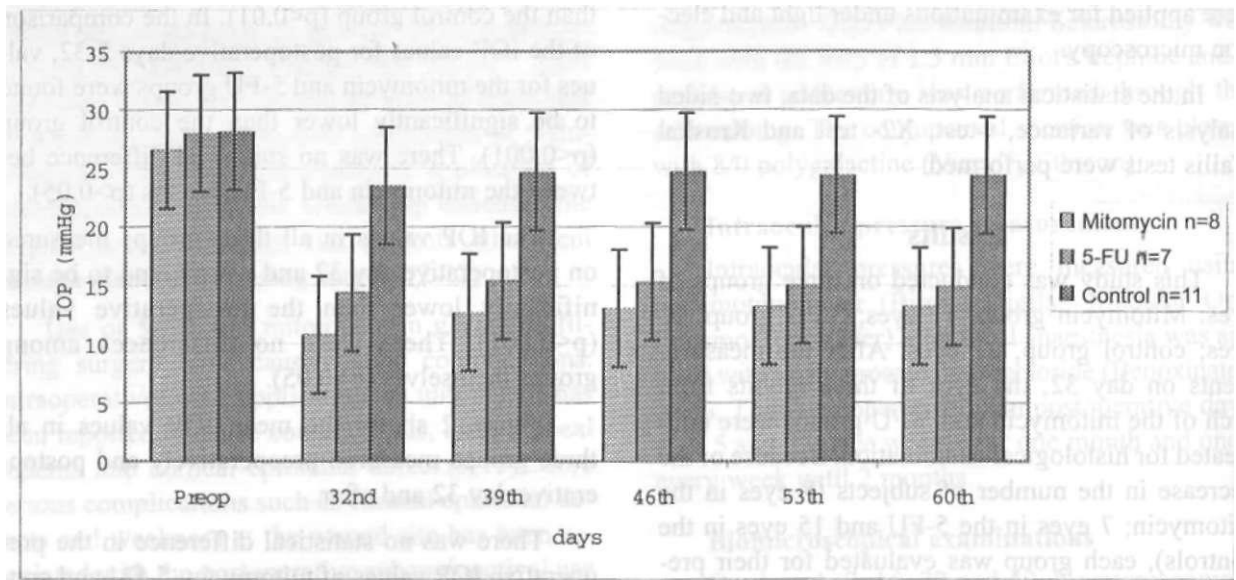


Figure 2. Comparison of the mean IOP values in mitomycin, 5-FU and control groups measured preoperatively, postoperative day 32 and after.

nificant ($p < 0.001$). In the comparison of the mitomycin and the 5-FU groups the difference was not significant ($p > 0.05$).

There were no differences among all three groups in anterior chamber formation, epithelial defects and hyphaema ($p > 0.05$).

In light and electron microscopic examination of sections from the controls on postoperative day 32, the sclerostomy fields were almost filled with fibrotic tissue and were about to appear histologically like the normal sclera. It was late phase scarring according to the wound healing pathogenesis. Mononuclear cells, proliferated fibroblast in active synthesis, increased number of collagen fibers, macrophages and plasmocytes could be seen (Figure 3). In relation to the increased synthesis of collagen fibers, their phagocytosis could be observed in the cytoplasm of some mononuclear cells and Langhans type giant cells (Figure 4a and b). The findings for the control group on postoperative day 60 were similar to those on postoperative day 32. There was proliferation in the fibroblasts in the site of scarring which was proliferative late phase granulation tissue. Almost all of the sclerostomy site was filled with regular collagen bands which gave the area an appearance like that of the normal sclera. In some eyes, the iridocorneal angle

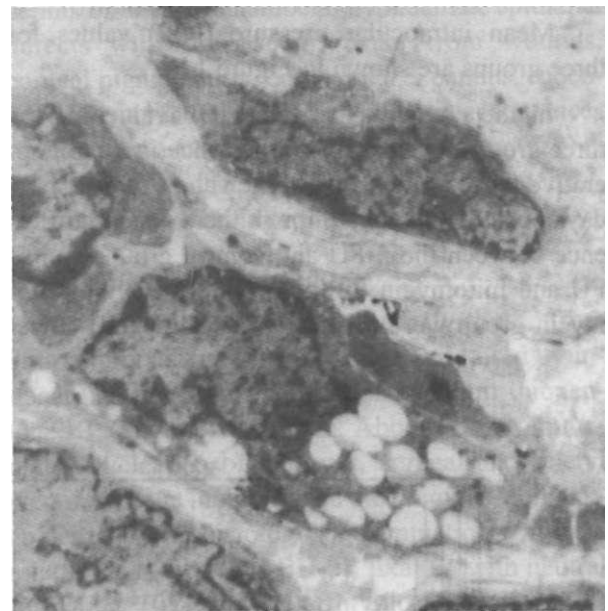

Figure 3. Active fibroblasts, increased number of collagen fibers and mononuclear cells in the control group. Electronmicrograph (EM), X4500.

was observed to be filled with fibrotic tissue which made the angle prolapse towards the anterior chamber and extend into the Descemet's membrane and obstruct the filtration on a large scale.

In the histological sections of mitomycin and 5-FU groups on postoperative day 32, sclerostomy site was seen to be filled with fibrovascular tissue which was not yet formed completely between the

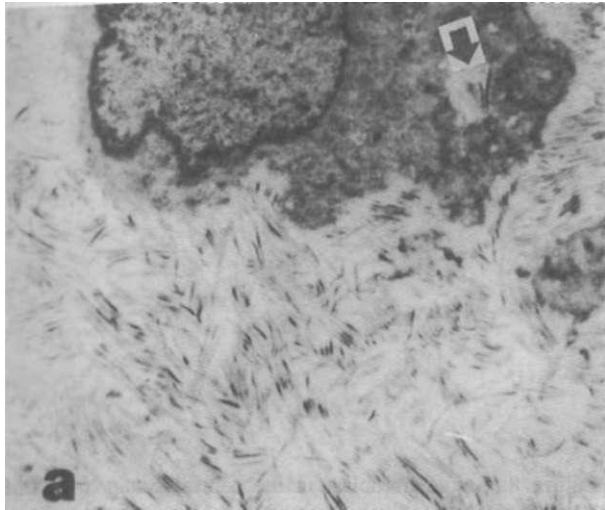


Figure 4. Increased phagocytosis of collagen fibers in the control group. (->)
a. Mononuclear cells, EM X7500

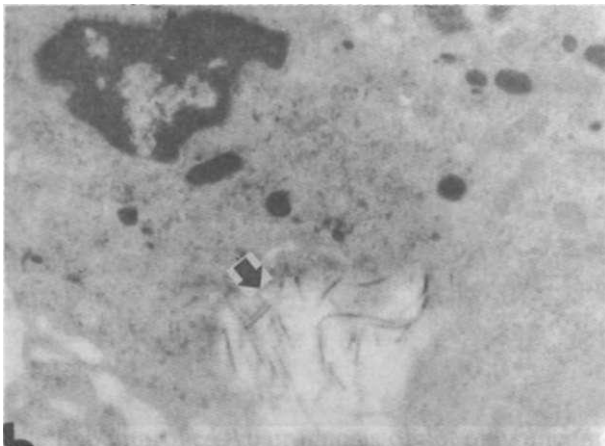


Figure 4. Increased phagocytosis of collagen fibers in the control group. (->)
b. Giant cells of the Langhans type, EM XI9950

scleral and collagen bundles. This fibrovascular tissue was found to have formed collagen bundles in a much thinner area as compared to the controls. From the findings of postoperative day 60, it was interesting to note that both the fibrovascular tissue which filled the sclerostomy site was loose, thin and in a structure with less fibroblast activation and that the wound healing lagged much behind the duration of the experiment (Figure 5). Cicatrisation was even less in some eyes than that seen in control eyes on postoperative day 32. In the comparison of

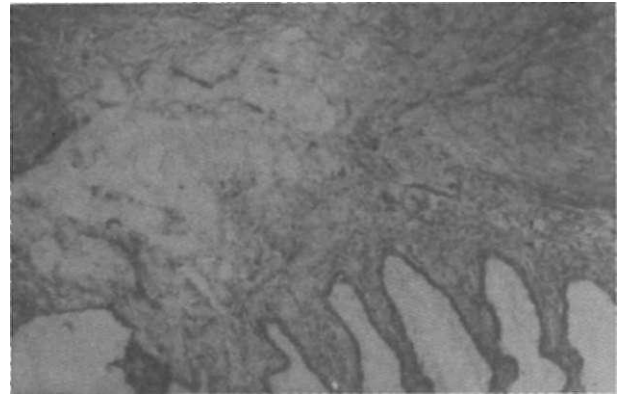


Figure 5. Loose fibrovascular tissue in the sclerostomy site of an eye from the mitomycin group on postop day 60. Hematoxylin Eosin XSO

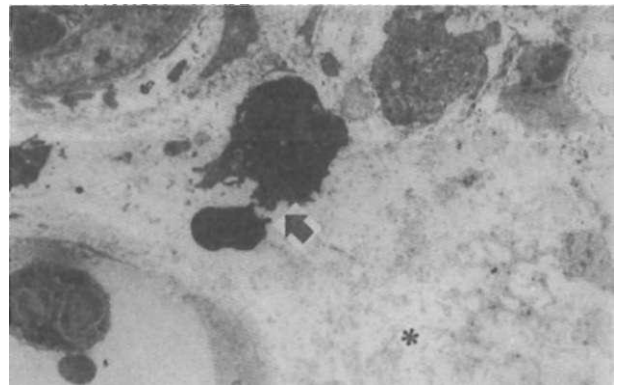


Figure 6. Early wound healing phase in drug treatment groups: Loosely layered, edematous and poor in collagen synthesis cells. (*)
a. Sclerostomy site with neutrophils and ekstravascular erythrocytes in the mitomycin group. (->) EM X2570

mitomycin and 5-FU groups with respect to wound healing, the examination of light microscopic serial sections revealed that the tissue in the filtration site was looser and thinner in the mitomycin group as compared to the 5-FU group. This difference was quite minor in the comparison to the control. Electron microscopic investigation, on the other hand, revealed more prominent difference between the mitomycin and 5-FU groups than that seen through the light microscopy. These two groups (Figure 6a and b) went through a wound healing

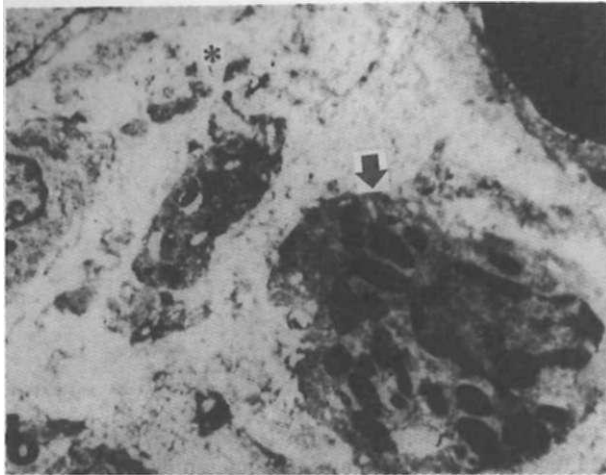


Figure 6. Early wound healing phase in drug treatment groups: Loosely layered, edematous and poor in collagen synthesis cells. (*)
b. Sclerostomy site with eosinophils in the 5-FU group. (->) EM X9900

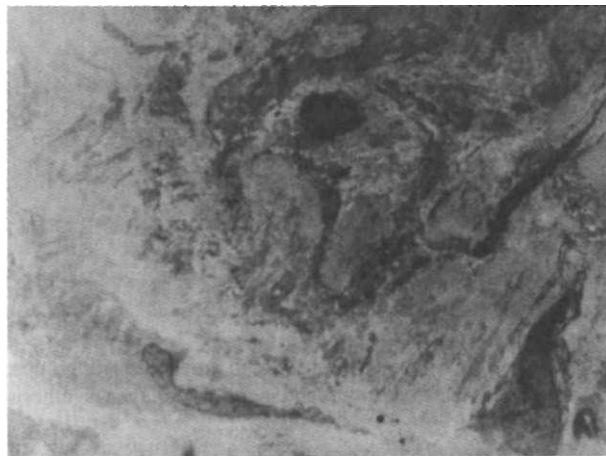


Figure 7. Alignment near to normal scleral structure in the controls. EM X4000

process quite different from the controls. (Figure 7). The healing process was also in a positive way from the prognosis of the filtering surgery point of view. A marked delay in scarring was seen in the drug treated groups. In contrast to active fibroblasts seen in the control group (Figure 8), fibroblasts were mostly inactive and showed no proliferation in drug treatment groups (Figure 9). Cells characteristic of early wound healing phase were observed in drug treatment groups. There were neutrophils in the mitomycin and eosinophils in the 5-FU groups

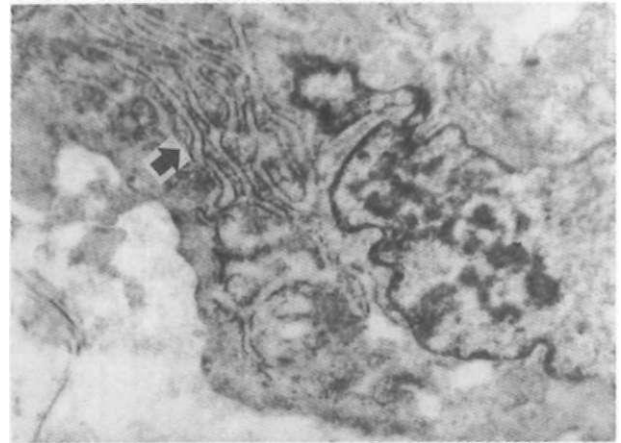


Figure 8. Active fibroblast in the control group. (->) EM X14250

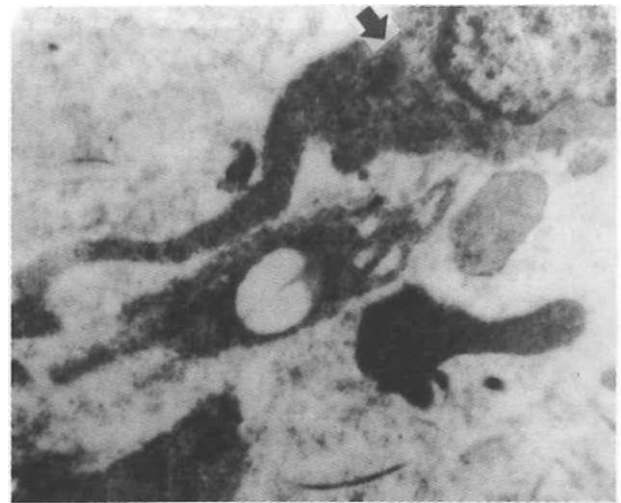


Figure 9. Inactive fibroblast in the drug treated groups. (->) EMX11875

(Figure 6a and b). The most striking ultrastructural difference was that myofibroblasts were seen only in the mitomycin group. These cells were in clumps in cicatrisation sites which were looser and thinner as compared to the 5-FU group (Figure 10a and b).

Discussion

Scar formation in the subconjunctival tissue and the tenon capsule causes filtration failure which by itself is the most important factor affecting the success of the trabeculectomy operations. (1) There are different studies dealing with the

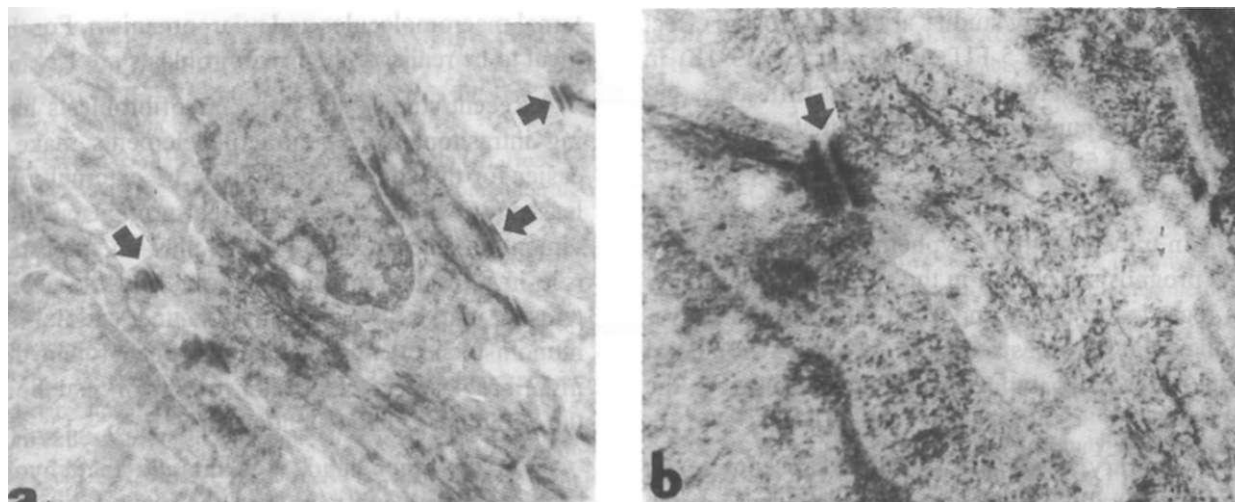


Figure 10. Myofibroblasts seen only in the mitomycin group: Cells with typical indented nuclei, intracytoplasmic contractile elements and forming complexes by binding to each other and with extracellular elements. (->) EM a XI1875 and b X39580

question of how to decrease post trabeculectomy scar formation.(24-29) The post operative subconjunctival 5-FU injection (first trial done by Gressel (30) et al and first true pilot studies done by Heuer (2) et al) has showed an increase in the success rate of the surgery. In the latter studies, the application of 5-FU in complicated and uncomplicated glaucoma patients showed improvement in the prognosis of the operations.(2-8) Because the postoperative subconjunctival application of 5-FU has many serious complications; many other metabolites have recently been studied . According to these studies, intraoperative local applications of mitomycin into the flab improves the prognosis of not only uncomplicated glaucoma but also in completed ones.(9-12) From the complications of 5-FU injections and the good results of the local mitomycin injections we deduced the use of local 5-FU.(19-21)

In this study we were interested in the results of peroperative local use of mitomycin and 5-FU in filtering glaucoma operations. The results of the postoperative follow up of IOP of the three groups showed a significant fall in all the groups. In Figure 1 we notice a fall during the first postoperative week followed by a rise later on , in the IOP, in all three groups .Therefore it has been thought that the post trabeculectomy success is associated with the healing of the wound during first postoperative month. Khaw (21) and Pasquale (31) found that the operations in which mitomycin had been applied

became more successful. In our study we have not seen statistical differences between mitomycin and 5-FU groups, but mitomycin group showed lower IOP than those of control from the first postoperative day on, while the 5-FU group showed lower IOP than that of control group only after the 5th postoperative day. We deduced that the surgical procedure is important in lowering the IOP and the application of mitomycin or 5-FU will enhance that effect.

Presence of the functional filtering bleb during trabeculectomy operation is one of the factors affecting the success of the operation . The filtering flaps have an important rule in the passage of the aqueous humours into the subepithelial field, and in this study, the postoperative blebs in mitomycin, 5-FU and control groups are assessed according to the Kay (22) et al criteria and we noticed that there are statistically important differences in the postoperative blebs in mitomycin and 5-FU groups than that of control groups and that this difference stays for 60 days postoperatively. However we did not find any difference between mitomycin and 5-FU groups , Khaw (21) et al stated that in mitomycin group the difference stays for 30 days .

The anterior chamber depth is assessed according to the Stewards (23) et al criteria, and in all three groups we found shallowness during the first few days which improved after the first week, and there was no difference between the groups .

There are many studies about the erosive effect of mitomycin and 5-FU on the cornea.(13-18) In our study we have not found any difference between the groups and we noticed that a single application of 5-FU decreased the occurrence rate of corneal defects.

In trabeculectomy hypohemia formation effects the prognosis .The clot in the site of the sclerotomy is regarded to be an important factor in the activation of the fibroblasts.(26) In our study, we did not find statistically important differences between the groups.

Contrary to all other surgical procedures , in trabeculectomy , the healing and the closure of the wound is not the aim. Miller (32), in his study, applied filtering glaucoma surgery in rabbit eyes and studied the healing time of the wounds. Zalış (6) et al applied 5-FU after filtering glaucoma surgery and found that, although the opening in the flab is partially closed with fibrovascular tissue , it still remains intact. Our study showed similar results .

In Mandelbaum (33) endophthalmitis the micro-organisms are thought to be able to find access to the eye; though, the flab's field indicate that the weakness at the site of the flab may increase the risk of endophthalmitis. However, endophthalmitis is a serious complication of infiltration surgery. (34-35) In our study, we did not face any endophthalmitis during sixty-day follow up. Heuer (2) et al found that in case of post-operative subconjunctival injection of 5-FU ,41% shows weakness at the site of the conjunctival wound. Seidel test in none of our cases was positive. This indicate that the per-operative application of 5-FU prevents one of its most important complications. However, such an important complication obligates us to be more careful with the use of mitomycin. The absence of myofibroblasts in 5-FU may indicate that they have a function in preventing weakness at the site of the wound.

The success of filtran surgery is barely evaluated on the basis of the delay in the healing process of the wound in sclerostomy area. It is seen in our study, that this expectation has been fulfilled. However, the delay in the healing process would cause weakness at the site and related complications. The ideal is to have a filtration area that releases aqueous humour but forms a barrier for ex-

ternal macromolecules and microorganism. For this ideal to be realised, the myofibroblasts are lacking.

Recent studies show that myofibroblasts having intrasitoplasmic contractile elements make it easier for the aqueous humour to be externally released.(36) It has been found that proteins such as vimentin, spectrin, and F-actin play an important role in releasing aqueous humour, and these proteins be marked in Schlemm's channel endotel immunohistochemically. It has also been found that myofibroblasts in trabecular meshwork supports the Schlemm's channel endotel.(37)

On the other hand, it is thought that myofibroblasts cause contraction in the wound area and make it easier for the aqueous humour to be released in early postoperative phase (between the 7th-14th day).(38) In light of the fact that myofibroblasts were not seen in 5-FU and control group may be the cause for the failure of late filtration. The high filtration caused by the myofibroblasts in the mitomycin group; in addition may lead to bleb leakage and late endophthalmitis.(39-40) Regarding the continuation of filtration, mitomycin is as effective as 5-FU with respect to structural predisposing factors for the complication and the myofibroblasts. We stated that the myofibroblast like cells have an important role in the angiogenesis and the control of the blood flow, and that the increase in the number of the aqueous veins is one of the ways of the postoperative reduction of the IOP.(41-42) Therefore the reduction in the IOP in mitomycin group could be related to the effect of the mitomycin in transforming fibroblasts to myofibroblasts, even though the superiority of mitomycin in the postoperative reduction of IOP is statistically not important.

Mitomycin and 5-FU increases the efficiency and success of glaucoma filtering surgery. Further histopathological studies would explain the success of this filtration in terms of its causes in relation to the transformation evident in myofibroblasts so that the importance and role of these cells is identified.

REFERENCES

1. Mirza GE, Karaküçük S, Doğan H, Erkilic K. Filtering surgery with mitomycin C in uncomplicated (primary open angle) glaucoma. *Acta Ophthalmol* 1994; 72: 155-61.
2. Heuer DK, Parrish II RK, Gressel MG, Hodapp E, Palmberg PF, Anderson RD. 5-fluorouracil and glaucoma filtering surgery: II. A pilot study. *Ophthalmology* 1984; 91: 384-94.

3. Heuer DK, Parrish II RK, Gressel MG, Hodapp E, Desjardins DC, Skuta GL, Palmberg PF, Nevárez JA, Rockwood EJ. 5-fluorouracil and glaucoma filtering surgery. *Ophthalmology* 1986; 93: 1537-46.
4. Rockwood EJ, Parrish II RK, Heuer DK, Skuta GL, Hodapp E, Palmberg PF, Gressel MG, Feuer W. Glaucoma filtering surgery with 5-fluorouracil. *Ophthalmology* 1987; 94: 1071-8.
5. Hennis HL, Stewart WC. The use of 5-fluorouracil in patients following combined trabeculectomy and cataract extraction. *Ophthalmic Surg* 1991; 22: 451-4.
6. Zalish M, Leiba H, Oliver M. Subconjunctival injection of 5-fluorouracil following trabeculectomy for congenital and infantile glaucoma. *Ophthalmic Surg* 1992; 23: 203-5.
7. Jampel HD, Jabs DA, Quigley HA. Trabeculectomy with 5-fluorouracil for adult inflammatory glaucoma. *Am J Ophthalmol* 1990; 109: 168-73.
8. The Fluorouracil Filtering Surgery Study Group. Three-year follow-up of the fluorouracil filtering surgery study. *Am J Ophthalmol* 1993; 115: 82-92.
9. Chen CW, Huang HT, Bair JS, Lee CC. Trabeculectomy with simultaneous topical application of mitomycin-C in refractory glaucoma. *J Ocular Pharmacol* 1990; 6: 175-82.
10. Waheed S, Ritterband DC, Greenfield DS, Liebmann JM, Sidoti PA, Ritch R. Bleb-related ocular infection in children after trabeculectomy with mitomycin C. *Ophthalmology* 1997;104:2117-20.
11. Kitazawa Y, Kawase K, Matsushita H, Minobe M. Trabeculectomy with mitomycin. A comparative study with fluorouracil. *Arch Ophthalmol* 1991; 1109: 1693-8.
12. Kawase K, Matsushita H, Kitazawa Y: Mitomycin-C for trabeculectomy in glaucoma. *Invest Ophthalmol Vis Sei* 1991; 32: 1122.
13. Shin DH, Kim YY, Sheth N, Ren J, Shah M, Kim C, Yang KJ. The role of adjunctive mitomycin C in secondary glaucoma triple procedure as compared to primary glaucoma triple procedure. *Ophthalmology* 1997; 105: 740-5.
14. Kitazawa Y, Suemori-Matsushita H, Yamamoto T, Kawase K. Low-dose and high -dose mitomycin trabeculectomy as an initial surgery in primary open-angle glaucoma. *Ophthalmology* 1993; 100:1624-8.
15. Bergstrom TJ, Wilkinson WS, Skuta GL, Watnick RL, Einer VM. The effects of subconjunctival mitomycin-C on glaucoma filtration surgery in rabbits. *Arch Ophthalmol* 1991;109(12):1725-30.
16. Knapp A, Heuer DK, Stern GA, Driehe WT Jr. Serious corneal complications of glaucoma filtering surgery with postoperative 5-fluorouracil. *Am J Ophthalmol* 1987; 103: 183-7.
17. Capone A Jr, Lance SE, Friend J, Thoft RA. In vivo effects of 5-FU on ocular surface epithelium following corneal wounding. *Invest Ophthalmol Vis Sei* 1987; 28: 1661-7.
18. Lee DA, Hersh P, Kersten D, Melamed S. Complications of subconjunctival 5-fluorouracil following glaucoma filtering surgery. *Ophthalmic Surg* 1987;18:187-90.
19. Dietze PJ, Feldman RM, Gross RL. Intraoperative application of 5-fluorouracil during trabeculectomy. *Ophthalmic Surg* 1992; 23: 662-5.
20. Lachkar Y, Leyland M, Bloom P, Migdal C. Trabeculectomy with intraoperative sponge 5-fluorouracil in Afro-Caribbeans. *Br J Ophthalmol* 1997; 81: 555-8.
21. Khaw PT, Doyle JW, Sherwood MB, Smith MF, McGorray S. Effects of intraoperative 5-fluorouracil or mitomycin C on glaucoma filtration surgery in the rabbit. *Ophthalmology* 1993; 100: 367-72.
22. Kay JS, Fryczkowski AW, Litin BS, Chvapil M, Jones MA, Herschler J. Delivery of antifibroblast agents as adjuncts to filtration surgery- Part II: Delivery of 5-fluorouracil and bleomycin in a collagen implant: Pilot study in the rabbit. *Ophthalmic Surg* 1986; 17: 796-801.
23. Stewart WC, Shields MB: Management of anterior chamber depth after trabeculectomy. *Am J Ophthalmol* 1988; 106: 41-4.
24. Starita RJ, Fellman RL, Spaeth GL, Poryzees EM, Greendge KC, Traverso CE. Short and long-term effects of postoperative corticosteroids on trabeculectomy. *Ophthalmology* 1985; 92: 928-46.
25. Roth SM, Spaeth GL, Starita RJ, Birbillis EM, Steinman WC. The effects of postoperative corticosteroids on trabeculectomy and the clinical course of glaucoma: Five-year follow-up study. *Ophthalmic Surg* 1991; 22:724-9.
26. Giangiacoma J, Dueker DK, Adelstein E. The effect of preoperative subconjunctival triamcinolone administration of glaucoma filtration. I. Trabeculectomy following subconjunctival triamcinolone. *Arch Ophthalmol* 1986; 104: 838-41.
27. Fourman S. Effects of aminopropionitrile on glaucoma filter blebs in rabbits. *Ophthalmic Surg.* 1988; 19:649-652.
28. Khaw PT, Ward S, Grierson I, Rice NSC. Effects of b radiation on proliferating human tenon's capsule fibroblasts. *Br J Ophthalmol* 1991; 75: 580-3.
29. Yablonski M, Masonson HN, El-Sayyad F, Dennis PH, Hargrave S, Coleman DJ. Use of therapeutic ultrasound to restore failed trabeculectomies. *Am J Ophthalmol* 1987; 103:492-6.
30. Gressel MG, Parrish II RK, Folberg R: 5-fluorouracil and glaucoma filtering surgery: I. An animal model. *Ophthalmology* 1984; 91: 378-83.
31. Pasquale LR, Thibault D, Dormon-Pease ME, Quigley HA, Jampel HD. Effect of topical mitomycin-C on glaucoma filtration surgery in monkeys. *Ophthalmology* 1992; 99:14-8.
32. Miller MH, Grierson I, Unger WI, Hitchings RA. Wound healing in an animal model of glaucoma fistulizing surgery in the rabbit. *Ophthalmic Surg* 1989; 20:350-7.
33. Mandelbaum S, Forster RK, Gelender H, Culbertson W. Late onset endophthalmitis associated with filtering blebs. *Ophthalmology* 1985; 92: 964-72.
34. Katz LJ, Cantor LB, Spaeth GL. Complications of surgery in glaucoma. *Ophthalmology* 1985; 92: 959-63.

35. Kangas TA, Greefield DS, Flynn HW, Parrish II RK, Palmberg P. Delayed-onset endophthalmitis associated with conjunctival filtering blebs. *Ophthalmology* 1997; 104: 746-52.
36. Welge Lussen U, Eichhorn M, Bloemendal H, Lutjen-Drcoll E. Classification of human scleral spur cells in monolayer culture. *Eur J Cell Biol* 1998; 75(1):78-84.
37. Hamanaka T, Thomell LE, Bill A. Cytoskeleton and tissue origin in the anterior cynomolgus monkey eye. *Jpn J Ophthalmol* 1997;41(3): 138-49.
38. Reddick R, Merritt JC, Ross G, Avery A, Peiffer RL. Myofibroblasts in filtration operations. *Ann Ophthalmol* 1985;17(3): 200-3.
39. Solomon A, Ticho U, Frucht-Pery J. Late-onset, bleb-associated endophthalmitis following glaucoma filtering surgery with or without antifibrotic agents. *J Ocul Pharmacol Ther* 1999;15(4):283-93.
40. Mandal A K, Prasad K, Naduvilath TJ. Surgical results and complications of mitomycin C-augmented trabeculectomy in refractory developmental glaucoma. *Ophthalmic Surg Lasers* 1999;30(6):473-80.
41. Gabbiani, G, Hirschel BJ, Ryan GB, Statkov PR, Majno G. Granulation tissue as a contractile organ: A study of structure and function. *J Exp Med* 1972; 135:719-34.
42. Hitchins CA, Grierson I, Rahi AH. Contraction of scar tissue in the rabbit vitreous. *Connec Tissue Res* 1986; 15:123-40.