

Incidental Extrabiliary System Lesions Detected by an Open Magnetic Resonance Imaging System During Magnetic Resonance Cholangiopancreatography Examinations

AÇIK MANYETİK REZONANS GÖRÜNTÜLEME CİHAZI İLE GERÇEKLEŞTİRİLEN MANYETİK REZONANS KOLANJİOPANKREATOGRAFİ İNCELEMELER SIRASINDA TANIMLANAN İNSİDENTAL EKSTRABİLİYER LEZYONLAR

Şebnem ÖRGÜÇ, MD,^a Gökhan PEKİNDİL, MD,^a Gülgün YILMAZ OVALI, MD,^a Selim SERTER, MD,^a Murat ÜNLÜ, MD^a

^aDepartment of Radiology, Celal Bayar University Medical Faculty, MANİSA

Abstract

Objective: The purpose of this article is to determine the spectrum and the incidence of incidental extrabiliary lesions detected during magnetic resonance cholangiopancreatography (MRCP) performed with an open magnetic resonance imaging (MRI) system.

Material and Methods: Incidental lesions were retrospectively evaluated in 242 patients who were referred to our department for MRCP examination with suspected pathologies of gallbladder and bile ducts.

Results: A total of 124 incidental lesions in 89 patients were detected. The incidence of incidental extrabiliary system lesions was 36.8% (89/242). Seventeen hepatic cysts, 5 hepatic hemangiomas, 3 hepatic metastasis, 4 chiroctic livers, 1 subcapsular hematoma of the liver, 3 hepatomegalies, 3 splenomegalies, 8 vertebral hemangiomas, 3 vertebral metastases, 1 discitis, 1 pseudomeningocele, 27 renal cysts, 2 renal atrophies, 2 hydronephrosis, 1 horseshoe kidney, 13 intraabdominal free fluid, 2 pleural effusions, 9 acute and 1 chronic pancreatitis, 2 pancreatic pseudocysts, 1 carcinoma of pancreatic corpus, 2 surrenal adenomas, 6 intraabdominal lymphaderomegalies (LAMs) 2 gastric carcinomas, 4 hydatid cysts (3 hepatic, 1 at the lung base) were determined.

Conclusion: Many incidental pathologies of the adjacent organs are detected during MRCP examinations of the gallbladder and bile ducts. Lesion detection and characterization is improved when MIP images are evaluated together with TSE axial slices and source images. Since clinically significant extrabiliary lesion detection may improve the management of several cases, the radiologist must also focus on the incidental findings during the interpretation of MRCP examinations.

Key Words: Cholangiopancreatography, magnetic resonance, magnetic resonance imaging

Türkiye Klinikleri J Med Sci 2006, 26:385-389

Geliş Tarihi/Received: 21.02.2006

Kabul Tarihi/Accepted: 25.05.2006

Yazışma Adresi/Correspondence: Şebnem ÖRGÜÇ, MD
Celal Bayar University Medical Faculty,
Department of Radiology, MANİSA
sebnemorguc@superonline.com

Copyright © 2006 by Türkiye Klinikleri

Türkiye Klinikleri J Med Sci 2006, 26

Özet

Amaç: Kliniğimizde açık MR sistemi ile manyetik rezonans kolanjiopankreatografi (MRKP) tetkiki uygulanan olgularda insidental olarak tanımlanabilecek bulguları ve bunların sıklığını belirlemeyi amaçladık.

Gereç ve Yöntemler: Kliniğimizde safra kesesi ve yollarına ait hastalık kuşkusu nedeniyle MRKP incelemesi yapılan 242 olguda tanımlanan insidental bulgular retrospektif olarak değerlendirildi.

Bulgular: Seksen dokuz olguda toplam 124 insidental lezyon saptandı. İnsidental ekstrabilyer sistem lezyonlarının insidansı %36.8 olarak hesaplandı (89/242). On yedi karaciğer kisti, 5 karaciğer hemanjiomu, 3 metastatik karaciğer, 4 sirotik karaciğer, 1 karaciğerde subkapsüler hematom, 3 hepatomegali, 3 splenomegali, 8 vertebra hemanjiomu, 3 vertebra metastazi, 1 diskrit, 1 psödomeningosel, 2 sürrenal adenomu, 27 böbrek kisti, 2 atrofik böbrek, 2 hidronefroz, 1 atnalı böbrek, 13 batın içi serbest sıvı, 2 plevral efüzyon, 9 akut ve 1 kronik pankreatit, 2 pankreatik psödokist, 1 pankreas korpus kanseri, 6 intraabdominal lenfadenopati (LAB), 2 mide kanseri, 4 kist hidatik olgusu (3 karaciğer, 1 akciğer bazali) tanımlandı.

Sonuç: MRKP incelemesi sırasında safra kesesi ve yollarının yanı sıra, sıklıkla komşu organlara ait patolojiler de görüntülenebilmektedir. MIP görüntüleri, kaynak imajlar ve TSE aksiyel kesitler ile birlikte değerlendirildiğinde lezyon saptama ve karakterizasyonu daha doğru olarak yapılabilmektedir. Klinik olarak anlamlı insidental lezyonların saptanması olguların yönlendirilmesinde etkin olabileceğinden, MRKP incelemelerin yorumlanması sırasında, radyolog insidental lezyonlara da dikkat çekmelidir.

Anahtar Kelimeler: Manyetik rezonans kolanjiopankreatografi, manyetik rezonans görüntüleme

MRCP is assuming a larger role as a rapid, accurate and non-invasive method of evaluating pancreaticobiliary disease. As the quality of MRCP examinations improved, the interest of radiologists and clinicians in its

clinical applications grew and the number of MRCP examinations performed increased. Special imaging sequences that are heavily-T2-weighted are utilized to depict the biliary tract, pancreatic duct and gallbladder as high signal intensity or bright structures owing to the fluid within them. During the MRCP examinations other structures, as expected mostly with high fluid content are also incidentally imaged. Furthermore many lesions with low or intermediate T2 signal may also be observed when maximum intensity projection (MIP) images are interpreted together with the axial and source images. All these factors increase the number of lesions that have to be identified by the radiologist when reporting MRCP examinations.

The aim of this study was to determine the spectrum and the incidence of incidental lesions detected during MRCP since there is no previous report focusing on this subject.

Materials and Method

Incidental lesions were retrospectively evaluated in 242 patients who were referred to our department for MRCP examination with suspected pathologies of gallbladder and bile ducts between January 1999 and July 2004. Since the study was designed as a retrospective evaluation of the MRCP examinations, which were previously performed in our department, no written consent of patients or ethical committee approval was obtained. No medication or patient preparation was used other than fasting overnight. Examinations were performed with an open MRI system (Gyroscan, 0.23T, Philips Medical Systems, The Netherlands) using axial TSE 7900/200 (other imaging parameters: FA: 90 deg, field of view of 38 cm, scan time of 3 minutes and 10 seconds, slice thickness of 8-10 mm, matrix 256 x 256) and multiplanar (axial, coronal and coronal oblique parallel to the left portal vein) -multislice breath-hold TSE 18000/160 (other imaging parameters: FA: 90 deg, field of view of 38 cm, scan time 19 seconds, slice thickness of 6-7 mm, matrix 160 x 160) sequences. Three-dimensional (3D) inversion recovery se-

quence was used to create 3D reconstructions of the bile ducts with MIP algorithm generating 15-20 coronal-sagittal composite views with 180 degrees of rotation around the cranio-caudal axis.

Results

Eighty-nine MRCP examinations yielded 124 incidental findings. The incidence of incidental extrabiliary system lesions was 36.8% (89/242). Seventeen hepatic cysts (Figure 1 A, B), 5 hepatic hemangiomas, 3 hepatic metastases, 4 cirrhotic livers, 1 subcapsular hematoma of the liver, 3 hepatomegalies, 3 splenomegalies, 8 vertebral hemangiomas, 3 vertebral metastases, 1 pseudomeningocele (Figure 2 A, B) 1 discitis, 27 renal cysts, 2 renal atrophies, 2 hydronephrosis (Figure 3 A, B), 1 horseshoe kidney, 13 intraabdominal free fluid, 2 pleural effusions (Figure 1 A, B), 9 acute pancreatitis, 1 chronic pancreatitis, 2 pancreatic

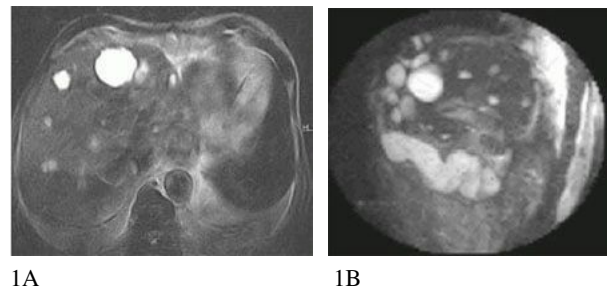


Figure 1 A, B. Multiple hepatic cysts and pleural effusion. Axial FSE T2 (1A) and MIP (1B) images. Note that the cysts are better localized on axial images, although the pleural effusion can also be diagnosed in MIP images.

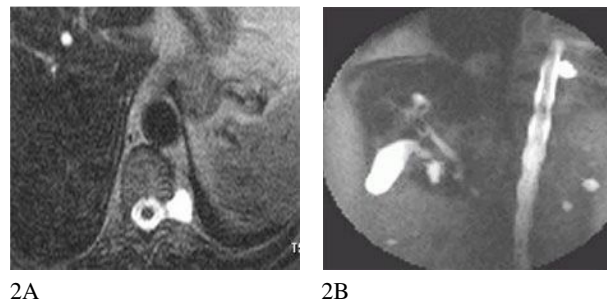
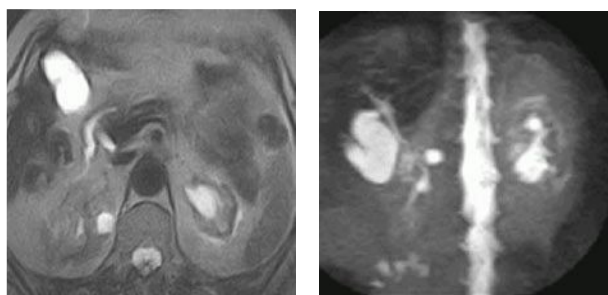


Figure 2 A, B. Incidental spinal lesions detected during MRCP. Figure 3 A, B: Pseudomeningocele. Axial FSE T2 (2A) and MIP (2B) images are both diagnostic for the cystic lesion in conjunction with the spinal canal.

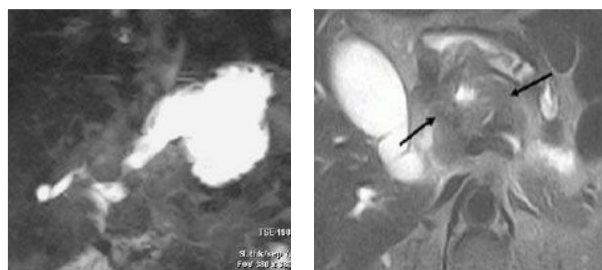


3A

3B

Figure 3 A, B. Axial FSE T2 (3A) and MIP (3B) images. It is easier to localize the right sided renal cyst on the axial images. Left atrophic kidney with hydronephrosis and pararenal edema are depicted on both images.

pseudocysts, 1 carcinoma of pancreatic corpus, 2 surrenal adenomas, 6 intraabdominal LAMs, 2 gastric carcinomas (Figure 4 A, B), 4 hydatid cysts (3 hepatic, 1 at the lung base), 1 abdominal aortic aneurysm were determined in 89 patients. There was more than one incidental lesion in 31 patients. MRCP was within normal limits in 40 (45%) of these incidental lesions and pathological in 49 (55%). A hundred and five MRCP examinations were positive for biliary system lesions in 153 patients where no incidental lesion was found (69%). Fifty-one cystic lesions located in liver, kidneys, pancreas and lung were more precisely located in axial images even though they could all be depicted in MIP images. Solid lesions, namely hepatic metastases, chirrotoic livers, atrophic kidneys, horseshoe kidney, carcinoma of the pancreas, surrenal adenomas, intraabdominal LAMs all had intermediate signal on axial heavily T2 weighted images. Depiction of these lesions on MIP images was almost impossible and all of the solid and vascular lesions were only detected on axial images, except the antral carcinoma with dilatation of stomach, which produced an MIP image similar to an upper gastrointestinal series. Vertebral and hepatic hemangiomas and discitis had high T2 signal on axial images, but since they were not cystic in nature they could not be detected by MIP images. Axial and source images were more informative for both biliary and incidental extrabiliary lesions in patients with ascitis and pancreatitis due to the superposition of fluid intensity in MIP images).



4A

4B

Figure 4 A, B. Two cases of gastric carcinoma: Antral carcinoma depicted on the MIP image (4A) by dilatation of the gastric lumen and shoulder sign formed by the antral mass lesion. It is easier to diagnose the gastric carcinoma and regional LAM on axial slices (4B).

Fifty-two lesions, namely the hepatic and vertebral metastasis, chirrotoic livers, subcapsular hematoma of the liver, organomegalies, discitis, surrenal adenomas, renal atrophies, hydronephrosis, intraabdominal free fluids, pleural effusions, carcinoma of pancreatic corpus, intraabdominal LAMs, gastric carcinomas, hydatid cysts and the aortic aneurysm were all irrelevant findings detected on MRCP examinations, which had an impact on the clinical management of the patients. Although some of these findings were known prior to MR examination several were detected during the MRCP study. All incidental findings were confirmed by clinical, laboratory findings or on other imaging modalities.

Discussion

MRCP represents a relatively new development in MR technology that is assuming a larger role as a rapid, accurate and non-invasive alternative to diagnostic endoscopic retrograde cholangiopancreatography (ERCP) for evaluation of the biliary tree, pancreatic duct and gallbladder. MRCP has evolved rapidly since Waller et al introduced the T2 weighted gradient echo technique for imaging dilated biliary ducts in 1991.¹ Fast scanning techniques, particularly half-Fourier fast spin-echo techniques allow scans within short breath-holds. Rapid acquisition with relaxation enhancement (RARE) sequence is based on fast spin echo (FSE) imaging and has a high spatial

resolution. Half-Fourier RARE sequences like half-Fourier acquisition single-shot fast-spin echo (HASTE) and single shot fast spin echo (SSFSE) allow imaging times of less than 2 seconds and eliminate respiratory motion.^{2,3} Post-processing techniques such as MIP algorithms are applied to the data to generate three-dimensional images.

Currently a number of heavily T2-weighted sequences, which produce high signals from the bile while suppressing the background signal are used in MRI of the biliary tree. These techniques produce images with bright bile, with little or no signal from the soft tissues, moving fluid and blood which have much shorter T2 times. A selective display of liquids is obtained on heavily T2-weighted pulse sequences when echo times exceed relaxation times of surrounding tissues (between 50 and 100 msec in upper abdomen) by a factor of at least 5.⁴ Static fluids other than the bile, with high T2 signals are also imaged during MRCP examinations. Although this inevitable phenomenon sometimes results in degrading of MRCP images due to superimpositions, from time to time it may yield incidental findings.

In our department, MRCP is usually not performed in conjunction with conventional MRI of the abdomen, which permits further evaluation of the solid organs of the abdomen in addition to the biliary tract, pancreatic duct and gallbladder. Although MRCP is highly specific and sensitive in demonstrating biliary dilation, calculi, strictures and anatomical variants, it is not used for characterizing other abdominal pathologies and from time to time radiologists may have to deal with findings unrelated to the biliary system while interpreting the images.³⁻⁵ Lesions easily recognized in axial sequences, and source images may cause a diagnostic problem in MIP images due to superimpositions and lack of anatomical landmarks. Because of the statistical nature of the MIP method, there is loss of information in the final images, a well known phenomenon previously reported for MR angiograms.⁶ As in MR angiography, for proper interpretation of incidental lesions in MRCP examinations it is important to review the single

source images in conjunction with the MIP images.^{6,7} Lesions with short T2 relaxation times (abdominal aort aneurysms, organomegalies, solid mass lesions etc.) are usually only detected in heavily T2 weighted source images and axial sequences accompanying MRCP examinations.

MRCP, which produces diagnostic images of the biliary tree non-invasively, without using any contrast medium or ionizing radiation and without the added risk of pancreatitis, sedation, and perforation, is being increasingly used in the clinical applications and has replaced diagnostic procedures such as percutaneous transhepatic cholangiography (PTC) and ERCP, reserving these invasive techniques with high spatial resolution for problem cases and therapeutic interventions.⁸ Detecting incidental lesions with long T2 relaxation times is another property of MRCP which is quite different than PTC and ERCP. With the absence of adverse effects and relative operator independence, the number of MRCP examinations performed increases and consequently more incidental lesions are discovered. While some of these lesions may be insignificant (e.g. simple renal cysts), some may interfere with the management of the patient (e.g. pancreatitis, sirossis, metastases). Therefore we believe that MRCP examinations should be thoroughly searched for incidental findings and appropriately reported.

Low magnet strength was the major limitation of our study. Nevertheless, we wanted to share our experience on a 0.23T open system, which supplied a considerable amount of useful information on the management of patients and had the advantage of imaging claustrophobic patients. Since it is well known that high power magnetic field has many advantages in the imaging of biliary system and its pathologies, it is most likely that more lesions in a wider spectrum may be detected and characterized to a better extent with such high resolution systems.

Conclusion

Many incidental pathologies of the adjacent organs are detected during MRCP examinations of

the gallbladder and bile ducts. Lesion detection and characterization is improved when MIP images are evaluated together with TSE axial slices and source images. As the MRCP technique becomes more refined and widely available, the complementary information provided by MRCP may assist the management of several cases.

REFERENCES

1. Wallner BK, Shumacher KA, Weidenmaier W, Friedrich JM. Dilated biliary tract: Evaluation with MR cholangiography with a T2-weighted contrast enhanced fast sequence. *Radiology* 1991;181:805-8.
2. Reinhold C, Guibaud L, Genin G, Bret PM. MR cholangiopancreatography: Comparison between two-dimensional fast spin-echo and three-dimensional gradient-echo pulse sequences. *J Magn Reson Imaging* 1995;5:379-84.
3. Ichikawa T, Nitatori T, Hachiya J, Mizutani Y. Breath-held MR cholangiopancreatography with half-averaged single shot hybrid rapid acquisition with relaxation enhancement sequence: Comparison of fast GRE and SE sequences. *J Comput Assist Tomogr* 1996;20:798-802.
4. Reuther G, Kiefer B, Tuchmann A, Pesendorfer FX. Imaging findings of pancreaticobiliary duct disease with single-shot MR cholangiopancreatography. *AJR Am J Roentgenol* 1997;168:453-9.
5. Jara H, Barish MA, Yucel EK, Melhem ER, Hussain S, Ferrucci JT. MR hydrography: Theory and practice of static fluid imaging. *AJR Am J Roentgenol* 1998;170:873-82.
6. Anderson CM, Saloner D, Tsuruda JS, Shapeero L, Lee RE. Artifacts in maximum-intensity-projection display of MR angiograms. *AJR Am J Roentgenol* 1990;154:623-9.
7. Reinhold C, Bret PM. Current status of MR cholangiopancreatography. *AJR Am J Roentgenol* 1996;166:1285-95.
8. Laing AD, Gibson RN. Magnetic resonance cholangiopancreatography. *Australas Radiol* 1999;43:284-93.