

# An Interesting Pediatric Ureteral Obstruction: Malposition of the Right Ureteral Segment Inside the Psoas Muscle: Case Report

## İlginç Bir Pediatrik Üreteral Obstrüksiyon Olgusu: Psoas Kası İçerisine Giren Sağ Üreter

Erdal YILMAZ, MD,<sup>a</sup>  
Ertan BATISLAM, MD,<sup>a</sup>  
Devrim TUĞLU, MD,<sup>a</sup>  
Serhan ALPCAN, MD,<sup>a</sup>

<sup>a</sup>Department of Urology,  
Kırıkkale University Faculty of Medicine,  
Kırıkkale

Geliş Tarihi/Received: 06.04.2008  
Kabul Tarihi/Accepted: 23.12.2008

Yazışma Adresi/Correspondence:  
Erdal YILMAZ, MD  
Kırıkkale University Faculty of Medicine,  
Department of Urology, Kırıkkale  
TÜRKİYE/TURKEY  
erdaly69@mynet.com

**ABSTRACT** Obstructive ureteral anomalies can seriously affect kidney function. Congenital obstructive lesions are more commonly encountered in the proximal and distal regions of the ureter. We present a case study of a patient whose ureter lies inside the psoas muscle without any systemic, traumatic, infiltrative or inflammatory cause, leading to obstruction. The ureter was observed to enter the psoas muscle 4 cm below the ureteropelvic joint and the ureter was freed from this area following a 2 cm dissection. The 1 cm portion of this region of the ureter was resected and end-to-end ureteroureterostomy was performed. We discuss the clinical presentation, diagnostic evaluation, surgical management, and operative results.

**Key Words:** Ureter; ureteral obstruction; psoas muscles

**ÖZET** Obstrüktif üreteral anomaliler böbrek fonksiyonunu ciddi biçimde etkileyebilir. Konjenital obstrüktif lezyonlar üreterin daha çok proksimal ve distal bölümlerinde gözlenir. Biz sistemik, travmatik, infiltratif ve inflamatuvar bir neden olmaksızın gelişen psoas kasının içine giren üreterdeki obstrüksiyonu sunduk. Üreterin üreteropelvik bileşkenin 4 cm altından psoas kasının içine girdiği görülmüş ve 2 cm.lik disseksiyondan sonra serbestleştirilmiştir. Üreterin bu alanından yapılan 1 cm.lik rezeksiyonun ardından uç uca üreteroureterostomi yapılmıştır. Klinik görünümü, tanısal değerlendirimi, cerrahi tedaviyi ve operatif sonuçları tartıştık.

**Anahtar Kelimeler:** Üreter; üreteral obstrüksiyon; psoas kası

**Türkiye Klinikleri J Pediatr 2009;18(4):336-8**

The early diagnosis and treatment of ureteral obstruction is important, as the condition can lead to renal damage.<sup>1</sup> Valves and strictures are the primary causes of the obstructions, apart from ureteropelvic and ureterovesical junctions, which most frequently lead to ureteral obstructions.<sup>1,2</sup> We present a case, in which the ureter lies inside the psoas muscle, thus leading to on obstruction. To our knowledge, this is the first case of such an obstruction to be reported.

### CASE REPORT

Ten-year-old male patient referred from the pediatric outpatient clinic with right lumbar pain, ultrasonograph indicated right hydronephrosis. The patient had no history of trauma, surgery or infection. No abnormality was

observed in the complete urine test and whole blood count of the patient. His biochemical parameters were normal. The urine culture of the patient, whose medical history did not include any urinary system infection, did not indicate any growth. The creatinin clearance of the patient was 84.93. Repeated USG revealed parenchyma thinning in the right kidney and dilatation of the pelvicaliceal system and the proximal ureter. Dilatation of the right kidney pelvicaliceal system was detected by intravenous urography and the ipsilateral ureter was not observed. During retrograde pyelography ureteral catheter did not pass to the kidney, the ureter was seen at the level 4 cm below the ureteropelvic region distally and that opaque solution did not pass over this region. No vesicoureteral reflux was detected in the patient in voiding cystourethrography. Bilateral kidney vascular flows were normal in the renal Doppler ultrasonography. Exploration was decided after these imaging methods, with suspicion at ureteral stricture or valve. Gerota's fascia was opened by a flank incision. The middle region of the ureter was dissected and suspended, and dissection was continued upwards from this region. The ureter was displaced in to the psoas muscle 4 cm below the ureteropelvic joint, and a small bowel segment was observed to adhere to the same point like a tape (Figure 1, 2). Dissection up until the psoas muscle was continued from the ureter entrance, and the ureter was freed from this area following a 2 cm dissection. The adhering bowel

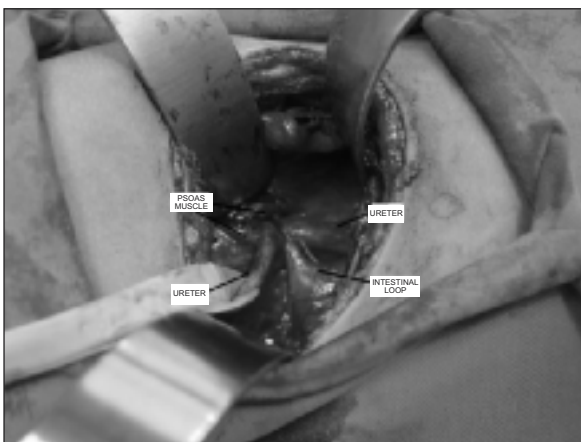


FIGURE 1: Retroperitoneal space during the operation.

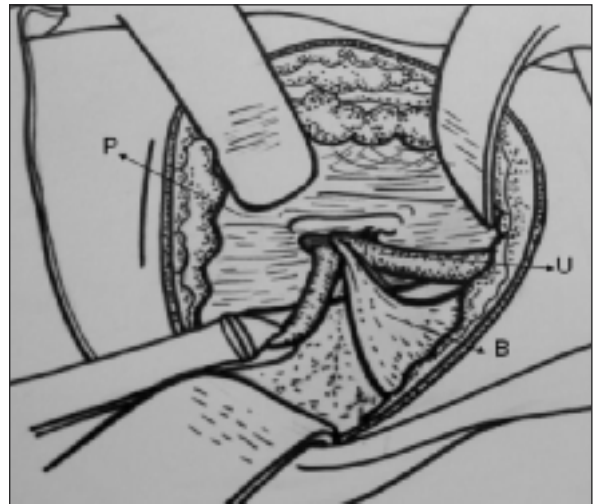


FIGURE 2: Diagrammatic sketch. (U) ureter, (P) psoas muscle, (B) Bowel segment.

segment was dissected from this area. The 1 cm portion of this region of the ureter, which was detected macroscopically, was resected and end-to-end ureteroureterostomy was performed, with a 4.8 F Double-J catheter in situ. Opaque solution passage was observed in the ureter with peristaltic activity on the follow-up IVU examination performed 2 months later. No valves were detected during the microscopic examination of the removed segment. The pathological examination of the resected ureter was normal.

## DISCUSSION

The ureter, the tubular extension of the pelvis renalis, runs downwards in front of the musculus psoas and adherent to the peritoneum.<sup>1</sup> Ureter is localized next to the psoas muscle in the posterior during its retroperitoneal course. The relation of the psoas muscle and the ureter is that of a neighborhood only. Ureter enters the pelvis at the bifurcation level crosswise iliac veins. Retroperitoneal gonadal veins are parallel to the ureter, crosswise to the ureter from the front, from inside to outside before they enter the pelvis.<sup>1</sup> The right ureter is neighbor to terminal ileum, cecum, appendix, ascending colon and their mesenteries in the anterior and the left ureter is neighbor to descending column, sigmoid and their mesenteries.<sup>1</sup>

Ureteral abnormalities are the most important anomalies seen in pediatric urology, as they directly affect the renal functions. These anomalies can appear acutely or stealthily.<sup>3,4</sup> The known ureter anomalies are; termination (ureter ectopy, ectopic ureter), structural (ureterocele, ureteral stenosis, strictures, valves, spiral turn, folds, diverticulum, congenital high position), numerical (blunt-ended duplication of the ureter, inverted Y duplication, multiple ureters), and position (preureteral vena cava, preureteral iliac artery, ureteral herniation) anomalies.<sup>1-5</sup> Congenital obstructive lesions of the ureter primarily appear in the proximal or the distal end. In a pediatric autopsy series, obstruction was observed in the ureteropelvic joint in 34% of the cases, and in the ureterovesical joint in 62% of the cases. Obstruction in the other parts of the ureter was detected at a frequency of 4%.<sup>6</sup> Obstructions in this region usually occur due to ureteral valves or strictures. Niranjana et al have reported a ureteral obstruction due to leukemic infiltration of the psoas muscle in an adult patient.<sup>7</sup>

No cases of obstruction due to the entrance of the ureter into the psoas muscle were encountered in searched literature. In our case, the ure-

ter that is supposed to go downwards on the psoas muscle entered into the psoas muscle and caused obstruction. Although it was stuck to an intestinal loop have suggested an infective, infiltrative, and traumatic incident that the patient may have experienced earlier, the detailed anamnesis of the patient did not contain such incidents. Therefore, we have thought that the case is congenital. Since the sticking of the intestinal loop to the ureter did not have an infective, infiltrative, traumatic story, it can be asserted that it is due to a defect during in utero migration. In the evaluation of a child with ureteral obstruction, if sufficient assessments cannot be made using ureteral imaging methods, that it can enter the psoas muscle throughout its course as in our case should be kept in mind.

Hereby, we report a congenital anomaly of the ureter, causing obstruction by entering the psoas muscle without any systemic, traumatic, infiltrative and inflammatory cause.

### **Acknowledgment**

*We wish thank Gulsah Bademci, MD for help with the figures.*

## REFERENCES

1. Kabalin JN. Surgical anatomy of the retroperitoneum, kidneys, and ureters: In: Walsh PC, Retik AB, Vaughan ED Jr, Wein AJ, eds. Campbell's Urology, 8<sup>th</sup> ed. Philadelphia: WB Saunders Co; 2003. p.3-80.
2. O'Toole S. Congenital anomalies of the kidney and ureter: In: Godbole P, Gearhart J, Wilcox D, eds. Clinical Problems in Pediatric Urology. 1<sup>st</sup> ed. Oxford: Blackwell Publishing; 2006. p.88-100.
3. Ulman I. [Hydronephrosis and urinary obstruction in pediatric age group]. *Turkiye Klinikleri J Pediatr Sci* 2005;1(12):1-4.
4. Başaklar AC. [Urological emergencies of newborn]. *Turkiye Klinikleri J Surg Med Sci* 2007; 3(15):26-38.
5. Hwang AH, McAleer IM, Shapiro E, Miller OF, Krous HF, Kaplan GW. Congenital mid ureteral strictures. *J Urol* 2005;174(5):1999-2002.
6. Bauer SB. Anomalies of the upper urinary tract: In: Walsh PC, Retik AB, Vaughan ED Jr., Wein AJ, eds. Campbell's Urology. 8<sup>th</sup> ed. Philadelphia: WB Saunders Co; 2003. p.1885-924.
7. Niranjana J, Mandal AK, Nijhawan R. Leukemic infiltration of psoas muscle: an unusual cause of ureteral obstruction. *J Urol* 2002;168(5): 2121.