

Single Dose Prophylactic Antibiotics May Not Be Sufficient in Elective Pilonidal Sinus Surgery: An Early Terminated Study

Tek Doz Profilaktik Antibiyotik Elektif Pilonidal Sinüs Cerrahisinde Yeterli Olmayabilir: Erken Sonlandırılan Bir Çalışma

Duray ŞEKER, MD,^a
Celil UĞURLU, MD,^a
Zafer ERGÜL, MD,^a
Melih AKINCI, MD,^a
Engin ÖLÇÜCÜOĞLU, MD,^a
Hakan KULAÇOĞLU, MD^a

^aDepartment of Surgery,
Dışkapı Teaching and
Research Hospital, Ankara

Geliş Tarihi/Received: 19.08.2009
Kabul Tarihi/Accepted: 09.03.2010

Yazışma Adresi/Correspondence:
Hakan KULAÇOĞLU, MD
Dışkapı Teaching and
Research Hospital,
Department of Surgery, Ankara,
TÜRKİYE/TURKEY
hakankulacoglu@hotmail.com

ABSTRACT Objective: The surgical infection rate is not low in some series of elective pilonidal sinus surgery despite single dose antibiotic prophylaxis. This study was designed to compare wound infection rate after a single dose and a 5-day intravenous course of cefazolin plus metranidazole administration in patients who were operated employing Karydakias flap for pilonidal sinus. **Material and Methods:** A total of 50 patients were involved in this prospective randomised clinical study. Karydakias flap procedure was used and a vacuum drain was left in situ in all cases. The patients were divided into two groups: Group 1 had either a single dose of 500 mg metranidazole plus 500 mg cefazolin sodium IV for prophylaxis and Group 2 were subjected to same preoperative drugs IV followed by their oral administration for five days (Sefazol 500 mg tablet plus Flagyl 500 mg tablet, twice a day). The surgical site infection rate, total drainage volume and drain removal time were recorded. **Results:** The study was truncated because of occurrence of an unacceptable infection rate, thus, 30 patients were able to continue on the study. Five surgical site infections were observed in 14 patients in Group 1 (35.71%) whereas only one infection was recorded in 16 patients in Group 2 (6.25%). Although the target patient number was not reached, the statistical difference was already achieved ($p=0.04$). The mean total drainage volume was greater in Group 1 than in Group 2 (91.42 v.s. 72.12 ml; $p=0.073$). However, the mean drain removal times were similar. **Conclusion:** The wound infection rate is high in elective pilonidal sinus surgery. Single dose prophylactic antibiotic combination may not be sufficient to avoid wound infection in pilonidal sinus surgery in which Karydakias flap technique is used.

Key Words: Pilonidal sinus; surgical wound infection; antibiotic prophylaxis; cefazolin

ÖZET Amaç: Pilonidal sinüs nedeniyle elektif cerrahi uygulanan ve tek doz antibiyotik profilaksi yapılan bazı serilerde cerrahi alan enfeksiyonu riski düşük değildir. Bu çalışmada pilonidal sinüs tanısıyla Karydakias tekniğiyle ameliyat edilen hastalarda tek doz sefazolin-metranidazol profilaksi ile aynı kombinasyonun beş günlük uygulamasının yara enfeksiyonu oranına etkisi araştırıldı. **Gereç ve Yöntemler:** Bu prospektif randomize çalışmaya toplam 50 hasta dahil edilmesi planlandı. Tüm hastalara Karydakias flep ameliyatı yapıldı ve vakumlu dren kullanıldı. Hastalar aynı antibiyotik kombinasyonunun iki farklı uygulaması için iki kola ayrıldı. Grup 1'deki hastalara 500 mg metranidazol ile 500 mg sefazolin tek doz IV profilaksi şeklinde verilirken, Grup 2'dekilerde bu kombinasyon oral yoldan 2 x 1 şeklinde 5 güne tamamlandı. Cerrahi alan enfeksiyonu oranı, toplam drenaj miktarı ve dren çekme zamanı kaydedildi. **Bulgular:** Prospektif çalışma kollarından birinde kabul edilemez oranda yüksek enfeksiyon oranı gözlenmesi nedeniyle henüz 30 hasta kayıt edilmişken çalışma sonlandırıldı. Bu süre içinde Grup 1'de yer alan 14 hastanın beşinde (%35.71) enfeksiyon saptanırken, Grup 2'deki 16 hastanın sadece birinde (%6.25) enfeksiyon gelişmişti. Hedeflenen hasta sayısına ulaşılmamış olmasına rağmen gruplar arasındaki fark anlamlılık düzeyine erişmişti ($p=0.04$). Toplam drenaj miktarı Grup 1'de daha yüksek olup, gruplar arasındaki fark istatistiksel anlamlılık düzeyine yakındı (91.42 vs 72.12 ml; $p=0.073$). Grupların dren çekme zamanları benzerdi (3.64/3.31 gün). **Sonuç:** Elektif pilonidal sinüs cerrahisinde yara enfeksiyonu oranları yüksek olabilmektedir. Bu çalışmada, Karydakias flep uygulamasında tek doz profilaktik antibiyotik kombinasyonu yara enfeksiyonunun önlenmesinde yeterli bulunmamıştır.

Anahtar Kelimeler: Pilonidal sinüs; cerrahi yara enfeksiyonu; antibiyotik profilaksi; sefazolin

Sacroccygeal pilonidal disease is a common surgical problem. Many therapeutic options have been employed with various outcomes up to date. Meta-analyses and systematic reviews reveal that total excision and primary off-midline closure techniques offer very good results.¹ However, surgical site infection rates still remain high in many series.²⁻⁶ In fact, wound infection is the major cause of surgical failure, suggesting that perioperative antibiotic use may improve the outcome. Unfortunately, a recent survey conducted by Petersen et al.⁷ showed that only one-third of the clinical studies mentioned if antibiotics were used.

Various antibiotics have been chosen in different series as a preoperative single shot or as short courses.^{2,3} In a recent randomised study, a combination of cephalosporin and metranidazole given in a case series of primary midline closure was observed to be more efficient in infection control in comparison with single dose preoperative metranidazole.² Another series which employed primary closure revealed that antibiotic prophylaxis with a single dose of cefalosporine failed to provide any advantage over the patients received no prophylaxis.³ Although off-midline closure such as Karydakias flap that we routinely use seems to have lower infection rates,⁸ infection rates may remain high after Karydakias procedure when no antibiotic prophylaxis is given.⁵ Therefore, we conducted this prospective randomized study to compare wound infection rates after a single dose and a 5-day course of intravenous cefazolin plus metranidazole regimen.

MATERIAL AND METHODS

After having the approval of the local ethic committee for the study protocol, informed consents were collected from a total of 50 male patients involved in this prospective randomised clinical study. All patients were operated under general anesthesia on an elective basis. The patients were divided into two groups to be administered with the same antibiotic combination in two different timelines. After randomisation by sealed envelopes, single-blind preoperative antibiotics administration was performed by an anesthesia team. Group 1 was given only a single dose of 500 mg metranidazole

(Flagyl 500 mg injectable, Eczacıbaşı, İstanbul, Turkey) plus 500 mg cefazolin sodium (Sefazol 500 mg injectable, Mustafa Nevzat İlaç, İstanbul, Turkey) intravenously just before the induction of general anesthesia as a prophylactic measure, while Group 2 received the same preoperative intravenous administration and then continued on their oral administration for five days (Sefazol 500 mg tablet twice a day and Flagyl 500 mg tablet twice a day).

After total excision, Karydakias flap was employed in all cases.⁹ 3/0 polypropylene mattress sutures were placed for skin closure. A Jackson-Pratt vacuum drain was left *in situ* and removed by observing the daily drainage volume. The drain was removed when daily drainage was 20 ml or less. All patients were instructed to avoid lying or sitting up on the operated area and to take care for personal hygiene. All sutures were removed within two weeks. The wounds were examined by the surgical team on day 1, 2, and 3 and then extended to week 1, 2 and 4 post-operation. If there was redness and swelling at the wound edges or abscess in relation to a suture or spreading wound infection and wound breakdown, the situation was defined as infected wound. In the presence of these signs, wound was termed "overtly infected" even if the microbiological culture results were negative. Wound healing was defined based on complete epithelisation over the wound.

Statistical analysis of the data was done using SPSS for Windows version 11.0 package (Chicago IL). Chi-square test was employed to compare the infection rates and Student's t test was employed to compare the mean values of total drainage volume and drain duration. The level of significance was accepted at $p < 0.05$.

RESULTS

The study was truncated because of an unacceptable infection rate; therefore only 30 patients completed the experiment (14 in Group 1 and 16 in Group 2). All patients were ASA 1 Class. There were no differences in age and the execution time between the groups. The mean total drainage volume in patients in Group 1 was higher than that in patients in Group 2, without any difference in the drain removal time (Table 1).

TABLE 1: Wound infection and drainage values.

Variable	Group 1	Group 2	p
Wound infection (%)	35.71	6.25	0.04
Total drainage volume (ml)	91.42 ± 8.09	3.64 ± 0.17	0.07
Drain removal time (day)	72.12 ± 5.84	3.31 ± 0.15	0.11

Five surgical site infections were observed in Group 1 (5/14, 35.71%) whereas only one infection was recorded in Group 2 (1/16, 6.25) ($p=0.04$). No patients were found to have a wound infection on planned examination dates except for one patient in Group 1 at first week. Other 5 patients returned to the hospital with infection on days 6, 8, 9 and 11 in Group 1 and on day 12 in Group 2.

DISCUSSION

Sacrococcygeal pilonidal disease is very common in a number of countries and it causes an economic burden especially in cases with postoperative morbidity. Wound infection is the major cause of failure after elective pilonidal sinus surgery. Although some publications report low infection rates, this figure can reach up to 38.5%.⁷ The series with low infection rates often lack a complete 30-day follow-up.

Flap procedures improve infection rates as they have lower recurrence risk comparing primary closure at midline.^{4,6,7} However, the prevalence may still be higher than 10%.¹⁰⁻¹² Although perioperative antibiotics may be preventive, only one-third of the reports mention use of antibiotics. In fact, flap techniques are clean procedures generally performed in clean fields. However, sacrococcygeal area is rich of both aerobic and anaerobic microorganisms especially in individuals with poor hygiene. Preoperative antimicrobial preparation can not attenuate the microbial burden adequately. Therefore, when a flap is being performed for sacrococcygeal pilonidal disease electively, the surgical field may naturally be contaminated even no actual abscess or drainage exists. This may imply a full treatment dose of antibiotics in the perioperative period rather than a mere single dose preoperative prophylaxis. For this reason, a prospective randomised trial specifically

focusing on the patterns of antibiotic use in pilonidal disease surgery may guide the surgeons in daily routine practice.

As early as mid-1980s Marks et al.¹³ reported a better and early healing course with a combination of metronidazole and erythromycin after excision and lay open technique. After primary closure techniques gained popularity, antibiotic use found a place in pilonidal sinus surgery without any standardization. Some surgeons prefer a single shot prophylaxis while some centres accept longer antibiotic use although there is no strong evidence.

Previous microbiological studies reported that both aerobic and anaerobic agents were involved in pilonidal disease.¹⁴⁻¹⁶ Therefore, antibiotics should have a broad spectrum coverage. In one of early examples of a single antimicrobial agent series in 1985 Søndena et al.³ concluded that operative results were not influenced by a single dose cefoxitin prophylaxis. Unfortunately the complication rates in both groups of this randomised study were higher than 40% after primary midline closure. This high infection rate might be related to either quite narrow spectrum of cefoxitin or its short-term use.

Better wound complication rates have been obtained in recent studies. Terzi et al.¹⁷ reported 12.8% infection rate after primary midline closure using a single shot broad spectrum combination prophylaxis with intravenous cefuroxime axetil (1.5 g) and metranidazole (500 mg). Al-Khayat et al.¹⁰ similarly reported surgical site infection rate as 12% by using cephalosporin plus metranidazole combination for 24-48 hours in a series of Karydak procedure. Petersen et al.¹⁸ achieved exactly the same wound infection rate after performing the flap technique, but used a single dose preoperative ampicillin-sulbactam. Anyanwu and colleagues¹² reported a somewhat lower infection rate (10.7%) with a single dose broad-spectrum antibiotic.¹⁸ One of the lowest infection rates after Karydak procedure was reported by Bessa,⁸ who used a third generation cephalosporin and metranidazole for 48 hours. However, a strikingly high infection rate (26%) after Karydak procedure was reported recently in a series in which no antibiotic prophylaxis was used in Turkey.⁵

Nevertheless, it seems possible to obtain very acceptable infection rates in Limberg flap series. Mahdy⁴ reported 5% wound infection rate after single dose 1 g ampicillin-sulbactam, while Ersoy et al.⁶ reported 4.5% infection rate after 1 g cefazolin sodium prophylaxis. Higher wound infection rates were also reported in Limberg flap series in spite of a 3-day course of cefuroxime plus metranidazole administration.¹¹

Although surgical antibiotic prophylaxis is standard in most elective procedures, no consensus exists for elective pilonidal sinus surgery. There is a spectrum of antibiotic administration ranging from a 5-day combination therapy to administration of a single dose first generation cephalosporin. After observing an unacceptable wound infection rate in a large group of cases who used limited antibiotics, we decided to conduct this prospective randomised study. However the study could not reach the previously planned number of cases due to a very high infection rate in the single shot prophylaxis group. This made us halt the study early to avoid more patient morbidity.

In fact, early terminated randomised trials are an important in biomedical literature. The number of these reports is increasing and they are often published in high profile journals and receive close interest.¹⁹ A comprehensive review by Montori et al.²⁰ revealed that an average of 63% of the planned target patient volume was reached in early terminated randomised studies. Although a p value of 0.001 is recommended for strong evidence to stop early, this figure is generally used in hematologic or oncologic studies. Thus we truncated our surgical study at a p value of 0.04.

There are generally two types of questions regarding antibiotic use in elective pilonidal disease treatment: "Single dose or for some more days?" and "Single agent or combination" It is possible to blend these two questions in the same trial. The present study compared the same agents in different timelines. Similar to our study, Lundhus et al.²¹ 15 years ago compared one and four day use of metranidazole-ampicillin combination in a series of primary midline closure. Contrary to our results, they found no difference between two groups. A

recent randomised study from the United Kingdom compared two different antibiotic protocols.² The wound infection rate was significantly higher in the group receiving a single dose of single drug (metranidazole 500 mg IV) when compared to the group receiving a combination (cefuroxime 1.5 g IV and metranidazole 500 mg IV preoperatively, and co-amoxiclav 375 mg p.o. t.i.d. postoperatively for five days) at week 2 (20% vs. 0%; $p < 0.0001$) and at week 4 (44% vs. 12%; $p < 0.03$). However it is not possible to discriminate the reason for a higher infection rate in that study: Due to insufficient antimicrobial coverage or short duration of administration? For this reason, the protocol of single dose preoperative antibiotic prophylaxis in our study was chosen as "metranidazole plus cefazolin" instead of a merely anti-anaerobic coverage. The results of the present study suggest that continuing a broad spectrum antibiotic regimen postoperatively may lower surgical infection rates.

CONCLUSION

The wound infection rate after elective pilonidal sinus surgery is not low in spite of improved techniques and high-tech suture materials. A broad spectrum antibiotic use may yield considerably better results.

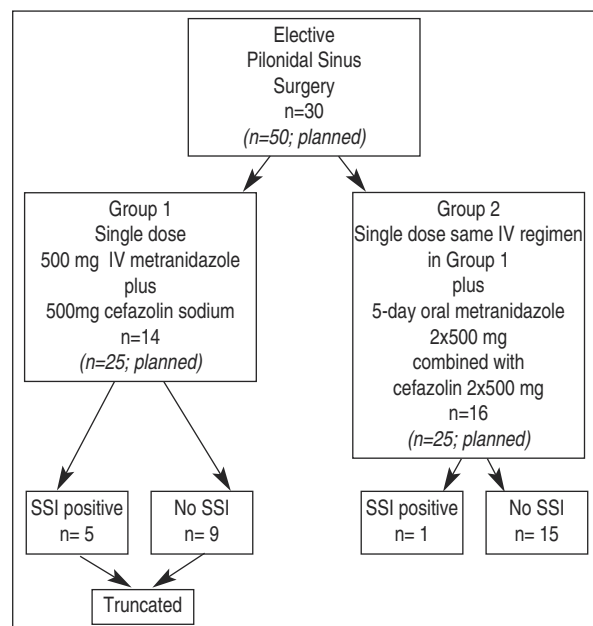


FIGURE: Diagram.
SSI: Surgical site infection.

REFERENCES

- McCallum IJ, King PM, Bruce J. Healing by primary closure versus open healing after surgery for pilonidal sinus: systematic review and meta-analysis. *BMJ* 2008;336(7649):868-71.
- Chaudhuri A, Bekdash BA, Taylor AL. Single-dose metronidazole vs 5-day multi-drug antibiotic regimen in excision of pilonidal sinuses with primary closure: a prospective, randomized, double-blinded pilot study. *Int J Colorectal Dis* 2006;21(7):688-92.
- Søndena K, Nesvik I, Gullaksen FP, Furnes A, Harbo SO, Weyessa S, et al. The role of cefoxitin prophylaxis in chronic pilonidal sinus treated with excision and primary suture. *J Am Coll Surg* 1995;180(2):157-60.
- Mahdy T. Surgical treatment of the pilonidal disease: primary closure or flap reconstruction after excision. *Dis Colon Rectum* 2008;51(12):1816-22.
- Ersoy E, Devay AO, Aktimur R, Doganay B, Özdoğan M, Gündoğdu RH. Comparison of the short-term results after Limberg and Karydakis procedures for pilonidal disease: randomized prospective analysis of 100 patients. *Colorectal Dis* 2009;11(7):705-10.
- Ersoy OF, Karaca S, Kayaoglu HA, Ozkan N, Celik A, Ozum T. Comparison of different surgical options in the treatment of pilonidal disease: retrospective analysis of 175 patients. *Kaohsiung J Med Sci* 2007;23(2):67-70.
- Petersen S, Koch R, Stelzner S, Wendlandt TP, Ludwig K. Primary closure techniques in chronic pilonidal sinus: a survey of the results of different surgical approaches. *Dis Colon Rectum* 2002;45(11):1458-67.
- Bessa SS. Results of the lateral advancing flap operation (modified Karydakis procedure) for the management of pilonidal sinus disease. *Dis Colon Rectum* 2007;50(11):1935-40.
- Karydakis GE. Easy and successful treatment of pilonidal sinus after explanation of its causative process. *Aust N Z J Surg* 1992;62(5):385-9.
- Al-Khayat H, Al-Khayat H, Sadeq A, Groof A, Haider HH, Hayati H, et al. Risk factors for wound complication in pilonidal sinus procedures. *J Am Coll Surg* 2007;205(3):439-44.
- Arumugam PJ, Chandrasekaran TV, Morgan AR, Beynon J, Carr ND. The rhomboid flap for pilonidal disease. *Colorectal Dis* 2003;5(3):218-21.
- Anyanwu AC, Hossain S, Williams A, Montgomery AC. Karydakis operation for sacrococcygeal pilonidal sinus disease: experience in a district general hospital. *Ann R Coll Surg Engl* 1998;80(3):197-9.
- Marks J, Harding KG, Hughes LE, Ribeiro CD. Pilonidal sinus excision--healing by open granulation. *Br J Surg* 1985;72(8):637-40.
- Allen-Mersh TG. Pilonidal sinus: finding the right track for treatment. *Br J Surg* 1990;77(2):123-32.
- Holzer B, Grüssner U, Brückner B, Houf M, Kiffner E, Schildberg FW, et al.; EMD study group. Efficacy and tolerance of a new gentamicin collagen fleece (Septocoll) after surgical treatment of a pilonidal sinus. *Colorectal Dis* 2003;5(3):222-7.
- Miocinović M, Horzic M, Bunoza D. The prevalence of anaerobic infection in pilonidal sinus of the sacrococcygeal region and its effect on the complications. *Acta Med Croatica* 2001;55(2):87-90.
- Terzi C, Canda AE, Unek T, Dalgic E, Fuzun M. What is the role of mechanical bowel preparation in patients with pilonidal sinus undergoing surgery? Prospective, randomized, surgeon-blinded trial. *World J Surg* 2005;29(11):1465-71.
- Petersen S, Aumann G, Kramer A, Doll D, Sailer M, Hellmich G. Short-term results of Karydakis flap for pilonidal sinus disease. *Tech Coloproctol* 2007;11(3):235-40.
- Bassler D, Ferreira-Gonzalez I, Briel M, Cook DJ, Devereaux PJ, Heels-Ansdell D, et al. Systematic reviewers neglect bias that results from trials stopped early for benefit. *J Clin Epidemiol* 2007;60(9):869-73.
- Montori VM, Devereaux PJ, Adhikari NK, Burns KE, Eggert CH, Briel M, et al. Randomized trials stopped early for benefit: a systematic review. *JAMA* 2005;294(17):2203-9.
- Lundhus E, Gjøde P, Gottrup F, Holm CN, Terpling S. Bactericidal antimicrobial cover in primary suture of perianal or pilonidal abscess. A prospective, randomized, double-blind clinical trial. *Acta Chir Scand* 1989;155(6-7):351-4.