

Collagenous Fibroma of the Caruncle: A Rare Pediatric Case

Karünkülün Kollajenöz Fibromu: Nadir Bir Çocuk Olgusu

Lara BİLİCİ^a, Ayşe Buse MELİK^a, İlke BAHÇECİ ŞİMŞEK^b, Aydın SAV^c

^aYeditepe University Faculty of Medicine, İstanbul, Türkiye

^bDepartment of Ophthalmology, Yeditepe University Kozyatağı Hospital, İstanbul, Türkiye

^cDepartment of Medical Pathology, Yeditepe University Koşuyolu Hospital, İstanbul, Türkiye

ABSTRACT A 9-year-old man was presented with a left caruncle 3x3 mm hyperpigmented mass without necrosis. The lesion was excised with a 4 mm incision to include the edge of the caruncle. The sample consisted of two brown pieces of elastic tissue measuring 1x0.5x0.3 cm and 0.5x0.3x0.2 cm. Histopathology revealed a tumor rich in infiltrative fusiform cells with a dense collagenous matrix. For the internal control use epidermal melanocytes were immunohistochemically positive for MART-1, and S-100 whereas the tumor cells were negative. Also CD34 was negative in tumor tissue. The tumor matrix was collagen-dense and was proved by applying Masson trichrome and reticulin staining to show collagen fibers lined up in parallel with conventional histochemistry. The lesion was interpreted as a collagenous fibroma. Differential diagnoses, included nevomelanocytic nevus, melanoma, vascular tumors, schwannoma, and neurofibroma. As far as we know, this is the first case of collagenous fibroma located in the caruncle in a pediatric patient.

Keywords: Eye; immunohistochemistry; biomarkers, tumor; pathology; fibroma

ÖZET Dokuz yaşında bir erkeğe nekrozu olmayan sol karünkül 3x3 mm hiperpigmente kitle sunuldu. Karünkülün kenarını içerecek şekilde 4 mm'lik bir kesi ile lezyon eksize edildi. Numune, 1x0,5x0,3 cm ve 0,5x0,3x0,2 cm ölçülerinde 2 kahverengi renkli elastik doku parçasından oluşuyordu. Histopatoloji, yoğun bir kollajenöz matrikse sahip infiltratif fusiform hücre bakımından zengin bir tümör ortaya çıkardı. Epidermal melanositler MART-1 ve S-100 için immünohistokimyasal olarak pozitif. Bununla birlikte, tümör hücreleri MART-1, CD34 ve S-100 için negatif. Tümör matrisi kollajen yoğunluğunu ve geleneksel histokimya ile paralel dizilmiş kollajen liflerini göstermek için Masson trikrom ve retikülün boyaması uygulanarak kanıtlandı. Lezyon kollajenöz fibroma olarak yorumlandı. Bu durumda ayırıcı tanılar nevomelanositik nevüs, melanom, vasküler tümörler, schwannoma ve nörofibromayı içeriyordu. Bildiğimiz kadarıyla, bu, pediatrik bir hastada karünkülden bulunan kollajen fibromanın ilk vakasıdır.

Anahtar Kelimeler: Göz; immünohistokimya; biyobelirteçler, tümör; patoloji; fibrom

A collagenous fibroma (CF) is a rare, benign, slowly growing, fibroblastic tumor that mostly presented without pain in the soft tissues of the fascia, subcutis, or within skeletal muscle. It is first described as desmoplastic fibroblastoma by Evans in 1995 and was renamed a CF.¹ Some of the cases also showed the presence of bone erosion. Previous reports have shown that CF is rarely encountered in the eye and there are a few cases of CF in the lacrimal gland, and orbital rim.^{2,3} According to a study of 63 cases, tumors appear to be encountered mostly in males than in females with an average age of fifty years.⁴ The tumor cells are stellate and spindle-

shaped fibroblasts separated by a collagenous or myxocollagenous matrix. Mitotic activity is quite rare or not seen at all. For the diagnosis of CF, Masson Trichrome staining is preferred. We describe a rare case of CF at the inner canthus of the eye, the caruncle. To our knowledge, it is the first reported case of CF occurrence in the caruncle.

CASE REPORT

A 9-year-old male had a slowly expanding fixed mass of 3x3 mm at the left caruncle (Figure 1). The lesion showed only discoloration without redness or pain. He had no prior surgical or unintentional facial or or-

Correspondence: Aydın SAV

Department of Medical Pathology, Yeditepe University Koşuyolu Hospital, İstanbul, Türkiye

E-mail: murataydinsav@gmail.com

Peer review under responsibility of Türkiye Klinikleri Journal of Ophthalmology.

Received: 03 Oct 2022

Received in revised form: 15 Feb 2023

Accepted: 06 Mar 2023

Available online: 09 Mar 2023

2146-9008 / Copyright © 2023 by Türkiye Klinikleri. This is an open access article under the CC BY-NC-ND license (<http://creativecommons.org/licenses/by-nc-nd/4.0/>).



bital damage, also he denied any deterioration in vision and diplopia. On examination, his acuity was 20/20 OS. Fundus examination was normal. Proptosis or restriction of ocular motility was not observed. Malignancy was not considered and the mass was followed up for three months. After 3-months follow up slight growth was detected in the mass. His parents insisted on the excision of the mass.

Total excision was applied as 4 mm, along with the safety margin of the caruncle. The specimen consisted of a fragment of two brown-colored elastic tissue measuring 1x0.5x0.3 cm and 0.5x0.3x0.2 cm. The patient had healed without any complications.

Microscopic examination of excised tissue showed an infiltrative, paucicellular fusiform cell lesion. This lesion consisted of a dense collagenous matrix in the dermal soft tissues below the conjunc-

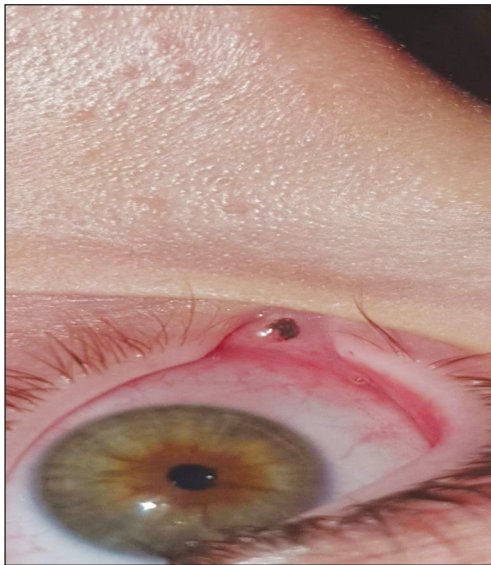

FIGURE 1: 9-year-old male with a slowly expanding darkly stained fixed mass of 3x3 mm at the left caruncle.

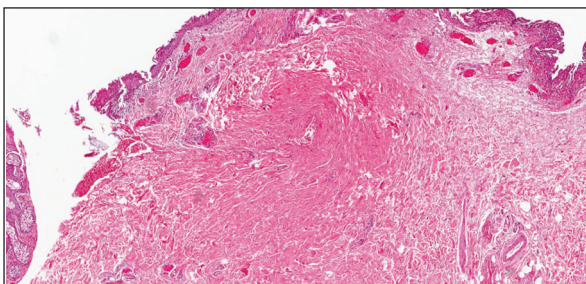


FIGURE 2: Excised tissue from the caruncle showed an infiltrative, sparsely fusiform cell lesion (H&E, x3.2 original magnification).

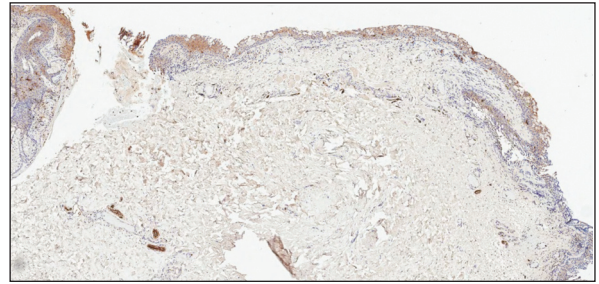


FIGURE 3: S100P reactivity is in tumors but is solely seen in cutaneous nerves (S100P, Biotinylated streptavidin complement, x50 original magnification).

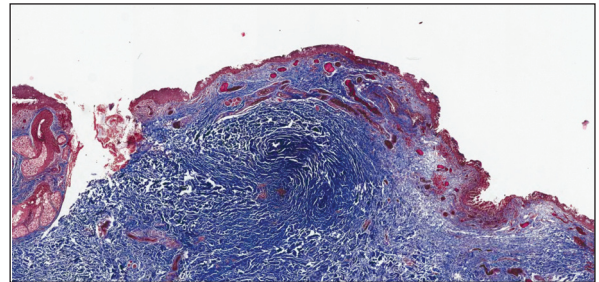


FIGURE 4: Masson's trichrome stains demonstrated dense undulant collagenous layers (MTC, x80 original magnification).

tival epithelium containing goblet cells. Within the neoplasm, there was dense parallel arrayed collagen bundles (Figure 2). There was no mitosis, or necrosis unassociated with inflammatory infiltration. The matrix forming the lesion was spread between indigenous connective tissue, cutaneous nerves, and dermal adipose cushions.

Immunohistochemical analysis revealed no reaction with S100P (Figure 3), MART-1 and, CD34 (not shown). Ki67 labeling index was 0.5%, consistent with an extremely slow proliferation rate. Conventional histochemical staining procedures, Masson's trichrome (Figure 4), and reticulin stains (not shown) demonstrated dense undulant collagenous layers but elastic fiber-free tumor matrix.

The immunohistochemical analysis was provided to exclude the differential diagnosis, such as nevomelanocytic nevus, melanoma, vascular tumors, schwannoma, and neurofibroma. Finally, the diagnosis of the lesion was decided as a CF with the help of both immunohistochemical and conventional histochemical staining procedures. The patient was accepted to sign an informed consent form for this study.

DISCUSSION

There are examples of masses in the orbital region for pediatric patients. However, none of them reported the presence of CF. In the relevant literature, a 13-month-old boy was diagnosed with nodular fasciitis after presenting with new-onset proptosis of the right eye.⁵ Histologically it was characterized by collagenous stroma and myxoid matrix and with minimal inflammatory cells predominantly formed by spindle cells and high mitotic activity as well. Unlike CF, inflammation and pain are common symptoms of nodular fasciitis lesions which grow rapidly. Additionally, there is a 53-year-old female patient with mild right upper eyelid swelling, without redness or pain showing similar findings, i.e. non-palpable or tender, unaccompanied with inflammation. The nodule was paucicellular, composed of dense bands of hyalinized collagenous tissue and a myxoid background. There was no mitotic activity or necrosis. This is a true example of CF in the orbital region.² Another example of CF was a 40-year-old female patient with left periorbital swelling with the features of stellate fibroblasts within a dense collagenous matrix. Rare blood vessels and no mitotic activity were observed.³

Tumors from fibrous and related tissues were evaluated and ruled out. The solitary fibrous tumor is a rarely encountered mesenchymal tumor in which cells are composed of collagenous stroma and centrally hyalinized and contain some dilated vessels as well. Mitotic activity is rare. Some variants of solitary fibrous tumor-like giant cell angiofibroma, are usually encountered in the orbit. Fibrocollagenous dermatofibromas consist of collagen and fibroblast-like cells arranged irregularly or fasciculated. Mitoses are rare. Another illustration is the cutaneous myxoid fibroblastoma, which consists of cells with stellate and spindle shapes that are loosely distributed in a fascicular pattern and resemble “tissue cultures of fibro-

lasts”. Rhabdomyosarcoma, which is the most frequently seen soft tissue sarcoma of childhood, has been considered but ruled out because of its histopathologic features and malignancy.⁶ Immunohistochemical analysis was preferred for the exclusion of differential diagnosis by the selective use of S100P, MART-1, CD34, and Ki67.

The definitive diagnosis was confirmed as CF by using the conventional histochemical staining methods, e.g., Masson’s trichrome and reticulin stains. Conclusively, reported cases of CF are rarely encountered in the orbit of the eye, mostly laterally. However, in our case, the tumor is located medially, i.e., in the caruncle. In the conclusion, our case is the first example of a CF occurrence in the caruncle of a pediatric case. The patient was no recurrent lesion upon the follow-up period.

Source of Finance

During this study, no financial or spiritual support was received neither from any pharmaceutical company that has a direct connection with the research subject, nor from a company that provides or produces medical instruments and materials which may negatively affect the evaluation process of this study.

Conflict of Interest

No conflicts of interest between the authors and / or family members of the scientific and medical committee members or members of the potential conflicts of interest, counseling, expertise, working conditions, share holding and similar situations in any firm.

Authorship Contributions

Idea/Concept: Aydın Sav; **Design:** Aydın Sav; **Control/Supervision:** Aydın Sav, Lara Bilici, Ayşe Buse Melik; **Data Collection and/or Processing:** Lara Bilici, Ayşe Buse Melik, İlke Bahçeci Şimşek; **Analysis and/or Interpretation:** Aydın Sav, Lara Bilici, Ayşe Buse Melik; **Literature Review:** Lara Bilici, Ayşe Buse Melik; **Writing the Article:** Lara Bilici, Ayşe Buse Melik; **Critical Review:** Aydın Sav; **References and Fundings:** Aydın Sav; **Materials:** İlke Bahçeci Şimşek, Aydın Sav.

REFERENCES

1. Evans HL. Desmoplastic fibroblastoma. A report of seven cases. *Am J Surg Pathol.* 1995;19(9):1077-81. [[Crossref](#)] [[PubMed](#)]
2. Ahn M, Osipov V, Harris GJ. Collagenous fibroma (desmoplastic fibroblastoma) of the lacrimal gland. *Ophthalmic Plast Reconstr Surg.* 2009;25(3):250-2. [[Crossref](#)] [[PubMed](#)]
3. Stacy RC, Jakobiec FA, Fay A. Collagenous fibroma (desmoplastic fibroblastoma) of the orbital rim. *Ophthalmic Plast Reconstr Surg.* 2013;29(4):e101-4. [[Crossref](#)] [[PubMed](#)]
4. Miettinen M, Fetsch JF. Collagenous fibroma (desmoplastic fibroblastoma): a clinicopathologic analysis of 63 cases of a distinctive soft tissue lesion with stellate-shaped fibroblasts. *Hum Pathol.* 1998;29(7):676-82. [[Crossref](#)] [[PubMed](#)]
5. Compton CJ, Clark JD, Thompson MP, Lee HB, Nunery WR. Nodular fasciitis of the orbit. *Ophthalmic Plast Reconstr Surg.* 2016;32(6):e154-e6. [[Crossref](#)] [[PubMed](#)]
6. Weedon D. Tumors and tumor-like proliferations of fibrous and related tissues. *Weedon's Skin Pathology.* 3rd ed. London: Churchill Livingstone Elsevier; 2010. p.810-44. [[Crossref](#)]