

Microsurgical loop intussusception in epididymovasostomy (An alternative technique in the rat model)

Âli İhsan TAŞÇI, Turhan ÇAŞKURLU, M.İhsan KARAMAN, Güven SEVİN,
Sefa RESİM, Gökhan GÜRBÜZ

Dept. of Urology, Vakıf Gureba Hospital, İstanbul, TURKEY

Epididymovasostomy done by intussusception of an epididymal loop into the vas deferens seems more simple and more reliable than the end-to-side and end-to-end anastomosis technique. Loop intussusception technique epididymovasostomy was performed in 10 adult rats bilaterally. Postoperative anatomical and histological patency rate was high as 80%. In only 4 (20%) anastomosis was unsuccessful which was evident with the formation of sperm granulomas. This new technique has the superiority of end-to-side and end-to-end epididymovasostomy. There are no technical limitation for clinical usage. [Turk J Med Res 1994; 12(6): 261-263]

Key Words: Epididymovasostomy, Loop intussusception

First, Silber used microsurgical end-to-end epididymovasostomy of the single tubule to the vas for the treatment of obstructive azospermia in 1978 (1). After that, various experimental studies have been done on modification of Silber's technique (2,3). In this type of operation, there are many difficulties. Most important one is deciding which epididymal tubule is the afferent loop for anastomosis.

Microsurgical end-to-side anastomosis techniques have been begun to use in order to avoid the problems of end-to-end technique (4,5). But, in this technique, correct placement of the sutures are difficult in the epididymal tubule.

Microsurgical epididymovasostomy by loop intussusception technique have been used in the rat model as a variation of end-to-side technique which simple and reliable by Stefanovic and colleagues (6).

We used the technique loop intussusception in the experimental animal model with some modifications. The anatomical and histological results are presented and the technique of loop intussusception is described.

Received: Oct. 1, 1994

Accepted: Oct. 23, 1994

Correspondence: Ali İhsan TAŞÇI
Dept. of Urology,
Vakıf Gureba Hospital,
İstanbul, TURKEY

MATERIALS AND METHODS

Loop intussusception technique epididymovasostomy was performed in 10 adult male Sprague-Dawley rats (average weight 300 g) bilaterally. After induction of anesthesia with ether, intramuscularly ketalar (50 mg/kg) was used for anesthesia. Infection prophylaxis was made with gentamicin 4 mg/kg intramuscularly. Dissection and sutures were done under microscope with 5% and 20% magnification.

After disinfection with povidone-iodine, a longitudinal scrotal midline incision was made and scrotal contents exposed after dissecting the tunica vaginalis of testis. The vas deferens identified, sharply dissected from surrounding tissue and transected near the cauda epididymis. Also, proximal end of vas deferens was ligatured after transection (Figure 1/A,B,C). Adventitia of the epididymis was excised equal to the size of the vas deferens in the region of the cauda epididymis (Figure 1/D). After that, slight pressure applied to the epididymis and part of epididymal loops delivered into the field. Single loop of the tubule was identified with sharp, delicate dissection. Connective tissue between the loops was protected for the placement of the sutures.

After dilatation of the vas lumen with microscopic vasodilators, two 10/0 nylon is placed on the posterior aspect of the vas deferens from adventitia and muscularis of vas to adventitia of the epididymis (Figure 1/E).

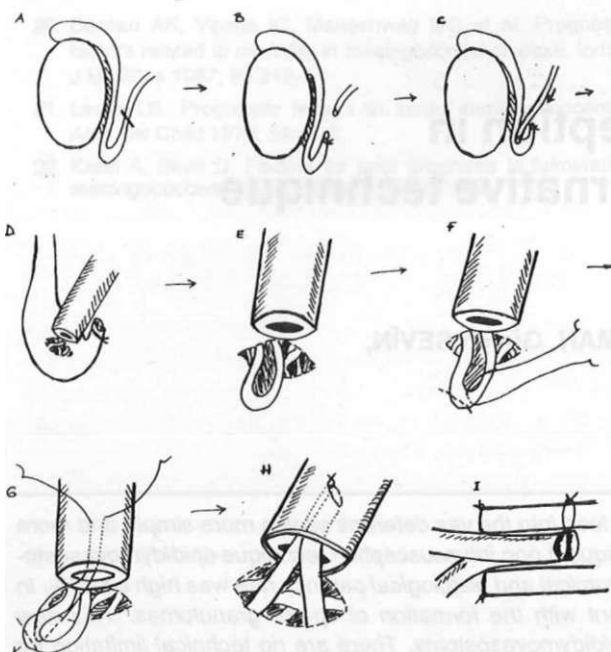


Figure 1. The technics of the loop intussusception method

A suture was placed to connective tissue between the loop and only inner part of the epididymal tubule itself with 10/0 nylon with double 70 micron round needle. After the placement of the suture, tip of the loop was opened tangentially with microscissor. Then, one of the needle was passed through the entire wall of the vas from the lumen to the outside at a distance 3 times the width of epididymal tubule then, second needle was passed with same way (Figure 1/F.G). Suture was pulled towards to vas. This allows the entire loop to slide into the lumen of the vas for a distance equal to 3 times the width of the tubule. After that, suture is tied and ends were cut (Figure 1/H.I).

The outer layer that between transected vasal adventitia and muscularis with epididymal adventitia, is closed using 3 or 4 interrupted 10/0 nylon sutures in addition to the first two sutures.

The same procedure was performed on the contralateral side. Testes was then replaced through the tunical incision. Tunica vaginalis and scrotal skin was closed with a continuous running suture of 6/0 chromic gut in 2 planes. The wound painted with iodine solution. Any drain, scrotal support and dressing were not used. The entire operation can be completed within 2 hours and only 1 injection of ketalar is sufficient. Post-operative management of the rats included a clean cage and no limitation on food and water.

After 2 months, under ether and ketalar anesthesia, the rats were re-explored through a scrotal midline incision. The scrotal contents were delivered from scrotum. All anastomoses were evaluated for the presence of scar tissue, infection and presence of

spermatic granulomas. The patency of the anastomosis was checked in four ways:

1. Since, the vasal wall is transparent, the fluid of the vas can be seen easily.

2. After transection of the vas, the epididymal Cauda was squeezed. If the lumen of the anastomosis was patent, fluid of the vas efflux can be seen; if obstructed there is not fluid efflux.

3. Under light microscopy the fluid of the vas was examined for the presence of sperm.

4. Specimens were sent to pathology laboratory and longitudinal sections of the specimens were done for histological confirmation of patency and existence of spermatic granulomas in all anastomoses.

After the examination of the anastomosis field and excision of the scrotal contents, scrotal skin was closed with 6/0 chromic gut.

RESULTS

After 2 months, there were no infection and anastomotic disruption. In 16 anastomoses (80%), epididymo-vasal line were patent and there were no macroscopic spermatic granulomas. There was minimal microscopic spermatic granuloma in three anastomoses, but all of them were patent. In 4 anastomoses (20%), patency were not found and there were both macroscopically and microscopically spermatic granulomas.

DISCUSSION

Various surgical procedures have been developed to correct obstructive azospermia caused by epididymal blockage. Macrosurgical vasoepididymostomy using a side-to-side anastomosis to create a fistula had been the standard approach and was successful some cases of epididymal obstruction (7-10). But, the overall patency rate for side-to-side fistula method had calculated to be 43.7 percent, with a pregnancy rate of 16.8 percent (5).

Silber described and popularized a true microsurgical vasoepididymal anastomosis (1). He serially cut off the end of the epididymis until reaching that point just above the obstruction. The cut end of the distal vas was brought into contact with that portion of the tubule exuding sperm, and two lumens were approximated with four 9/0 or 10/0 nylon sutures. This end-to-end epididymovasostomy technique have reportedly been excellent (11,12). However, in this type of epididymovasostomy, there are many difficulties such as, determining proximal end loop of epididymal tubule, vessels at the cut end of the epididymis (5). Also, diameter of the epididymal tubule and vas deferens are different so that increases the risk of sperm leakage (6).

The end-to-side epididymovasostomy has advantages to end-to-end technique and many experimental and clinical studies have been done. In this technique resection of epididymis is not require, identification of the patent tubule is easier and there is little to no bleeding to obscure the surgeon's view (5,13). But, in this technique, correct placement of the sutures are difficult in the epididymal tubule. Incorrect sutures can lead to sperm leakage, blocking the tubule, or stricture at the anastomosis site (6).

The microsurgical epididymovasostomy by loop intussusception have many advantages. There are no any obstructing sutures in the epididymal lumen and the tangentially incision on the tip of the tubule is sufficient for patency. Also, distal non-functional stump is another benefit for tamponade, blocking sperm leakage.

Stefanovic's original microsurgical epididymovasostomy by loop intussusception technique has two peritubular connective tissue sutures which allows the epididymes into the vas deferens and their sutures does not touches the mucosa of the epididymal tubule. But, we tough that very thin connective tissue between the epididymal loops is not suitable for two sutures and only one suture which has connective tissue and tubulus mucosa is sufficient. They indicated that the segment of non-functional epididymal stump located in the lumen of the vas deferens is usually resorbed over time (in 90% of anastomoses after 3 months), but, we didn't see any resorption to the non-functional epididymal tubule after two months. Also, they stated that this method have 100% patency rate (6).

In conclusion, this method has the superiority of side-to-end and end-to-end epididymovasostomy. The patency rate is high. There are no technical limitation for clinical usage. Technique requires only one stitches, does not depend on tubull size and does not require the determination of proximal and distal ends of the epididymal tubule.

Loop intusepsiyon tekniği ile epididimovasostomi

Epididimal tubulun vaz deferens içerisine intusepsiyonu end-to-end ve end-to-side anastomoz tekniklerinden daha basit ve daha güvenilirdir.

Loop intusepsiyon tekniği ile epididimovasostomi 10 erişkin sıçanda bilateral olarak gerçekleştirildi. %80'inde post operatif anatomik ve histolojik açıklık vardı. Sadece 4 anastomoz (%20) belirgin sperm granulumu oluşması ile beraber başarısızdı. Loop intusepsiyon tekniği end-to-end ve end-to-side epididimovasostomi gibi diğer anastomoz tekniklerinden üstündür ve klinik kullanımda bir sınırlılığa yoktur. [TurkJ Med Res 1994; 12(6): 261-263]

REFERENCES

1. Silber S.J. Microscopic vasoepididymostomy specific micro-anastomosis to the epididymal tubule. Fertil Steril 1978; 30:565-71.
2. Belgrano E, Carmignani G, Puppo P et al. Tubulovasostomy in the rat: a new experimental model. J Androl 1983; 4:253-5.
3. Ozdiler E, Kelami A. Microsurgical splint epididymovasostomy. Eur Urol 1981; 7:81-4.
4. Lee HY. A 20 year experience with epididymovasostomy for pathological epididymal obstruction. Fertil Steril 1987; 47:487-91.
5. Thomas AJ Jr. Vasoepididymostomy. Urol Clin North Am 1987; 14:527-38.
6. Stefanovic KB, Clark SA, Buncke HJ. Microsurgical epididymovasostomy by loop intussusception; A new technique in the rat model. Br J Urol 1991; 68:518-23.
7. Dubin L, Amelar RD. Magnified surgery for epididymovasostomy. Urology 1984; 23:525.
8. Hendry WF. The long-term results of surgery for obstructive azospermia. Brit J Urol 1981; 53:664-8.
9. Hendry WF, Parslow JM, Stedronska J. Exploratory scrototomy in 168 men azospermic males. Brit J Urol 1983; 55:785.
10. Jitendra KK, Phadke AM. Vaso-epididymal anastomosis. Fertil Steril 1975; 26:741-56.
11. Silber S.J. Microsurgery for vasectomy reversal and vasoepididymostomy. Urology 1984; 23:505.
12. Silber S.J. Reversal of vasectomy and the treatment of male infertility: Role of microsurgery, vasoepididymostomy and pressure-induced changes of vasectomy. Urol Clin North Am 1981; 8:53.
13. Southwick G.J, Temple-Smith PD. Epididymal microsurgery: Current techniques and new horizons. Microsurgery 1988; 9:266-77.