

Maxillary Sinus Mucocele with Exudative Retinal Detachment and Ocular Dystopia Without Diplopia

Diplojisiz Oküler Distopi ve Eksudatif Retina Dekolmanına Yol Açan Maksiller Sinüs Mukoseli

Serpil YAZGAN,^a
Sultan BİŞKİN,^b
Orhan AYAR,^a
Mehmet Orçun AKDEMİR,^a
İrem IŞIK,^a
Suat Hayri UĞURBAŞ^a

Departments of
^aOphthalmology,
^bEar Nose and Throat
 Bülent Ecevit University
 Faculty of Medicine,
 Zonguldak

Received: 14.10.2016
 Received in revised form: 30.12.2016
 Accepted: 06.01.2017
 Available online: 10.08.2018

Correspondence:
 Serpil YAZGAN
 Bülent Ecevit University
 Faculty of Medicine,
 Department of Ophthalmology, Zonguldak,
 TÜRKİYE/TURKEY
 drsrplyzgn@hotmail.com

ABSTRACT Mucocele is a cystic lesion occurring by the obstruction of drainage of normal paranasal sinus secretions due to infections, trauma, and rarely tumor. This lesion can impress to orbital contents by eroding orbital bone and it can be confused with malignant tumors. Most mucoceles originate from frontal and ethmoid sinuses, whereas maxillary and sphenoid sinus presentation is rare. In this case report we have presented a maxillary sinus mucocele case leading to asymptomatic inferior exudative retinal detachment and pushing up glob. A 43-year-old woman presented with swelling on her right malar region and lower eyelid lasting one year and increasing last three months. The patient had upward ocular dystopia and an exudative retinal detachment not extending the macula at the inferior retinal area in her right eye. She had diagnosed right maxillary sinus tumor suspicion by clinical examination and imaging methods. Operation was performed by the ear-nose-throat department. While ocular dystopia completely recovers, exudative retinal detachment was still present at the postoperative first day. As a result, maxillary sinus mucocele can lead to findings such as ocular dystopia without diplopia and exudative retinal detachment, and clinical signs may mimic the tumor.

Keywords: Diplopia; mucocele; retinal detachment

ÖZET Mukosel travma, infeksiyon ve nadiren de tümör nedeniyle normal paranasal sinus drenajının engellenmesi ile oluşan kistik bir lezyondur. Bu lezyon orbital kemiği erode ederek orbital içeriğe bası yapabilir ve malign tümörlerle karıştırılabilir. Çoğu mukosel frontal ve etmoid sinus kaynaklıdır, oysa maksiller ve sfenoidal sinus presentasyonu nadirdir. Biz bu makalede globu iten ve asemptomatik alt kadran eksudatif retina dekolmanına yol açan bir maksiller sinus mukoseli olgusunu sunduk. Kırk-üç yaşında bir kadın, sağ yanak ve alt göz kapağı bölgesinde 1 yıldır var olan ve son 3 aydır artan şişlik ile başvurdu. Glopta yukarı distopi ve retinanın alt bölgesinde makülaya taşmayan eksudatif retina dekolmanı mevcuttu. Klinik muayene ve görüntüleme yöntemleri ile maksiller sinüs tümörü şüphesi ile kulak-burun-boğaz hastalıkları bölümü tarafından operasyon uygulandı. Postoperatif birinci gün oküler distopi tamamen düzeldi retinal eksudasyon hala mevcuttu. Sonuç olarak, maksiller sinus mukoseli diploji olmaksızın oküler distopi ve eksudatif retina dekolmanı gibi bulgulara yol açabilir ve klinik bulgular tümörü taklit edebilir.

Anahtar Kelimeler: Diploji; mukosel; retina dekolmanı

Mucocele is a benign, cystic lesion covered internally with respiratory tract epithelium developing when the drainage of normal paranasal sinus secretions is obstructed due to infection, trauma and occasionally tumors. Although it is a benign lesion, it can expand and gradually erode the bony walls of the sinuses.^{1,2} The lesion can originate from all paranasal sinuses however most mucoceles are resulted from the

frontal and anterior ethmoid sinuses. Maxillary sinus mucocele comprises 3-10% of all cases.³ The majority of mucoceles (70%) occur in adults (aged 40-70 years). The incidence of mucoceles in the general population is 0.4-0.8%.⁴ In this case report, clinical findings of a maxillary sinus mucocele case that eroding inferior orbital bone were presented.

CASE REPORT

A 43-year old woman applied to ear-nose-throat clinic with swelling of right lower eyelid and right malar region. The patient was referred to eye clinic with the initial diagnosis of orbital invasion of maxillary tumor. The patient stated that the swelling of right lower eyelid was present for 1 year however got worsed-within last 3 months (Figure 1). She had undergone functional endoscopic sinus surgery (FESS) 22 years ago. Relative afferent pupillary defect was absent. The ocular movements were normal except restriction of downgaze in the right eye and diplopia was not

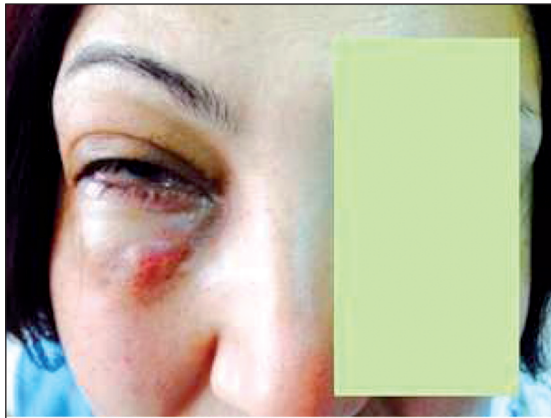

FIGURE 1: Ocular dystopia and swelling on the right malar region.

present. Diplopia and eye movements were evaluated by subjective method. Snellen visual acuity was 6/6 in both eyes. There was no difference in the measurements of exophthalmometry 16 mm in both eyes. Intraocular pressure (IOP) was 22 mmHg in the right eye and 10 mmHg in the left eye. Biomicroscopic examination was normal. In the right eye, fundus examination revealed subretinal folds in the macular region (Figure 2a). Exudative retinal detachment was detected in the inferior 1/3 part of the retina (Figure 2b). Optic disc was normal. In the left eye funduscopy was normal (Figure 3). The right-eye B-scan ultrasonography (USG) was performed, thus solid lesion was excluded and exudative retinal detachment (RD) at the inferior quadrant of the retina was confirmed. Because the initial diagnosis was maxillary sinus tumor, cranial and orbital magnetic resonance imaging (MRI) was performed in ear, nose and throat (ENT) clinic. MRI revealed a mass adjacent to inferior rectus muscle and inferior bulbus oculi that completely reducing right maxillary sinus aeration, eroding maxillary sinus and inferior orbital bone, and pushing bulbus oculi to upward. These findings suggested to us that it could be an invasive tumor mass (Figure 4a-b). The patient was prepared to surgery with the initial diagnosis of maxillary tumor. Informed consent was obtained from the patient. Under general anesthesia, maxillary sinus was reached via an incision through the right gingivo-buccal junction. Maxillary sinus was filled with purulent material and it was completely drained. The biopsy report confirmed benign cystic inflammatory mass consistent with mucocele. In the superior part of the lesion 1

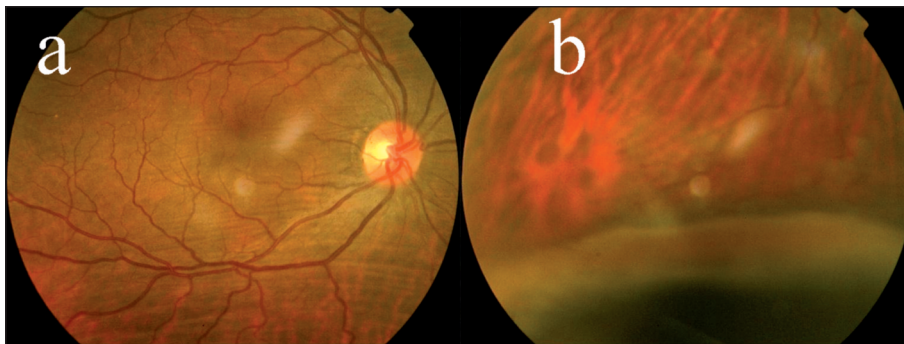


FIGURE 2: a) Subretinal folds resulting from compression of the right orbit. b) In the right eye, inferior exudative retinal detachment due to compression.

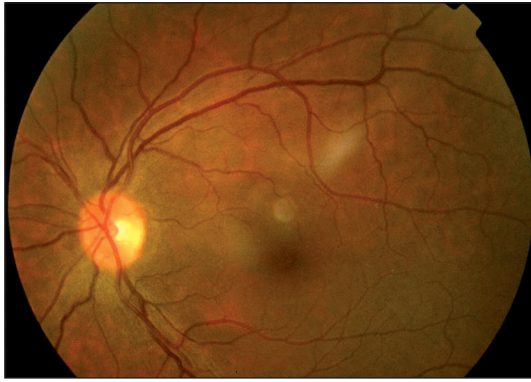


FIGURE 3: Normal fundus photo of the left eye.

cm bone defect was present in the inferior orbital wall. During the operation, bulbus oculi replaced its normal position immediately after drainage. Force duction test was negative in all the cardinal directions of gaze. Reconstruction of inferior orbital wall was not performed because of the small size of the defect, intact orbital septum and no displacement of orbital structures into maxillary sinus. In the first postoperative day, restriction of downgaze in the right eye was improved; however, diplopia developed in the primary position (Figure 5). In the postoperative first week diplopia disappeared. However, the area of exudative retinal detachment was still present. Since the patient resided outside the province, she did not come to her control examinations after the first week and we could not follow the retinal detachment.

DISCUSSION

Although mucoceles are benign lesions they may spread from one paranasal sinus to another and compress globe and optic nerve after eroding orbital bones and invading the orbit.¹⁻⁵ Patients usu-

ally apply to ophthalmologist with headache, proptosis, dystopia and diplopia at adult age. Pain is unusual except secondary infection. Computed tomography (CT) may show opacification in involved paranasal sinuses with dehiscence and destruction in bone septae. The content of the cyst may exhibit various amount of density. Treatment is total excision and restoration of drainage of the paranasal sinuses.¹⁻⁵

The most common cause of mucocele originating from the maxillary sinus is trauma: accidental or iatrogenic.⁶ A previous medical history is important in such patients. Khong et al. stated that 93% of the patients had had former sinus surgery and 80% of the patients had chronic sinusitis in their study.⁷ In the literature, postoperative maxillary sinus mucocele development has been reported even after 10-19 years the operation.⁷⁻⁹ Our patient stated that she underwent endoscopic sinus surgery 22 years before. The diagnosis of mucocele is based on symptoms, imaging, surgical exploration and histological confirmation. The most consistent symptom is dull facial pain and sensitivity. Other symptoms include swelling and/or numbness of the cheek, nasal obstruction, proptosis, double vision, ptosis, epiphora, optic nerve dysfunction with reduced vision and dental problems.^{3-5,9} High-resolution CT scan shows homogenous lesions, which are isodense with brain and no contrast intensification, unless infected. There are clear-cut margins of bone erosions occurring in the sinus walls. In malignancy, the mass is likely to be irregular in shape, with erosion and destruction of sinus walls. In sinusitis or retention cyst, there is no bone destruction.⁹



FIGURE 4: a) The magnetic resonance imaging of T1-W axial with fat suppression. Orbital invasion is seen on the right side. b) The magnetic resonance imaging of T2-W coronal section. This picture exhibit a mass completely filling right maxillary sinus and pushing up bulbous oculi.




FIGURE 5: In the first postoperative day, restriction of downgaze in the right eye was improved.

When the maxillary sinus mucocele cases published in the literature are reviewed, it is seen that ocular displacement is frequently accompanied by diplopia.^{4-5,9-11} In the case of maxillary sinus mucocele with diplopia reported by Sheth and Goel, the patient had a swelling story in the malar region and around the lower eyelid for two weeks.¹¹ In the case of Raman, the first complaint of the patient was facial numbness and vaguely transient double vision, and he was followed by neurology with the diagnosis of trigeminal neuralgia for several months.⁵ In this second case, diplopia suddenly emerged with an increase in proptosis and a limitation in ocular movements. In fifteen mucocele case series published by Wang et al., despite the presence of proptosis in 10 cases, development of diplopia has been reported in only 5 patients.¹² In our case, she did not have diplopia in primary position or in other directions despite excessive globe dystopia was present. The absence of a diplopia complaint in our case could be the resulted of slow progression of mucocele and ocular displacement. In contrast, diplopia was occurred in the first postoperative day when the globe attained its normal position. The cause triggering postoperative diplopia may be a dramatically improvement of ocular dystopia in the eye that has adapted to its previous position. In addition, covering the pupil due to deprivation of the right eye resulting from edema in the eyelids and completely restriction of downward gaze may have prevented developing of diplopia.

In the literature review, we could not find any article about development of exudative retinal detachment related to maxillary sinus mucocele. However, in the book 'Ocular Differential Diagnosis' written by Ray the inflammation of the orbit and sinuses is shown among the causes leading to exudative RD.¹³ We could not follow the course of clinical findings in our case after the first week. In spite of the ocular dystopia and the pressure have completely disappeared on the postoperative first day and first week ophthalmic examination we observed that exudative RD began to diminish but still continued. The distinguishing features of our case are presence of exudative RD and lack of diplopia despite excessive ocular dystopia. These clinical findings also suggest that this case may be a malignant maxillary sinus tumor.

As far as we know, a maxillary sinus mucocele case leading to exudative RD has not been presented until now. As a result, maxillary sinus mucocele is a rare form and may occur with various clinical presentations. It can imitate malignant tumors expanding into the orbit. Although this is confusing for clinicians to diagnose, mucocele disease should always kept in mind.

Source of Finance

During this study, no financial or spiritual support was received neither from any pharmaceutical company that has a direct connection with the research subject, nor from a company that provides or produces medical instruments and materials which may negatively affect the evaluation process of this study.

Conflict of Interest

No conflicts of interest between the authors and / or family members of the scientific and medical committee members or members of the potential conflicts of interest, counseling, expertise, working conditions, share holding and similar situations in any firm.

Authorship Contributions

Idea/Concept: Serpil Yazgan, Sultan Bişkin; **Design:** Serpil Yazgan; **Control/Supervision:** Suat Hayri Uğurbaş; **Data Collection and/or Processing:** Serpil Yazgan, İrem Işık; **Analysis and/or Interpretation:** Serpil Yazgan, Sultan Bişkin, Orhan Ayar; **Literature Review:** Mehmet Orçun Akdemir; **Writing the Article:** Serpil Yazgan; **Critical Review:** Suat Hayri Uğurbaş.

REFERENCES

1. Yanoff M, Duker JS. *Orbits and oculoplastics. Ophthalmology*. 3rd ed. China: Mosby Elsevier; 2009. p.1462.
2. Kanski JJ, Bowling B. Orbit. In: Nischal K, Pearson A, eds. *Clinical Ophthalmology: A Systematic Approach*. 7th ed. Edinburgh, New York: Elsevier/Saunders; 2011. p.101.
3. Arrué P, Kany MT, Serrano E, Lacroix F, Percodani J, Yardeni E, et al. Mucocoeles of the paranasal sinuses: uncommon location. *J Laryngol Otol* 1998;112(9):840-4.
4. Yagüe-García J, España-Tost AJ, Berini-Aytés L, Gay-Escoda C. Treatment of oral mucocoele-scalpel versus CO2 laser. *Med Oral Patol Oral Cir Bucal* 2009;14(9):e469-74.
5. Raman S. Mucocoele of the maxillary sinus and the eye. *Eye (Lond)* 2003;17(1):101-4.
6. Atherino CC, Atherino TC. Maxillary sinus mucopyoceles. *Arch Otolaryngol* 1984;110(3):200-2.
7. Khong JJ, Malhotra R, Wormald PJ, Selva D. Endoscopic sinus surgery for paranasal sinus mucocoele with orbital involvement. *Eye (Lond)* 2004;18(9):877-81.
8. Sharp JF. Non-axial proptosis without diplopia secondary to maxillary pyomucocoele. *J R Soc Med* 1989;82(8):506-7.
9. Jayaraj SM, Patel SK, Ghufloor K, Frosh AC. Mucocoeles of the maxillary sinus. *Int J Clin Pract* 1999;53(5):391-3.
10. Natvig K, Larsen TE. Mucocoele of the paranasal sinuses. A retrospective clinical and histological study. *J Laryngol Otol* 1978;92(12):1075-82.
11. Sheth HG, Goel R. Diplopia due to maxillary sinus mucocoele. *Int Ophthalmol* 2007;27(6):365-7.
12. Wang TJ, Liao SL, Jou JR, Lin LL. Clinical manifestations and management of orbital mucocoeles: the role of ophthalmologists. *Jpn J Ophthalmol* 2005;49(3):239-45.
13. Ray FH. *Syndromes and diseases associated with retinal detachment and retinal folds. Ocular Differential Diagnosis*. 9th ed. USA: Jaypee Highlights Medical Publishers; 2012. p.381-3.