

Sedation with Ketamine, Propofol or Sevoflurane for Pediatric Patients Undergoing Magnetic Resonance Imaging: An Observational Study

Pediyatrik Manyetik Rezonans Görüntülemesinde Ketamin, Propofol veya Sevofluran ile Sedasyon: Gözlemsel Çalışma

Demet ALTUN,^a
Tülay ÖZKAN SEYHAN,^a
Giray VARANSU,^a
Ali Emre ÇAMCI^a

^aDepartment of Anesthesiology and Reanimation, Istanbul University, Istanbul Faculty of Medicine, Istanbul

Geliş Tarihi/Received: 31.03.2016
Kabul Tarihi/Accepted: 09.06.2016

Yazışma Adresi/Correspondence:
Demet ALTUN
Istanbul University
Istanbul Faculty of Medicine,
Department of Anaesthesiology and Reanimation, Istanbul,
TÜRKİYE/TURKEY
drdemetaltun@hotmail.com

ABSTRACT Objective: Sedation is necessary frequently needed in children undergoing magnetic resonance imaging (MRI) to avoid motion. The purpose of present observational cross-sectional study is to investigate the success of three different sedation regimens including ketamine, propofol and sevoflurane in a mixture of 50% nitrous oxide-oxygen which are routinely used in our institution for pediatric sedation during MRI following midazolam premedication. **Material and Methods:** Three hundred and seventy children (age 0-14 year) were enrolled to the study. Sedation was achieved in 125 children with ketamine, in 130 children with propofol and in 115 children with sevoflurane in a mixture of 50% nitrous oxide-oxygen. Comparison was performed among the groups for number of failures by excessive movements, numbers of rescue, adverse effects, sedation time and recovery time. Descriptive and parametric statistics (ANOVA) were utilized to look for significant differences. **Results:** Children were similar in demographic characteristics. The comparison of three regimens in term of success according to the movements affecting imaging and requirement for rescue drug showed that minimal mobility which affects imaging and requires less rescue drug was achieved with sevoflurane in a mixture of 50% nitrous oxide-oxygen rather than propofol and ketamine. Although during MR imaging patients in Group ketamine required fewer numbers of rescue intervention to resolve the respiratory problems, desaturation by opening the airway by repositioning the head and neck and increasing the oxygen supply than the other two groups, rescue drug requirement was found more than Sevoflurane group. **Conclusion:** In this study three different sedation regimens were compared according to the mobility which affects imaging and rescue for drug requirement and Sevoflurane in a mixture of 50% nitrous oxide-oxygen -based MRI sedation regimen in children is associated with lower movement, lower requirement for rescue drug, less side effects and higher success compared to ketamine and propofol.

Key Words: Diffusion magnetic resonance imaging; conscious sedation; ketamine; propofol; sevoflurane

ÖZET Amaç: Çocuklarda Manyetik Rezonans (MR) çekimi sırasında hareketi önlemek amacıyla sıklıkla sedasyona ihtiyaç vardır. Bu gözlemsel kesitsel çalışmanın amacı, kurumumuzda MR görüntüleme esnasında midazolam premedikasyonunu takiben çocukların sedasyonunda rutin olarak kullandığımız Ketamin, Propofol ve Sevofluran+%50 nitroz oksit-oksijen kombinasyonu içeren üç farklı sedasyon rejiminin başarısını araştırmaktır. **Gereç ve Yöntemler:** Çalışmaya 0-14 yaş arası 370 çocuk dahil edildi. Oral midazolam premedikasyonunu takiben, çocukların 125'inde sedasyon iv. Ketamin (K), 130'unda iv. Propofol (P), ve 115'inde Sevofluran (S) + %50 nitroz oksit-oksijen kombinasyonu ile sağlandı. Gruplar arası karşılaştırmada ve uygulanan sedasyon rejiminin başarısını belirlemede, hastanın çekim sırasındaki hareket etme sayısı, müdahale gereksinim sayısı, yan etkiler, sedasyon zamanı ve derlenme zamanı değerlendirilmeye alındı. Gruplar arasındaki anlamlı farklılıklara bakmak için tanımlayıcı ve parametrik (ANOVA) istatistik kullanıldı. **Bulgular:** Çocukların demografik özellikleri benzer bulunmuştur. Çekim esnasında en az hareketlilik Sevofluran + %50 nitroz oksit-oksijen kombinasyonu ile sağlanıp Propofol ve Ketamin gruplarına kıyasla çekim daha az etkilenmiş ve daha az ek ilaç gereksinimi olmuştur. Çekim esnasında desatürasyon nedeniyle baş-boyun pozisyonuna müdahale etme gereksinimi Ketamin grubunda diğer iki gruba kıyasla daha az bulunmuştur. Ayrıca Sevofluran grubu, ajitasyon hariç daha az yan etki ile ilişkili bulunmuştur. **Sonuç:** Çocukların MR çekimi esnasında, Ketamin ve Propofol ile karşılaştırıldığında Sevofluran bazlı sedasyon rejiminin; daha az hareketlilik, daha az ilaç müdahalesi, daha düşük yan etki ve sonuçta daha yüksek başarı ile ilişkili olduğu gösterilmiştir.

Anahtar Kelimeler: Difüzyon manyetik rezonans görüntüleme; bilinçli sedasyon; ketamin; propofol; sevofluran

doi: 10.5336/anesthe.2016-51591

Copyright © 2016 by Türkiye Klinikleri

Türkiye Klinikleri J Anest Reanim 2016;14(3):90-7

Magnetic resonance imaging (MRI) despite being a painless procedure requires absolute immobility for good quality images, which is difficult to achieve in the pediatric population without sedation. Noisy and closed environment of the MRI unit further demands deep sedation, or even general anaesthesia.¹⁻³ Sedating children with serious systemic disorders or congenital malformations may cause severe undesirable events.^{4,5} Although an ideal sedation regimen for this population is still a matter of debate, the goal of the anaesthetic approach for the MRI unit can be summarized as follows: obtaining the desired sedation level in a smooth and rapid manner, an acceptable level of immobility allowing a good image quality, and fast emergence and discharge times with minimal cardiorespiratory side effects. Several sedation regimens based on inhalational or intravenous technique are available, and these have variable advantages and risks.^{6,7}

The purpose of this prospective observational study is to investigate the success of three different sedation regimens that are routinely used in our institution for pediatric sedation during MRI, including ketamine, propofol and sevoflurane, following midazolam premedication. Success was defined according to immobility and need for additional anaesthetic. Sedation time, induction time, discharge time and side effects were further outcomes.

MATERIAL AND METHODS

STUDY POPULATION AND SETTING

After obtaining Institutional Ethics Committee approval and parental written consent, American Society of Anaesthesiologists (ASA) I-II status 370 children requiring an elective cranial, spinal, or combined cranio-spinal MR imaging were included in this observational study during a 13-month period. All children were fasted for 4 and 6 h for clear liquids/breast milk and solid food, respectively. Our routine protocol consists of premedication with oral midazolam followed by 3 different sedation regimens utilizing either intravenous ketamine (K) (n=125), propofol (P)

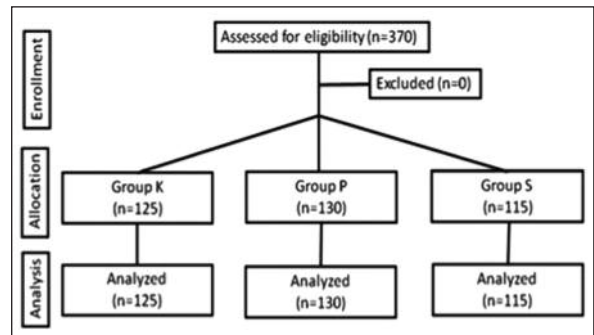


FIGURE 1: Study flow diagram.

(n=130) or sevoflurane (S) (n=115) inhalation, which was selected by two consultant anaesthesiologists during the pre-interventional evaluation (Figure 1). Intravenous agents were selected predominantly in patients at risk for malignant hyperthermia and whereas ketamine was chosen predominantly in cases with anatomical airway abnormalities and propofol in patients with the risk of intracranial pressure elevation. Sevoflurane was chosen predominantly in children with hyperreactive airway and in infants.

The children were transferred to the MRI unit 20 min after oral premedication (midazolam, 0.5 mg kg⁻¹), whereupon a peripheral venous cannula was inserted and IV atropine (0.015 mg kg⁻¹) was injected. Normal saline was initiated for vein patency. Standard monitoring was performed including 3-lead ECG, pulse oxymetry and non-invasive blood pressure measurement (3150 MRI Magnitude, In Vivo Research Inc. USA). The children were sedated according to one of the three predetermined sedation regimens.

All patients in Group K and P inhaled 50% oxygen via a facemask adapted to an MRI-compatible anaesthesia machine (Aestiva 5/MRI, Datex-Ohmeda, GE Corp., Germany) with a fresh gas flow of 3–5 L min⁻¹. In Group K, IV ketamine (1 mg kg⁻¹) was administered followed by bolus doses of 0.5 mg kg⁻¹ every 15 min. In Group P, IV propofol (1 mg kg⁻¹) was used followed by bolus doses of 0.5 mg kg⁻¹ every 10 min. The 1% propofol contained lidocaine (2 mg mL⁻¹) to prevent injection pain. In Group S, 8% sevoflurane was

administered and was maintained with 2–4% sevoflurane in a mixture of 50% nitrous oxide-oxygen via facemask. If the image quality was affected by excessive movements due to insufficient sedation, ketamine (0.25 mg kg^{-1}) or propofol (0.5 mg kg^{-1}) was given in Group K or P, respectively, and the inspiratory concentration of sevoflurane in a mixture of 50% nitrous oxide-oxygen was increased up to 5–6% in Group S for rescue. After completion of the imaging procedure, the patients were taken to the recovery room for observation until they were ready for discharge. The following discharge criteria were used: the child regained pre-procedural neuro-mental status, the child was conscious with stable cardiovascular and respiratory conditions, and the child was sitting and communicating if the age and pre-procedural status was appropriate.

DATA COLLECTION

The success of the sedation was assessed according the following scale: **0** = sufficient sedation, the patient is immobile, and no additional drug is required; **1**= minimal mobility, imaging is not affected, and no rescue drug is required; **2** = mobility causing artefact, imaging is affected, and rescue drug is required; and **3** = sedation is completely insufficient, imaging is stopped, and more than one rescue is required. The need for a rescue intervention (repositioning head and neck for opening the airway to resolve the respiratory problem such as apnoea, desaturation) was recorded.

Heart rate (HR), mean arterial pressure (MAP), and peripheral oxygen saturation (SpO_2) values during the study period recorded before, at the beginning, and at the end of imaging; furthermore, the lowest and highest values were noted. Nausea, vomiting, and agitation during the awakening period were recorded. Agitation was assessed 5 minutes after eye opening using four point agitation scale (1= awake and calm, cooperative; 2= crying, requires consoling; 3= irritable/restless, screaming, inconsolable; 4= combative, disoriented, thrashing) and a score more than one was accepted as agitation).

A drop in the MAP of greater than 20% compared to the baseline was defined as hypotension and was treated by diminishing the sedation level and providing additional fluid infusion if the drop continued for more than 5 min. Hypertension and tachycardia were defined as an increase in the MAP and HR, respectively, of greater than 20% compared to the baseline, and both were treated by deepening the sedation level. Finally, bradycardia was defined as a decrease of HR greater than 20% compared to the baseline, and was treated with atropine (0.01 mg kg^{-1}). Holding the breath for over 20 s was detected by the monitor and defined as apnoea, whereas peripheral desaturation was described as a fall in SpO_2 values below 90%. Head repositioning with an increased extension level, airway insertion and increasing inspired oxygen fraction was performed in these cases. When serious airway obstruction was observed, bag-mask ventilation and laryngeal mask airway placement was performed after deepening the anaesthetic level. An oro-tracheal intubation technique was planned with neuromuscular blocking agents as a final solution. The incidence of hemodynamic (tachycardia, bradycardia, and hypotension) and respiratory (apnoea and peripheral desaturation) events were recorded.

The period from the beginning of sedation until the start of the imaging was defined as the induction time and the period from the end of induction to the end of imaging was defined as the sedation time. Finally, the period from eye opening until the child was ready for discharge was defined as the recovery time. All of these times were recorded.

STATISTICAL ANALYSES

Demographic data and number of rescues were given as median [minimum-maximum] and compared with Kruskal-Wallis test. Induction, sedation, recovery times were expressed as mean \pm standart deviation and analysed using ordinary ANOVA and Dunnett's test for post hoc comparison. Type of MRI, sedation success score and side effects were given as number (percent)

and analysed with the chi-square test. P value <0.05 was considered significant.

RESULTS

During the study period, 370 children (ages 0-14) were enrolled. Sedation was achieved with ketamine in 125 children, with propofol in 130 children, and with sevoflurane in a mixture of 50% nitrous oxide-oxygen in 115 children.

The demographic data and the types of imaging were not significantly different between the three groups (Table 1).

Patients in Group K required fewer numbers of rescue (repositioning head and neck for opening the airway) than the other two groups (Table 2).

The lengths of induction, sedation and recovery are summarized in Table 2. Shortest induction and recovery time was detected in Group P. The three groups showed similar characteristics in terms of sedation times.

The HR and MAP data are presented in Figures 2 and 3. Heart rate values at the end of induction were significantly lower in Group S compared to Group K. When comparing the highest HR values recorded during the study period, this value was significantly different in Group S compared with the other two groups, while no significant difference was found between the three groups when the lowest and end-MRI HR values were compared. Significantly lower MAP values were observed in Group P compared to the other two groups at the end of induction and MRI. Same significance was detected also for highest and lowest MAP values.

The statistical analysis of the SpO₂ data revealed no significant differences between the groups during the entire study period.

The incidence of desaturation between the groups was not statistically different, but the patients in Group P experienced significantly more apnoea (p=0.04). In all cases, the problem lasted for a very short period and was resolved by opening the airway by repositioning the head and neck and increasing the oxygen supply in the fresh gas flow. Severe respiratory depression occurred in two patients in Group K and one patient in Group S, and these patients were ventilated by using a bag-mask and were finally equipped with a laryngeal mask airway. None of the patients in Group P experienced severe respiratory depression requiring such an intervention. Among the circulatory side effects, hypotension (n=40) and

TABLE 1: Demographic data and type of imaging modalities.

	Group K (n=125)	Group P (n=130)	Group S (n=115)
Age (yrs)	4 (1-14)	4 (0-13)	4 (0-13)
Weight (kg)	16 (7-56)	15 (6-35)	13 (8-50)
Height (cm)	102.5 (43-144)	103 (55-137)	95 (64-140)
Type of MRI (Cranial/Spinal/Cranial+Spinal)	107/6/12	112/10/8	93/18/14

Data are given as median (min-max) and number of patients.

TABLE 2: Recorded time intervals and success.

	Group K (n=125)	Group P (n=130)	Group S (n=115)	p
Success score 0	67 (53.6%)	73 (56.2%)	105 (91.3%)	<0.001
1	15 (12%)	12 (9.2%)	3 (2.6%)	
2	40 (31%)	38 (29.2%)	7 (6.1%)	
3	3 (2.4%)	7 (5.4%)	0	
Number of rescue	0 (0-2)	0 (0-3)**	0 (0-3)**	<0.001
Induction time (sec)	105.2 (10)	56±31.2**	135.7±34.5**,#	<0.001
Sedation time (min)	26.1±7.9	27.2±11.1	24.4±9.2	NS
Recovery time (min)	40±14.1	36.1±12.3*	38.7±10.5	0.032

Data are given as median (min-max) or mean (SD) and number of patients.

*p=0.032 when compared to Group K, **p<0.001 when compared to Group to Group K, #p<0.001 when compared to Group P.

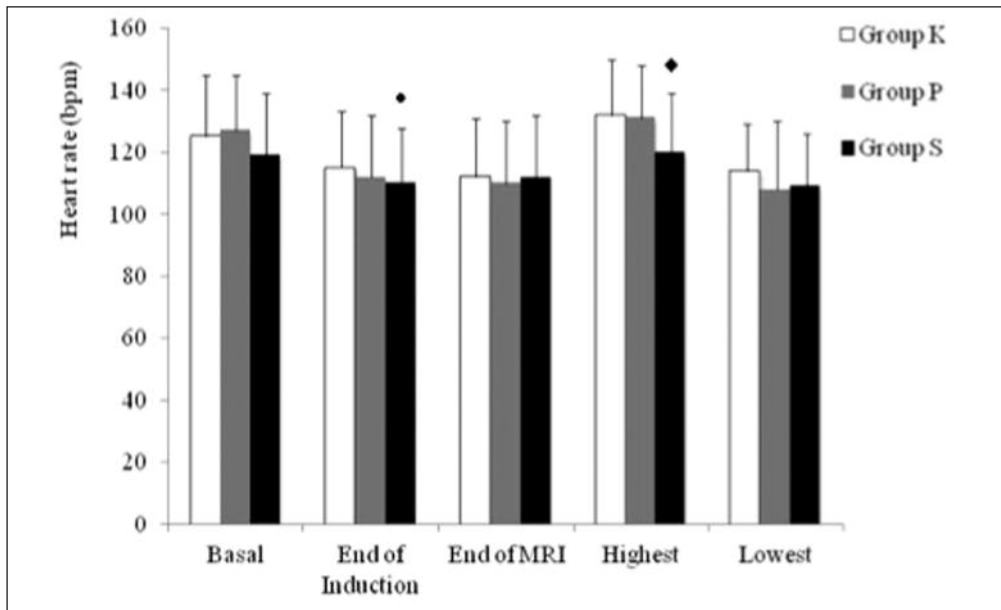


FIGURE 2: Heart rate values measured before sedation (basal), at induction, at the end of MRI, highest and lowest values measured during the procedure.

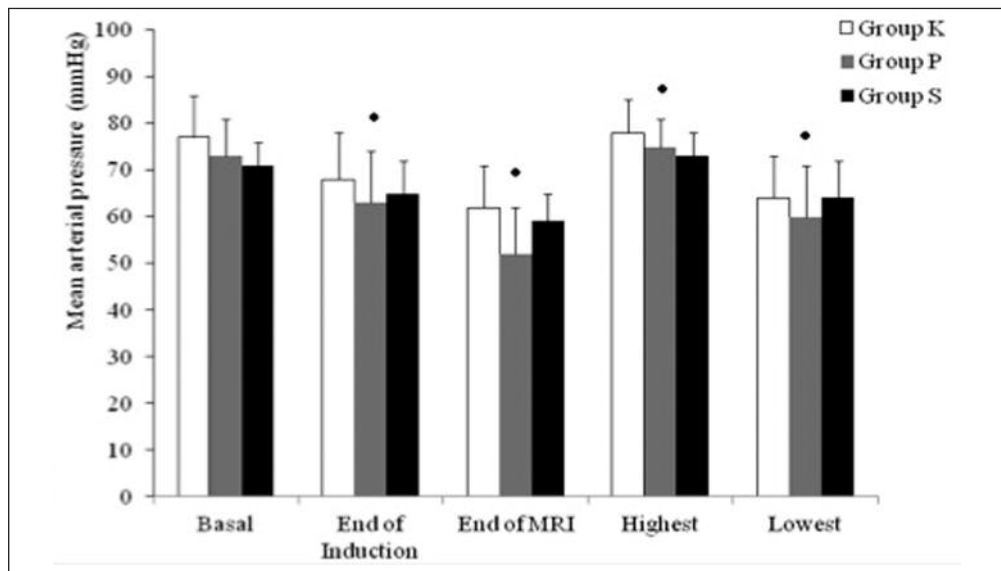


FIGURE 3: Mean arterial pressure values measured before sedation (basal), at induction, at the end of MRI, highest and lowest values measured during the procedure values.

bradycardia (n=20) were observed significantly more frequent in Group P, whereas tachycardia was observed more frequently in Group S (n=14) and Group K (n=10).

During the recovery period, sevoflurane in a mixture of 50% nitrous oxide-oxygen sedation was associated with significant agitation compared to ketamine and propofol. On the other

hand, patients who received ketamine sedation experienced more nausea and vomiting. Finally, two patients in Group K experienced convulsion during cranial imaging, and were successfully treated by intravenous midazolam (0.05 mg kg^{-1}).

The incidence of side effects observed during the study period is shown in Table 3.

TABLE 3: Side effects.

	Group K (n=125)	Group P (n=130)	Group S (n=115)	p
Desaturation	5 (4%)	8 (6.2%)	6 (5.2%)	NS
Apnea	5 (4%)	15 (11.5%)	6 (5.2%)	0.041
Hypertension	3 (2.4%)	0	0	0
Hypotension	7 (5.6%)	40 (30.8%)	5 (4.3%)	<0.001
Tachycardia	10 (8%)	1 (0.8%)	14 (12.2%)	0.001
Bradycardia	3 (2.4%)	20 (15.4%)	5 (4.3%)	<0.001
Nausea-vomiting	23	2	6	<0.001
Agitation	9	4	20	<0.001

Data were given as numbers (percents).

Written informed consent was obtained from parents of the children who participated in this case.

DISCUSSION

To our knowledge this is the first study comparing ketamine, propofol and sevoflurane in a mixture of 50% nitrous oxide-oxygen for sedation of children for MRI. In this prospective observational cross-sectional study, 370 pediatric patients were evaluated.

MRI is a superior imaging modality because of its high resolution and penetration characteristics, however increased sensitivity to body movements is a disadvantage of these features. Therefore, absolute immobility improves image quality and may shorten the duration of the procedure. In the study by De Sanctis, MRI was performed under sevoflurane sedation in 640 pediatric patients at 1.8 to 2% end-tidal concentrations, and an adequate level of sedation facilitating good image quality could be obtained without prolonging the procedure time in 98% of the cases.⁸ In another study, Sury et al. achieved successful sedation in 12 of 13 infants, with only one infant requiring general anaesthesia with intubation.⁹ Children sedated in our study with either propofol or ketamine had more body movements and a greater requirement for additional interventions. The reported incidence of inadequate sedation or the need for additional intervention during MRI sedation with ketamine or propofol is between 2

and 5% respectively.^{10,11} Our study yielded similar results, with a superior profile for sevoflurane in a mixture of 50% nitrous oxide-oxygen compared to the other two agents in terms of the sedation success score and requirement for rescue agent.

Propofol was associated with a higher frequency of hypotensive or bradycardic episodes, whereas ketamine and sevoflurane caused a significantly higher frequency of tachycardia. Hypotension, a well-known effect of propofol administration, was observed in 30% of our patients. However, none of these hypotensive episodes persisted or required specific treatment, and the lowest mean arterial blood pressure in the group (approximately 60 mmHg) was in the acceptable range for this age group. The reported frequencies of hypotensive episodes for propofol in similar studies vary between 6 and 42.5% with increased tendency during sedation interventions for MRI.^{12,13} The higher proportion of hypotensive episodes in the present study might have been the result of the criteria used to define hypotension, the absence of a standard propofol injection rate, or the use of intermittent bolus injections rather than continuous infusions. However, it should be noted that intermittent or continuous administration of propofol in children for MRI sedation did not result in significantly different rates of circulatory events in the study by Hassan et al.¹⁴

Undesired respiratory effects, which have been reported in 1 to 12% of patients for different agents in other MRI sedation studies, occurred at a similar frequency among our patients in the present study.¹⁵ The occurrence of arterial desaturation was about 5% and showed an equal distribution between groups; in contrast, apnoea was experienced in nearly 12% of propofol patients. The rate of apnoea was relatively high despite the use of low-dose propofol (1 mg/kg), but the problem was solved by head repositioning and did not reach a detrimental level for the patient. A wide range of respiratory depression starting from mild desaturation to the need for endotracheal intubation was caused by propofol in between 0 and 46% of cases in a previous study.¹⁶ The wide

variability in the reported incidence of respiratory effects is not surprising when the differences in the agents used, routes of administration and respiratory equipment in different centres are considered.

Agitation and delirium have been reported in 38% of the pediatric patients undergoing imaging studies with sevoflurane sedation.¹⁷ In our study, approximately 18% of the patients in the sevoflurane group experienced agitation during the arousal phase, but this was resolved within minutes without the requirement for any additional measures. Another problem during the recovery phase is nausea and vomiting, and these occurred more frequently in Group K. Similar to previous reports, propofol was superior to the other two agents in this regard because no patients in this group experienced nausea and/or vomiting during the recovery phase.

A sedation technique with a quick onset of action and recovery time is particularly suitable for MRI units with a high patient turnover. In this study, significantly shorter induction and recovery were achieved for propofol compared to the other agents. The induction time of 56 seconds for propofol in our patients was significantly shorter in comparison with the other two agents, which is similar to many other studies reporting an induction time of approximately one minutes for propofol.¹⁸ However, the contribution of propofol to improved patient turnover in the MRI room is debatable because this difference is unlikely to correspond to a clinically meaningful effect despite a statistically significant difference in arousal times.

An important limitation is the observational design of the study. Patients were sedated according to our institutional sedation protocols and the type of sedation was at the discretion of the consultant anaesthesiologists, who evaluated the child in the pre-anaesthesia clinic and also administered the sedation. The decision was made according anatomical or systemic disorders such as airway problems, cardiovascular or pulmonary disease, malign hyperthermia risk. Although not randomised, the study gives the chance to observe the comparison of three different sedation

methods. Randomization would strengthen our results. However this kind of patient allocation to groups was also reported in previous studies.^{3,19}

Another limitation is the bolus administrations of propofol instead of continuous infusion. This was due to the lack of non-magnetic infusion equipment in our department. Intermitant bolus administration of propofol could be a factor in the disadvantageous view of this agent in terms of the sedation quality and cardiorespiratory side effects. Cho et al. favored sedation using bolus doses of propofol for shorter recovery time compared to infusion doses.¹¹ In contrast to this method, Hassan et al. advocated continuous infusion of propofol as it may result lower consumption compared to bolus administration, but they could not observe difference in side effects.¹⁴ They used in both groups 2-4 mg/kg propofol for induction. In our study induction dose of propofol was 1 mg/kg and sedation was maintained with 0.5 mg/kg every 10 minutes. Despite the low total propofol dose, we observed a high incidence in side effects in propofol group which may be attributed to premedication. Midazolam premedication is reported as a predictor of respiratory events during propofol sedation in children.²⁰

Regarding undesired events, propofol was more frequently associated with apnoeic, hypotensive, or bradycardic episodes, patients in Group S were more likely to experience agitation during the arousal phase, and a higher proportion of patients in the ketamine group had nausea and vomiting during recovery.

CONCLUSION

In this study, according to our application procedure, the comparison of the three regimens in terms of success showed that Sevoflurane in a mixture of 50% nitrous oxide-oxygen -based MRI sedation regimen in children is associated with higher success rather than propofol and ketamine respectively and lower requirement for rescue intervention (less movements and need for rescue agents) compared to ketamine and propofol. It is also related with less side effects except agitation.

REFERENCES

- Formica D, Silvestri S. Biological effects of exposure to magnetic resonance imaging: an overview. *Biomed Eng Online* 2004;3(22):11.
- Shellock FG, Crues JV 3rd. MR safety and the American College of radiology white paper. *AJR Am J Roentgenol* 2002;178(6):1349-52.
- Malviya S, Voepel-Lewis T, Eldevik OP, Rockwell DT, Wong JH, Tait AR. Sedation and general anaesthesia in children undergoing MRI and CT: adverse events and outcomes. *Br J Anaesth* 2000;84(6):743-8.
- Gozal D, Drenger B, Levin PD, Kadari A, Gozal Y. A pediatric sedation/anaesthesia program with dedicated care by anesthesiologists and nurses for procedures outside the operating room. *J Pediatr* 2004;145(1):47-52.
- Weissend EE, Litman RS. Pediatric anaesthesia outside the operating room. *Curr Opin Anaesthesiol* 2001;14(4):437-40.
- Hubbard AM, Markowitz RI, Kimmel B, Kroger M, Bartko MB. Sedation for pediatric patients undergoing CT and MRI. *J Comput Assist Tomogr* 1992;16(1):3-6.
- Bluemke DA, Breiter SN. Sedation procedures in MR imaging: safety, effectiveness, and nursing effect on examinations. *Radiology* 2000;216(3):645-52.
- De Sanctis Briggs V. Magnetic resonance imaging under sedation in newborns and infants: a study of 640 cases using sevoflurane. *Paediatr Anaesth* 2005;15(1):9-15.
- Sury MR, Harker H, Thomas ML. Sevoflurane sedation in infants undergoing MRI: a preliminary report. *Paediatr Anaesth* 2005;15(1):16-22.
- Green SM, Denmark TK, Ciine J, Roghair C, Abd Allah S, Rothrock SG. Ketamine sedation for pediatric critical care procedures. *Pediatr Emerg Care* 2001;17(4):244-8.
- Cho JE, Kim WO, Chang DJ, Choi EM, Oh SY, Kil HK. Titrated propofol induction vs. continuous infusion in children undergoing magnetic resonance imaging. *Acta Anaesthesiol Scand* 2010;54(4):453-7.
- Seigler RS, Avant MG, Gwyn DR, Lynch AL, Golding EM, Blackhurst DW, et al. A comparison of propofol and ketamine/midazolam for intravenous sedation of children. *Paediatr Crit Care Med* 2001;2(1):20-3.
- Vespasiano M, Finkelstein M, Kurachek S. Propofol sedation: intensivists' experience with 7304 cases in a children's hospital. *Pediatrics* 2007;120(6):e1411-7.
- Hassan NE, Betz BW, Cole MR, Wincek J, Reischman D, Sanfilippo D, et al. Randomized controlled trial for intermittent versus continuous propofol sedation for pediatric brain and spine magnetic resonance imaging studies. *Pe-diatr Crit Care Med* 2011;12(6):e262-5.
- Cravero JP, Blike GT. Review of pediatric sedation. *Anesth Analg* 2004;99(5):1355-64.
- Tith S, Lalwani K, Fu R. Complications of three deep sedation methods for magnetic resonance imaging. *J Anaesthesiol Clin Pharmacol* 2012;28(2):178-84.
- Sandner-Kiesling A, Schwarz G, Vicenzi M, Fall A, James RL, Ebner F, et al. Side-effects after inhalational anaesthesia for paediatric cerebral magnetic resonance imaging. *Paediatr Anaesth* 2002;12(5):429-37.
- Uezono S, Goto T, Terui K, Ichinose F, Ishiguro Y, Nakata Y, et al. Emergence agitation after sevoflurane versus propofol in pediatric patients. *Anesth Analg* 2000;91(3):563-6.
- Kannikeswaran N, Sethuraman U, Sivaswamy L, Chen X, Mahajan PV. Children with and without developmental disabilities: sedation medication requirements and adverse events related to sedation. *Pediatr Emerg Care* 2012;28(10):1036-40.
- Srinivasan M, Turmelle M, Depalma LM, Mao J, Carlson DW. Procedural sedation for diagnostic imaging in children by pediatric hospitalists using propofol: analysis of the nature, frequency, and predictors of adverse events and interventions. *J Pediatr* 2012;160(5):801-6.