

Inhaled Colistin Use for Multi-Drug Resistant Gram-Negative Pneumonia in an Immunocompromised Patient: Case Report

Çok İlaça Dirençli Gram Negatif Pnömonili ve İmmünkompromise Bir Hastada İnhalasyon Yoluyla Kolistin Kullanımı

Figen ATALAY,^a
Aylin ÖZSANCAK UĞURLU,^b
Funda TİMURKAYNAK^c

Departments of

^aHematology,

^bPulmonary Medicine,

^cClinical Infectious Diseases,

Başkent University İstanbul Medical and
Research Center, İstanbul

Geliş Tarihi/Received: 19.11.2013

Kabul Tarihi/Accepted: 08.05.2014

Yazışma Adresi/Correspondence:

Figen ATALAY

Başkent University İstanbul Medical and

Research Center,

Department of Hematology, İstanbul,

TÜRKİYE/TURKEY

f_noyan@yahoo.com

ABSTRACT Patients with hematological malignancies are at high risk of hospital acquired infections. We report our successful experience of combined aerosolized and intravenous colistin use in a patient with hematologic malignancy and pneumonia caused by multi drug resistant (MDR) *Pseudomonas aeruginosa*. High dose methotrexate and cytarabine regimen was applied to a patient who diagnosed as Mantle cell lymphoma. At 7th day of chemotherapy (CT) he developed neutropenic fever and sepsis, required ventilatory support, treated for pneumonia caused by *Candida* spp. and improved. 5 days after his transfer to wards, he had diarrhea and fever together with neutropenia continued for 10 days, and subsequently developed hospital-acquired pneumonia confirmed by chest X ray and computerized tomography of the chest (55th day of CT). Sputum culture revealed MDR *P. aeruginosa*. Intravenous colistin and meropenem was started. Since his clinical condition did not improve after seven days of management, inhaled colistin was added-on. After 15 days of treatment with this regimen, pneumonia and sepsis regressed and he was discharged. Prolonged neutropenia and mechanical ventilation use increase the risk of lower respiratory tract infections due to *Pseudomonas* spp. Aerolized colistin therapy concomitant with intravenous form is the current option for a successful treatment of infections due to these difficult to treat pathogens, resistant to most of the drugs except for colistin.

Key Words: Pseudomonas; neutropenia; immunocompromised host; pneumonia, bacterial; colistin

ÖZET Hematolojik maligniteleri olan hastalar, hastane kökenli enfeksiyonlar açısından risk altındadırlar. Hematolojik malignitesi olan ve çok ilaca dirençli (ÇİD) *Pseudomonas aeruginosa*'ya bağlı pnömoni gelişen bir hastanın inhale ve intravenöz yolla verilen kolistin ile başarıyla tedavi edilmesini sunuyoruz. Relaps Mantle hücreli lenfoma tanısı olan hastaya yüksek doz metotreksat ve sitarabin kemoterapi protokolü uygulandı. Kemoterapinin 7. gününde hastada nötrojenik ateş ve sepsis gelişti, solunum desteğine ihtiyacı oldu. *Candida* spp.'e bağlı pnömoni için tedavi edildi. İyileşip servise alındıktan beş gün sonra hastanın ishal ve ateş ile 10 güne uzayan nötrojenisi oldu. Akciğer grafi ve bilgisayarlı tomografi ile tanısı desteklenen hastane kökenli pnömoni gelişti (KT'nin 55. günü). Balgam kültüründe ÇİD *P. aeruginosa* üremesi görüldü. Hastaya başlanan intravenöz meropenem ve kolistin tedavisinin 7. gününde klinik iyileşme olmaması üzerine tedavisine inhale kolistin eklendi. Bu tedavinin 15 gün uygulanmasını takiben pnömoni ve sepsis geriledi, hasta taburcu edildi. Uzamış nötrojeni ve mekanik ventilasyon kullanımı, bağışıklık sistemi baskılanmış hastalarda genellikle enfeksiyonlara sebep olan hastane kaynaklı patojen *Pseudomonas* spp'ye bağlı alt solunum yolu enfeksiyonlarının gelişme riskini artırır. İntravenöz uygulamaya ilaveten inhale olarak verilen kolistin, kolistin dışındaki ilaçların çoğuna dirençli olan bu patojenlerin sebep olduğu tedavisi güç enfeksiyonların başarı ile sağaltımında güncel seçenek olabilir.

Anahtar Kelimeler: Psödomonas; nötrojeni; immün yetmez konak; pnömoni, bakteriyel; kolistin

Türkiye Klinikleri J Case Rep 2015;23(3):269-74

doi: 10.5336/caserep.2013-38150

Copyright © 2015 by Türkiye Klinikleri

Patients with hematological malignancies, especially ones with neutropenia, are at high risk for hospital acquired infections, including pneumonias.¹⁻⁴ Since early 2000's, Gram negative bacteria seem to be

causing an increased number of infections with increased mortality in neutropenic patients.⁵⁻⁷ A current major problem is the increase in the proportion of patients diagnosed with hospital acquired infections due to multi-drug resistant (MDR) Gram negative bacteria, including mainly *Pseudomonas aeruginosa*, *Acinetobacter baumannii* and *Klebsiella pneumoniae*.⁸⁻¹¹ Colistin (also called polymyxin E), an historical bactericidal agent used since 1960's for treatment of Gram negative infections and abandoned in 1980s because of its nephrotoxicity and neurotoxicity, is one of the few drugs that are still effective against these pathogens.¹²⁻¹⁴ When administered by intravenous route, penetration is poor to lung tissue; therefore nebulisation of it has been suggested to achieve adequate bactericidal concentrations at the alveolar levels.¹⁵⁻¹⁹ There are few observational, retrospective, uncontrolled small case series, including patients with malignancies, about use of combination of inhaled and intravenous colistin for management of hospital acquired pneumonia (HAP) caused by MDR *Pseudomonas aeruginosa*.^{12,14,19,20} Herein, we present a case with lymphoma developed neutropenia and subsequently HAP caused by MDR *Pseudomonas aeruginosa*, and treated successfully with combined colistin therapy.

CASE REPORT

A fifty-nine year old man was diagnosed with Mantle cell lymphoma (MCL) blastoid variant in stage IV (Ann Arbor staging system) with bone marrow infiltration in 2008 and received a Rituximab plus CHOP (Cyclophosphamide, Hydroxydaunorubicin; Oncovin, Prednisone) (RCHOP) chemotherapy protocol for six courses. Since he relapsed within 1.5 years, a salvage chemotherapy regimen was given, followed by high dose chemotherapy (CT) with peripheral stem cell rescue. After sixth months of autologous transplantation, the patient with no fully matched sibling donor for allogeneic transplantation relapsed again. While the transplantation centre was looking for an unrelated and haploidentical donor, we administered one course of an R-Hyper CVAD (Cyclophosphamide, Vincristine, Adriamycin, and

Dexamethosone) regimen, followed by a high dose methotrexate and cytarabine regimen with fluconazole and valacyclovir prophylaxis. Although he received filgrastim at the end of CT, he developed severe neutropenia with fever, cough, hypotension, tachypnoea, hypoxaemia and bilateral rales in the lungs on 7th day of CT. Imipenem (4x500 mg/d) and vancomycin (2x1 g/d) were started empirically for febrile neutropenia, along with bronchodilator treatment. He was admitted to the intensive care unit (ICU) because of the deterioration in his clinical condition and required ventilatory support at the 14th day of the CT. One day after ICU admission, bone marrow regeneration occurred and the patient's neutrophil count increased. Blood cultures revealed *C. albicans*; so caspofungin was added-on the therapy (Day 15). After one-week-of-caspofungin therapy, the patient was afebrile with improved ventilation status and imipenem and vancomycin were stopped (Day 21). At 30th day of CT, he was extubated and transferred to the hematology ward on day 40. Five days later, the patient developed diarrhea and sub-febrile fever together with neutropenia and thrombocytopenia. Because of his prolonged hospitalization and history of chemotherapy (received 45 days ago), the patient was accepted as immunocompromised. With pre-diagnosis of cytomegalovirus (CMV) infection, gancyclovir and filgrastim were started at dose of 2x350 mg and 0,5 mIU/kg/day, respectively gancyclovir therapy was stopped at 10th day of management (since CMV-PCR was negative). Neutropenia continued for about 10 days. Patient complained of cough and shortness of breath and exhibited fever, tachypnoea and hypoxaemia, as well as rales in the lungs (Day 53 of CT). Chest X ray revealed infiltration areas in the upper lobe of the left lung, confirmed with computerized tomography as patchy form (Figure 1). Levofloxacin was started empirically at dose of 1x750 mg. Since sputum culture revealed MDR (resistant to all available antibiotics except for colistin) *P. aeruginosa*, levofloxacin was stopped and antimicrobial therapy consisting of intravenous colistin (3x100 mg/d) and meropenem (3x2 g/d) was started at 10th day of neutropenia (day 55 of CT). Caspo-

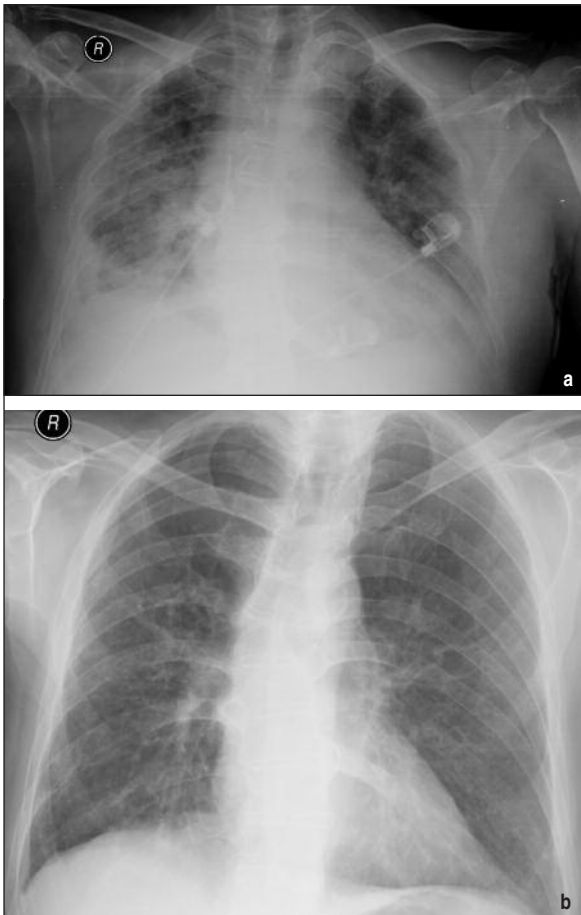


FIGURE 1: Chest X ray a) before and b) after the colistin therapy.

fungin was stopped (day 60 of CT). Despite treatment with intravenous colistin and meropenem for seven days, his condition failed to improve. Fiberoptic bronchoscopy was performed and bronchoalveolar lavage sample was obtained for quan-

titative culture. The same pathogen with the same susceptibility pattern was isolated at a concentration of 10^5 CFU/ml. Inhaled colistin (2x75 mg) was added-on the therapy (day 65 of CT). On the same day, patient's neutrophil count has started to increase and he was no longer neutropenic (Table 1). Within two weeks, his clinical status improved with regression of pneumonia and concomitant neutrophil and thrombocyte count increase, reaching nearly normal levels (Figure 1). Combination therapy was stopped at day 15 without any complications and he was discharged.

DISCUSSION

Cancer patients receiving cytotoxic antineoplastic therapy sufficient to adversely affect myelopoiesis are at risk for hospital acquired infection; including HAP, urinary tract infections and bacteremia.⁴ Patients with profound prolonged neutropenia are at particularly high risk for serious pulmonary infections, as shown by Carlisle et al. as 5.5 per 100 neutropenic patients with cancer.¹ The spectrum of potential pathogens known to cause pulmonary infections in immunocompromised individuals has grown as a result of intensified immunosuppression, prolonged patient survival, the emergence of antimicrobial-resistant pathogens, and improved diagnostic assays.

Pseudomonas aeruginosa, a nosocomial pathogen generally causing infections in ICU's or immunocompromised patients, can lead to develop-

TABLE 1: Laboratory findings of the patient.

	1 st day of CT	7 th day of CT	15 th day of CT	40 th day of CT	45 th day of CT	55 th day of CT	65 th day of CT	80 th day of CT
Hemoglobin, g/dL	11,1	8,92	7,52	9,5	9,05	7,87	8,77	12,5
White Blood Cell, / μ L	6150	1680	6130	9550	2380	1000	3620	5750
Neutrophil, / μ L	4970	630	5500	6650	2380	610	2340	2000
Platelet, / μ L	136000	32000	31800	146000	74500	14800	21600	77500
LiverFunctionTests	N	N	N	N	N	N	N	N
RenalFunctionTests	N	N	N	N	N	N	N	N
CRP, mg/dL	2,8	71,67	284	111,56	282	280	116	8,14

CT: Chemotherapy.

ment of HAP especially in patients with prolonged neutropenia and mechanical ventilation.²¹ At year 2014, the major challenge is the growing resistance in Gram-positive and Gram-negative pathogens (known as 'ESKAPE', including *P. aeruginosa*) causing infections in hospitals and community.¹³ D'A-gata et al. suggested that prevalence of MDR *P. aeruginosa* has increased from 1% to 16% over a 9 year period.¹⁰ A multicentre surveillance study from Turkey reported that resistance rates of *Pseudomonas aeruginosa* were 18% for piperacillin/tazobactam, 30% for imipenem, and 23% for amikacin.¹¹

Colistin, a polymyxin antibiotic, has been available for management of Gram-negative bacteria infections since 1959; however it was removed from use in the past because of its serious side effects, like nephrotoxicity.²² With the emergence of MDR Gram-negative bacteria, it has been reconsidered as salvage therapy.^{12,14-16} Since colistin is a cationic detergent damaging bacterial cytoplasmic membrane, it is more active in infections due to MDR bacteria.²³ But its polycationic/hydrophilic structure limits its penetration to lung tissue; therefore aerosolized form has been evaluated for generating high drug concentrations at site of infection without increasing the risks of systemic toxicity and resistance against colistin.¹⁵⁻¹⁹ Aerosolized colistin has been found to be successful in the treatment of MDR *Pseudomonas* related pneumonia in cystic fibrosis patients.²⁴ Clinical data for patients without cystic fibrosis are derived from uncontrolled small case series, as well as retrospective and non-randomized studies.^{12,14,17-21} Kwa et al. successfully used inhaled colistin therapy in patients with MDR *Pseudomonas* and *Acinetobacter*-related pneumonia, resulting in success rates of 57.1% and 87.5%, respectively.²⁵ In one of the largest studies (including 165 patients) Lu et al. demonstrated that nebulized colistin was effective to treat HAP caused by MDR *P. Aeruginosa* and *A. baumannii* with low risk of resistance development.¹⁸ The authors also noted that it did not increase the risk of renal failure, although repeated nebulization was found to induce systemic accumulation. Recently, Tumbarello et al. also indicated that in 208 criti-

cally ill patients with HAP caused by MDR Gram negative organisms, aerosolized colistin as adjunct to intravenous form could significantly improve clinical cure rates and shorten the duration of mechanical ventilation, as compared with intravenous colistin monotherapy alone.¹² These studies were conflicting with earlier studies showing no significant differences with combination therapy; however they were criticized to have small number of patients leading to power limitations.^{12,19,26} Efficacy of colistin can be enhanced with the use of another antibiotic, such as rifampicin or carbapenems.²⁷⁻²⁹ Pintado et al. reported that colistin use is effective in MDR Gram negative bacteraemia, with a response rate of 71.7%, when used in combination with aminoglycosides.²⁹

Our patient with MCL relapsed after autologous stem cell transplantation. His prognosis was poor and he was being prepared for allogeneic transplantation. We applied the R-Hyper-CVAD chemotherapy protocol, with favourable results in relapsed and refractory patients (Wang et al.). Unfortunately our patient developed neutropenia twice, 7 and 45 days after CT. No explanation can be made as a cause of second neutropenia; however we can speculate that it was related to prolonged Caspofungin use for 45 days, since his blood count improved after discontinuation of it. Neutropenia caused by caspofungin was reported as frequent as 1.9% by product monograph.³⁰

Febrile neutropenia guidelines recommends intravenous colistin use in patients with MDR Gram-negative bacteraemia, but routine use of inhaled colistin is not advised probably due to limited data without randomized controlled trials.³¹ With known synergistic antibiotic activity, we started intravenous colistin and meropenem for hospital acquired pneumonia caused by MDR *P. aeruginosa*, despite presence of meropenem resistance. Since his clinical condition did not improve under this regimen, inhaled colistin was added-on as adjunct therapy leading to clinical cure and discharge within 2 weeks. However the patient was no more neutropenic by the start of nebulised therapy. Therefore this clinical improvement can be ei-

ther due to additional inhaled colistin use or to increased neutrophil count.

In conclusion, immunocompromised patients have high risk for pneumonia, which can be due to MDR Gram-negative bacteria. Only two new antibiotics have been approved by US Food and Drug

Administration for management of these pathogens in the last 5 years.³² Aerosolized colistin therapy concomitant with the intravenous form can be safely used for successful treatment of HAP caused by these pathogens in patients with hematological malignancies.

REFERENCES

- Carlisle PS, Guicalp R, Wiernik PH. Nosocomial infections in neutropenic cancer patients. *Infect Control Hosp Epidemiol* 1993;14(6):320-4.
- Dettenkofer M, Ebner W, Bertz H, Babikir R, Finke J, Frank U, et al. Surveillance of nosocomial infections in adult recipients of allogeneic and autologous bone marrow and peripheral blood stem-cell transplantation. *Bone Marrow Transplant* 2003;31(9):795-801.
- Engelhart S, Glasmacher A, Exner M, Kramer MH. Surveillance for nosocomial infections and fever of unknown origin among adult hematology-oncology patients. *Infect Control Hosp Epidemiol* 2002;23(5):244-8.
- Huoi C, Vanhems P, Nicolle MC, Michallet M, Bénet T. Incidence of hospital-acquired pneumonia, bacteraemia and urinary tract infections in patients with haematological malignancies, 2004-2010: a surveillance-based study. *PLoS One* 2013;8(3):e58121.
- Regazzoni CJ, Khoury M, Irrazabal C, Myburg C, Galvalisi NR, O'Flaherty M, et al. Neutropenia and the development of the systemic inflammatory response syndrome. *Intensive Care Med* 2003;29(1):135-8.
- Metallidis S, Kollaras P, Giannakakis T, Seitanidis B, Kordosis T, Nikolaidis J, et al. A prospective, controlled, randomized, non-blind, comparative study of the efficacy and safety of a once daily high dose of ceftriaxone plus ciprofloxacin versus thrice daily cef-tazidime plus amikacin in empirical therapy for febrile neutropenic patients. *Eur J Intern Med* 2008;19(8):619-24.
- Wisplinghoff H, Bischoff T, Tallent SM, Seifert H, Wenzel RP, Edmond MB. Nosocomial bloodstream infections in US hospitals: analysis of 24,179 cases from a prospective nationwide surveillance study. *Clin Infect Dis* 2004;39(3):309-17.
- Jones ME, Draghi DC, Thornsberry C, Karlowsky JA, Sahn DF, Wenzel RP. Emerging resistance among bacterial pathogens in the intensive care unit—a European and North American Surveillance study (2000-2002). *Ann Clin Microbiol Antimicrob* 2004 Jul 29;3:14. doi:10.1186/1476-0711-3-14
- Fraimow H, Nahra R. Resistant gram-negative infections. *Crit Care Clin* 2013;29(4):895-921.
- D'Agata EM. Rapidly rising prevalence of nosocomial multidrug-resistant, Gram-negative bacilli: a 9-year surveillance study. *Infect Control Hosp Epidemiol* 2004;25(10):842-6.
- Gur D, Hascelik G, Aydin N, Telli M, Gültekin M, Oğulç D, et al. Antimicrobial resistance in gram-negative hospital isolates: results of the Turkish HITIT-2 Surveillance Study of 2007. *J Chemother* 2009;21(4):383-9.
- Doshi NM, Cook CH, Mount KL, Stawicki SP, Frazee EN, Personett HA, et al. Adjunctive aerosolized colistin for multi-drug resistant gram-negative pneumonia in the critically ill: a retrospective study. *BMC Anesthesiol* 2013;13(1):45.
- Boucher HW, Talbot GH, Bradley JS, Edwards JE, Gilbert D, Rice LB, et al. Bad bugs, no drugs: no ESKAPE! An update from the Infectious Diseases Society of America. *Clin Infect Dis* 2009;48(1):1-12.
- Tumbarello M, De Pascale G, Trecarichi EM, De Martino S, Bello G, Maviglia R, et al. Effect of aerosolized colistin as adjunctive treatment on the outcomes of microbiologically documented ventilator-associated pneumonia caused by colistin-only susceptible gram-negative bacteria. *Chest* 2013;144(6):1768-75.
- Stein A, Raoult D. Colistin: an antimicrobial for the 21st century? *Clin Infect Dis* 2002;35(7):901-2.
- Florescu DF, Qiu F, McCartan MA, Mindru C, Fey PD, Kalil AC. What is the efficacy and safety of colistin for the treatment of ventilator-associated pneumonia? A systematic review and meta-regression. *Clin Infect Dis* 2012;54(5):670-80.
- Lu Q, Girardi C, Zhang M, Bouhemad B, Louchahi K, Petitjean O, et al. Nebulized and intravenous colistin in experimental pneumonia caused by *Pseudomonas aeruginosa*. *Intensive Care Med* 2010;36(7):1147-55.
- Lu Q, Luo R, Bodin L, Yang J, Zahr N, Aubry A, et al.; Nebulized Antibiotics Study Group. Efficacy of high-dose nebulized colistin in ventilator-associated pneumonia caused by multidrug-resistant *Pseudomonas aeruginosa* and *Acinetobacter baumannii*. *Anesthesiology* 2012;117(6):1335-47.
- Kofteridis DP, Alexopoulou C, Valachis A, Maraki S, Dimopoulou D, Georgopoulos D, et al. Aerosolized plus intravenous colistin versus intravenous colistin alone for the treatment of ventilator-associated pneumonia: a matched case-control study. *Clin Infect Dis* 2010;51(11):1238-44.
- Korbila IP, Michalopoulos A, Rafailidis PI, Nikita D, Samonis G, Falagas ME. Inhaled colistin as adjunctive therapy to intravenous colistin for the treatment of microbiologically documented ventilator-associated pneumonia: a comparative cohort study. *Clin Microbiol Infect* 2010;16(8):1230-6.
- Garau J, Gomez L. *Pseudomonas aeruginosa* pneumonia. *Curr Opin Infect Dis* 2003;16(2):135-43.
- Falagas ME, Kasiakou SK. Colistin: the revival of polymyxins for the management of multidrug-resistant gram-negative bacterial infections. *Clin Infect Dis* 2005;40(9):1333-41.
- Michalopoulos AS, Karatza DC. Multidrug-resistant Gram-negative infections: the use of colistin. *Expert Rev Anti Infect Ther* 2010;8(9):1009-17.
- Katz SL, Ho SL, Coates AL. Nebulizer choice for inhaled colistin treatment in cystic fibrosis. *Chest* 2001;119(1):250-5.
- Kwa AL, Loh C, Low JG, Kurup A, Tam VH. Nebulized colistin in the treatment of pneumonia due to multidrug-resistant *Acinetobacter baumannii* and *Pseudomonas aeruginosa*. *Clin Infect Dis* 2005;41(5):754-7.
- Michalopoulos AS, Kasiakou SK, Mastora Z, Rellos K, Kapaskelis AM, Falagas ME. Aerosolized colistin for the treatment of nosocomial pneumonia due to multidrug-resistant Gram-negative bacteria in patients without cystic fibrosis. *Crit Care* 2005;9(1):R53-9.

27. Pankuch GA, Lin G, Seifert H, Appelbaum PC. Activity of meropenem with and without ciprofloxacin and colistin against *Pseudomonas aeruginosa* and *Acinetobacter baumannii*. *Antimicrob Agents Chemother* 2008; 52(1):333-6.
28. Timurkaynak F, Can F, Azap OK, Demirbilek M, Arslan H, Karaman SO. In vitro activities of non-traditional antimicrobials alone or in combination against multidrug-resistant strains of *Pseudomonas aeruginosa* and *Acinetobacter baumannii* isolated from intensive care units. *Int J Antimicrob Agents* 2006;27(3):224-8.
29. Pintado V, San Miguel LG, Grill F, Mejía B, Cobo J, Fortún J, et al. Intravenous colistin sulphomethate sodium for therapy of infections due to multidrug-resistant gram-negative bacteria. *J Infect* 2008;56(3):185-90.
30. Product monograph 'Candidas.' Date of revision Feb 21, 2013. Kirkland: Merck Canada INC; 2013. p.1-51.
31. Freifeld AG, Bow EJ, Sepkowitz KA, Boeckh MJ, Ito JI, Mullen CA, et al. Clinical practice guideline for the use of antimicrobial agents in neutropenic patients with cancer: 2010 update by the infectious diseases society of america. *Clin Infect Dis* 2011;52(4):e56-93.
32. Boucher HW, Talbot GH, Benjamin DK Jr, Bradley J, Gidos RJ, Jones RN, et al.; Infectious Diseases Society of America. 10 x '20 Progress--development of new drugs active against gram-negative bacilli: an update from the Infectious Diseases Society of America. *Clin Infect Dis* 2013;56(12):1685-94.