

Effect of Sildenafil on the Skeletal Muscle Regeneration: An Experimental Study

Sildenafilin İskelet Kası Rejenerasyonu Üzerindeki Etkisi: Deneysel Çalışma

GüldeN DİNİZ, MD,^a
Hayrullah DERİCİ, MD,^b
Erdoğan KAMER, MD,^b
Haluk Recai ÜNALP, MD,^b
Ali Doğan BOZDAĞ, MD,^b
Tuğrul TANSUĞ, MD,^b
Ragıp ORTAÇ, MD,^a
Yeşim ERBİL, MD^c

^aDepartment of Pathology,
İzmir Dr. Behcet Uz Children's Hospital,

^bDepartment of General Surgery,
Atatürk Research Hospital, İzmir

^cDepartment of General Surgery,
İstanbul University
İstanbul Faculty of Medicine, İstanbul

Geliş Tarihi/Received: 24.02.2010
Kabul Tarihi/Accepted: 05.11.2010

Yazışma Adresi/Correspondence:

GüldeN DİNİZ, MD
İzmir Dr. Behcet Uz Children's Hospital,
Department of Pathology,
İzmir,
TÜRKİYE/TURKEY
agdiniz@gmail.com

ABSTRACT Objective: Sildenafil is a phosphodiesterase 5 (PDE5) inhibitor that induces vasodilatation and is currently used in treatment of erectile dysfunction and pulmonary hypertension. The aim of this study was to investigate the effects of sildenafil on the regenerative activity of skeletal muscle adjacent to the abdominal wall wound in rats. **Material and Methods:** This study was conducted in Aegean University Faculty of Medicine Animal Research Laboratory between July 2008 and August 2008, and was performed with adult female Wistar-Albino rats. A control group (n= 50) was fed on a standard laboratory diet until 12 h before surgery. The study group (n= 50) was administered sildenafil therapy (10 mg/kg once a day for 10 days) through an orogastric tube. Each rat was anesthetized, and a 4-cm-long midline laparotomy was performed. Ten animals from each group were killed at postoperative days (PODs) 4, 7, 14, 21, and 35. The abdominal incision wounds and surrounding tissues were examined histologically. **Results:** Regenerative capacity of the abdominal muscle in sildenafil treatment group was significantly higher than the control group and the difference was statistically significant ($P \leq 0.01$). **Conclusion:** This study showed that sildenafil augmented the regenerative activity of the skeletal muscle. If this result can be reproduced by other studies, sildenafil may be beneficial therapy for degenerative muscle diseases.

Key Words: Muscle, skeletal; regeneration

ÖZET Amaç: Sildenafil vazodilatasyonu indükleyen bir fosfodiesteraz 5 (PDE5) inhibitörüdür ve halihazır erektil disfonksiyon ve pulmoner hipertansiyon tedavisinde kullanılmaktadır. Bu çalışmanın amacı, sildenafilin sıçanlarda karın duvarı yarasına bitişik iskelet kasındaki rejeneratif aktivite üzerine etkilerini araştırmaktır. **Gereç ve Yöntemler:** Bu çalışma, Ege Üniversitesi Tıp Fakültesi Hayvan Çalışmaları Laboratuvarında Temmuz 2008-Ağustos 2008 arasında, yetişkin dişi Wistar-Albino sıçanlar ile yapılmıştır. Kontrol grubu (n= 50) ameliyattan 12 saat öncesine kadar standart laboratuvar diyeti ile beslendi. Çalışma grubuna (n= 50) orogastrik tüp yardımıyla 10 gün boyunca günde bir kez oral 10 mg/kg sildenafil tedavisi uygulandı. Her bir sıçana anestezi altında 4 cm uzunluğunda orta hat laparotomi yapıldı. Her gruptan on hayvan postoperatif 4, 7, 14, 21, ve 35. günlerde (POG) öldürüldü. Abdominal insizyon yaraları ve çevre dokular histolojik olarak incelendi. **Bulgular:** Sildenafil tedavi grubunda karın kasının rejeneratif kapasitesi kontrol grubuna göre önemli ölçüde daha yüksek bulundu ve fark istatistiksel olarak ($P \leq 0.01$) anlamlı idi. **Sonuç:** Bu çalışma sildenafilin iskelet kasının rejeneratif aktivitesini artırdığını göstermektedir. Bu sonucun diğer çalışmalar tarafından da tekrarlanabilmesi durumunda, sildenafil ayrıca dejeneratif kas hastalıklarının tedavisi için kullanılabilir.

Anahtar Kelimeler: Kas, iskelet; rejenerasyon

Türkiye Klinikleri J Med Sci 2011;31(4):809-15

doi:10.5336/medsci.2010-17822

Copyright © 2011 by Türkiye Klinikleri

Türkiye Klinikleri J Med Sci 2011;31(4)

The reconstitution of the skeletal muscle cells after necrosis is termed regeneration.¹ Skeletal muscle has remarkable regenerative capacity and new myotubes are formed in only a few days after acute dama-

ge.² Experimental studies have demonstrated that multinucleated myotubes are generated from single myogenic precursor cells that resemble embryonic myoblasts and these precursors are derived from muscle satellite cells.^{1,2} These stem cells lie between the external lamina and sarcolemma of skeletal muscle fibers that are named for their location.^{3,4} Regeneration is due to the activation of quiescent satellite cells, which proliferate and differentiate to form new myotubes.⁵ In this process, several growth factors which come from the muscle and/or from the motor nerve and inflammatory cells have been shown to play key roles. During myogenesis, proliferation of satellite cells is regulated by FGFs (fibroblast growth factors), HGF (hepatocytes growth factor), TGF- β (transforming growth factor beta), PDGF (platelet-derived growth factor), IGF-I and II (insulin-like growth factor), while differentiation appears to be promoted mainly by IGFs. In contrary, FGF-2 and HGF delay the differentiation of myogenic progenitors. Other factors also appear to condition the regeneration process, such as LIF (leukemia inhibitory factor), which acts predominantly as a stimulator for myoblast growth; and HARP (heparin affinity regulatory peptide)/PTN (pleiotrophin)/HB-GAM (heparin-binding growth-associated molecule) and other neurotrophic factors, which may be necessary for the formation of new neuromuscular junctions. TGF- β has a major influence on the reorganisation of the extracellular matrix.^{6,7} Biochemical pathways regulating muscle regeneration are initiated by these mediators and evolution is conversed by several signaling pathways such as Notch, Wnt, sonic hedgehog (Shh).² Experiments identified that nitric oxide (NO) has a regulatory function on myoblast fusion and myotube growth, so it promotes muscle regeneration. These functions of NO were elegantly demonstrated to occur via cyclic guanosine monophosphate (cGMP) and induction of follistatin expression.⁸

When stimulation occurs, the neurotransmitter NO is released across the neuromuscular junction and causes an increase of the cGMP. These molecules relax the arterial walls and increase blood flow. PDE-5 breaks down the cGMP resulting

in a contraction of smooth muscles. The result is decreased blood flow. Sildenafil citrate has structural similarity with cyclic guanosine monophosphate (cGMP). Therefore it binds to the active site of the type five class phosphodiesterase (PDE-5), preventing the breakdown of cGMP through competitive inhibition. There are 11 types of PDE found in the body; PDE-5 is primarily found in the corpus cavernosum, platelets, skeletal muscle and smooth muscles of viscera. Sildenafil enhances vasodilatation, increases tissue blood flow by relaxing the smooth muscle in the vessels, inhibits platelet aggregation and improves microcirculation. Because of these effects, it is usually used in the treatment of erectile dysfunction (ED).⁹⁻¹¹

Muscular dystrophies are degenerative genetic disorders of muscle where there is marked muscle weakness and fragility. They are caused by mutations in genes encoding proteins of the dystrophin-associated glycoprotein complex at the sarcolemma and these mutations lead to its partial or complete absence. These structural proteins render the support network that connects myofilament proteins within the cell to the basal lamina outside the cell. The most common form of the disease, affecting 1 out 3500 newborn males, is Duchenne muscular dystrophy (DMD) in which dystrophin is absent. Without the dystrophin complex to tether the actin cytoskeleton inside the muscle cell to the extracellular matrix, forces generated by the muscle fiber result in tears of the sarcolemma and lead to muscle damage. The regenerative capacity in muscle cannot compensate for increased susceptibility for structural damage. A secondary consequence in dystrophic muscle is the inability of the muscle to adequately repair itself. The imbalance between muscle damage and muscle repair leads to a loss of muscle fibers and an increase in the amount of fibrosis over time until the functional capacity of the muscle diminishes to a point below the required force output.^{12,13}

In this study, we primarily aimed to evaluate the possible positive effects of sildenafil on wound healing.¹⁴ During the histopathological examinations, we determined increased regenerative activity on the striated muscle of rats receiving sildenafil

citrate. This result raises the question of whether treating with sildenafil might be beneficial in some muscle diseases characterized with decreased regenerative capacity.

MATERIAL AND METHODS

The study was performed with adult female 5-month-old Wistar-Albino rats ($n=100$) weighing between 250 and 300 g, in Aegean University Faculty of Medicine Animal Research Laboratory between July 2008 and August 2008.¹⁴ All animals were housed in cages under standard conditions (room temperature of 22-24°C and within a 12-h light/dark cycle). All experimental manipulations and postoperative care were undertaken in accordance with the National Institutes of Health Guide for the Care and Use of Laboratory Animals. The study was approved by the Animal Ethics Committee of the Aegean University Medical School. The rats were randomized into two groups of 50 each. The control group (CG, $n=50$) was fed on standard laboratory diet and water ad libitum and had free access to water and standard rat chow until 12 h before surgery. The study group (SG, $n=50$) was administered sildenafil (Viagra® Pfizer, İstanbul, Turkey; 10 mg/kg once a day for 10 days) via an orogastric tube, until 12 h before surgery. Sildenafil (dissolved in distilled water with a minimum amount of HCl and adjusted to a final pH of approximately 4 with NaOH at doses of 10 mg/kg body weight/day) was given to rats orally using the method described by Shin et al.¹⁵

Each rat was anesthetized with an intramuscular injection of 60 mg/kg of ketamine hydrochloride (Ketalar, Eczacıbaşı, Warner-Lambert Laboratories, Levent, İstanbul, Turkey) and 10 mg/kg of xylazine hydrochloride (Rompun, Bayer Laboratories, Sisli, İstanbul, Turkey). All procedures were performed under clean but nonsterile conditions. After the abdominal skin was treated with a povidone-iodine scrub and shaved, a 4-cm-long midline laparotomy was performed. Immediately after that, the abdominal fascia and skin were closed in a continuous fashion with running 3/0 silk sutures. All rats were given water and regular diet ad libitum on the day of operation.

Ten animals in each group were killed on postoperative days (PODs) 4, 7, 14, 21, and 35 with an overdose of sodium pentobarbital (300 mg/kg, intraperitoneal). The skin sutures were removed, and the entire incision line, including surrounding intact skin and fascia, was excised with 1 cm margins. The abdominal incision wounds were excised and fixed into a 10% formaldehyde solution and stored for pathologic examinations. Biopsy specimens from wound areas were obtained as described above on POD 4, 7, 14, 21, and 35. The samples were immediately fixed in formalin, embedded in paraffin, sectioned, and stained with hematoxylin and eosin (H&E) and Gomori's trichrome. All representative sections in each rat were examined microscopically by two pathologists in blinded fashion.

All slides were examined for eight parameters, including the presence of acute and chronic inflammatory infiltrates, the maturation of granulation tissue, the amount of collagen deposition, the degree of reepithelialization, proliferations of vessels and regenerative activity of skeletal muscle cells in wound areas. We used the Abramov's histological scoring system¹⁶ for the evaluation of first seven parameters in this study. This system assessed each parameter independently and gave it a score of 0-3. Acute and chronic inflammatory infiltrates, the amount of granulation tissue, and collagen deposition were graded as 0 (none), 1 (scant), 2 (moderate), and 3 (abundant). The maturation of granulation tissue was graded as 0 (immature), 1 (mild maturation), 2 (moderate maturation), and 3 (fully matured). Acute inflammation was defined as the presence of polymorphonuclear leukocytes, while chronic inflammation was defined as the presence of plasmacytes and monocytic cells. Reepithelialization was graded as 0 (none), 1 (partial), 2 (complete but immature or thin), and 3 (complete and mature). Neovascularization was graded as 0 (none), 1 [up to five vessels per high-power field (HPF)], 2 (six to ten vessels per HPF), and 3 (more than ten vessels per HPF).¹⁶

Hitherto there was no scoring system for regenerative activity of the skeletal muscle. So we propose a new scoring system. In this system, amount and maturation of regenerative fibers and se-

verity of accompanied inflammation are assessed and given a score of 0-3. The score is quantified according to the amounts or the presence of regenerated fiber and inflammation within each sample. For example, a few regenerated fibers and mild inflammation are almost always present in muscle cells adjacent to the wound. We define this status as “score 0”. Scarce regenerated fibers with prominent inflammatory cell infiltration similar the inflammatory myopathies are regarded as “score 1”. Huge clustered regenerated fibers without prominent inflammatory cell infiltration similar to muscular dystrophies are regarded as “score 2”. If the regenerated fibers present themselves as a few cells without inflammation and almost all muscle cells were matured, they are considered as mature muscle “score 3” (Figure 1). It is easy to determine if a fiber is still regenerating or if it has reached of complete maturity. The cytoplasm of regenerating fibers is blue, reflecting their high content of ribo-

somes. The nuclei of these cells tend to be large and pale, with abundant heterochromatin and they tend to remain toward the center of the cell until the mature phenotype is almost fully present.

In each PODs, Mann-Whitney U test was used to compare the two study groups on scores and the relationship between the two relevant variables were evaluated by using Spearman’s correlation analysis. Data were analyzed by statistical software SPSS 9.05 for Windows. P values less than 0.05 were considered to be statistically significant.

RESULTS

All 100 rats survived the surgical procedures with no complications during the study. Acute inflammation score on POD 14 of the study group was significantly higher than that of the control group ($P= 0.02$). There were no statistically significant differences between the two groups in terms of

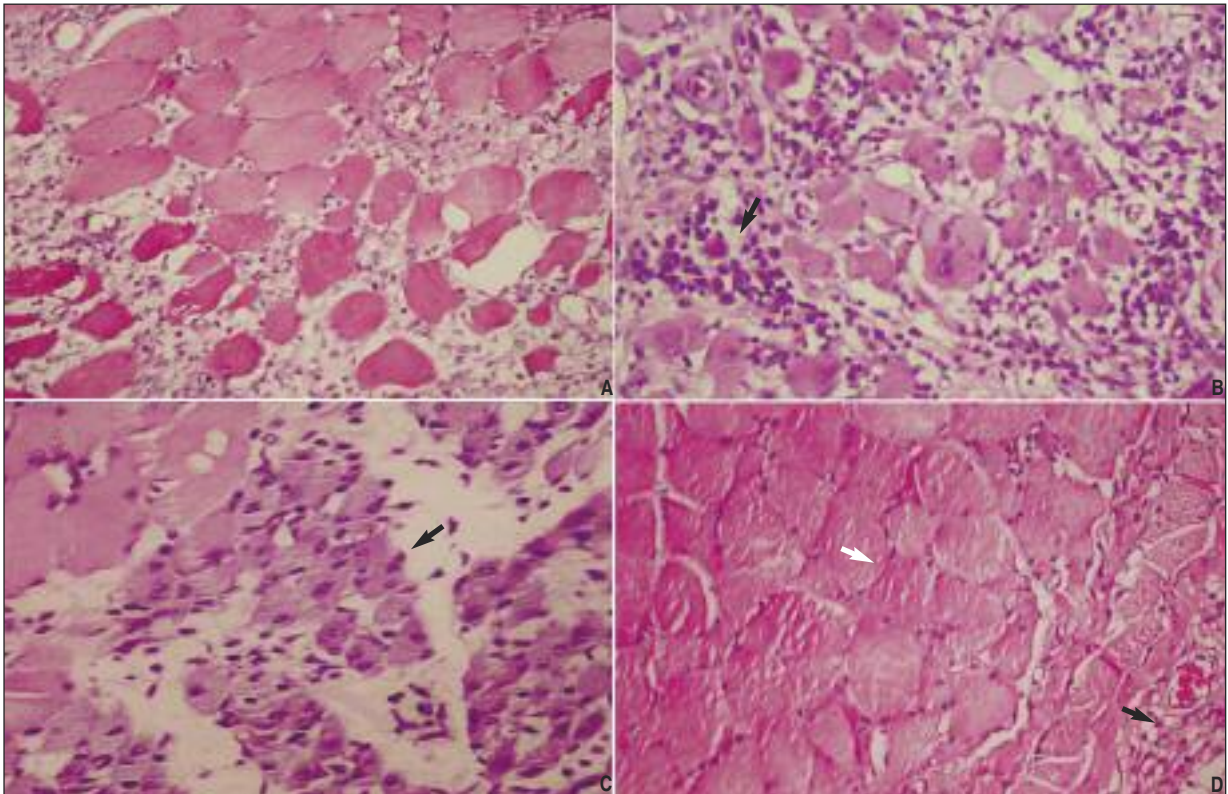


FIGURE 1: Histological features of skeletal muscle tissues according to the new scoring system for regenerative activity: **(A)** score 0; regenerative activity nearly absent, mild acute inflammatory infiltration and dense edema were noticed among the myofibers, **(B)** score 1: both regenerative activity and inflammatory infiltration (arrow) were increased similar to the inflammatory myopathies, **(C)** score 2: regenerative myofibers were more prominent (arrow) than inflammatory infiltration similar to the muscular dystrophies, **(D)** score 3: normal skeletal muscle tissue (white arrow) adjacent the healing wound (black arrow), (HE x 100).

chronic inflammation, amount of granulation tissue, fibroblast maturation and collagen deposition. Reepithelialization score did not differ significantly between the two groups. Neovascularization peaked on POD 14 in both groups; it differed significantly between the two groups on PODs 7, 14, 21, and 35 ($P=0.003$, $P=0.008$, $P=0.002$, and $P=0.007$, respectively).

In both groups, the mean values of regenerative activity of the skeletal muscle in abdominal wounds on POD 4, 7, 14, 21, and 35 of the experiment and the statistical comparisons of the groups are shown in Table 1. Regenerative capacity of the abdominal muscle in the sildenafil treatment group was superior than the control group (Figure 2) and the difference was statistically significant ($P=0.007$). However, there was no statistical significance between the wound healing scores and regenerative activity. In the Spearman analysis, regenerative activity was correlated with sildenafil therapy ($p=0.004$, $r=-0.560$), but not correlated with acute inflammation ($p=0.132$, $r=-0.317$), chronic inflammation ($p=0.999$, $r=0.000$), amount of granulation tissues ($p=0.792$, $r=0.57$), fibroblastic maturation ($p=0.415$, $r=0.175$), deposition of collagen ($p=0.474$, $r=0.154$), reepithelialization ($p=0.477$, $r=0.153$) and neovascularization scores ($p=0.729$, $r=-0.075$).

TABLE 1: Comparison of regenerative activity of adjacent skeletal muscle in wound field between the two study groups according to PODs.

PODs	Groups	Mean \pm SD	P ^a value
4	SG	1.75 \pm 0.50	0.056
	CG	0.67 \pm 0.58	
7	SG	1.75 \pm 0.96	0.119
	CG	0.67 \pm 0.58	
14	SG	2.00 \pm 0.82	0.252
	CG	1.00 \pm 0.00	
21	SG	1.75 \pm 0.96	0.119
	CG	0.67 \pm 0.58	
35	SG	2.50 \pm 0.58	0.029
	CG	0.33 \pm 0.18	

POD: postoperative day, CG: control groups, SG: study groups, ^aMann Whitney U test.

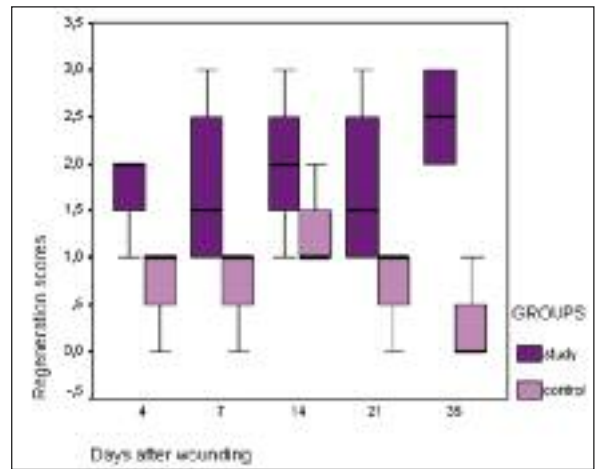


FIGURE 2: Changes of the regeneration scores of the skeletal muscles in the wound according to the PODs.

$p=0.007$, Mann Whitney U.

DISCUSSION

Division capacity of satellite cells is limited and it was estimated at about 60 total divisions.^{1,17} This capacity is consumed with age, possibly because necrosis and regeneration occur at a low level in normal life, in particular as a result of lengthening contractions.¹ In patients with severe muscular dystrophies, even at 2 years of age, the number of potential divisions of satellite cells is markedly decreased, presumably because there has been recurrent necrosis and regeneration since birth.^{1,17} Telomere length proves to be an excellent indicator of the number of divisions that a group of cells has undergone. A number of studies have shown that telomere length in human dystrophic muscle is significantly reduced compared to samples from healthy muscle.⁶ The function of dystrophin in muscle is still a mystery. However it has been suggested that it supports sarcolemma against mechanical stress, prevents free oxygen radicals from damaging muscle, acts in signal transductions, takes part in the regulation of intracellular calcium, and influences neurotransmitter receptors. All these mechanisms significantly interact with each other.¹⁸ No effective treatment of muscular dystrophies is known yet. Recent studies have focused on the promotion of skeletal muscle regeneration in these patients. It is expected that an increase of the regenerative capacity may provide an ameliorating effects for dystrophic symptoms.^{9,18-20}

DMD involves a complex pathophysiology that is not easily explained by the loss of dystrophin. Instead, many features of the pathology are attributable to the secondary loss of neuronal nitric oxide synthase (nNOS) from dystrophin-deficient muscle.⁹ Individual muscle fibers express one or both of the constitutive NO synthase (NOS) isoforms. Type I (neuronal) NOS is localized to the sarcolemma of fast fibers; type III (endothelial) NOS is associated with mitochondria. Isolated skeletal muscle produces NO at low rates under resting conditions and at higher rates during repetitive contraction. NO appears to mediate cell-cell interactions in muscle, including vasodilation and inhibition of leucocyte adhesion. NO also acts directly on muscle fibres to alter cell function and effects on muscle metabolism during the glucose uptake, glycolysis, mitochondrial oxygen consumption and creatine kinase activity. NO also modulates muscle contraction, inhibiting force output by altering excitation-contraction coupling. The mechanisms of NO action are likely to include direct effects on redox-sensitive regulatory proteins, interaction with endogenous reactive oxygen species and activation of second messengers such as cGMP.⁹ The localization of neuronal NOS (nNOS) at the plasma membrane of muscle has recently been shown to prevent muscle fatigue after exercise. It has been shown that dystrophin anchors nNOS to the sarcolemma through a direct interaction with dystrophin spectrin-like repeats 16 and 17.^{19,20}

It was demonstrated that the specific activity of phosphofructokinase (PFK; the rate limiting enzyme in glycolysis) is positively affected by nNOS in muscle; PFK-specific activity is significantly reduced in mdx muscles and the muscles of nNOS null mutants, but significantly increased in nNOS transgenic muscles and muscles from mdx mice that express the nNOS transgene.¹¹ In another recently reported study of mouse models of muscular dystrophy, PFK-5A inhibitors were used to treat the downstream ischemia that is associated with nNOS mislocalization. These findings indicate that

defects in glycolytic metabolism and increased fatigability in dystrophic muscle may be caused in part by the loss of positive allosteric interactions between nNOS and PFK.²¹

Previous studies have shown that sildenafil activates PKG-1 (cGMP-dependent protein kinase-1) resulting in anti-hypertrophic and anti-fibrotic effects on pressure-induced cardiac hypertrophy.²¹ Recently, another PDE5 inhibitor, tadalafil, has been reported to be effective in treatment of the some dystrophic symptoms in the mdx mouse.²² In this study, after 10-day sildenafil treatment, we saw an increase of the regenerative activity on the striated muscle adjacent to wound of rats. These data provides preliminary evidence that sildenafil treatment can induce the repair of skeletal muscle. Sildenafil has also a positive influence on wound healing at multiple levels, including angiogenesis, inflammation, endothelial and epithelial cell proliferation, matrix deposition, and remodeling.¹⁴ Sildenafil could enhance muscle regenerative capacity to offset the imbalance between muscle damage and repair. It could also promote protein synthetic pathways and inhibit muscle-wasting pathways by increasing of blood flow. The combined effect of enhanced repair and decreased wasting might lead to greater functional capacity over time, where there is a reduction in the proportion of maximal effort needed to produce a required force, so the muscle is less likely to be damaged by normal activity. In conclusion, it is apparent that the more work is required for the successful treatment of DMD, and that no general cure will be available any time soon. Therefore until a more effective therapy is developed, sildenafil may be used for patients with muscular dystrophies, especially DMD. Further studies are also required to investigate the possible mechanisms of sildenafil on regenerative activity. Finally, whether sildenafil can provide therapeutic benefit to the subset of patients with DMD and whether it can induce the regeneration of skeletal muscle must be examined in larger number of patients.

REFERENCES

- Carpenter S, Karpati G. Regeneration. Pathology of Skeletal Muscle. 2nd ed. New York: Oxford University Press; 2001. p.83-99.
- Wagers AJ, Conboy IM. Cellular and molecular signatures of muscle regeneration: current concepts and controversies in adult myogenesis. *Cell* 2005;122(5):659-67.
- Wozniak AC, Kong J, Bock E, Pilipowicz O, Anderson JE. Signaling satellite-cell activation in skeletal muscle: markers, models, stretch, and potential alternate pathways. *Muscle Nerve* 2005;31(3):283-300.
- Anderson JE. The satellite cell as a companion in skeletal muscle plasticity: currency, conveyance, clue, connector and colander. *J Exp Biol* 2006;209(Pt 12):2276-92.
- Husmann I, Soulet L, Gautron J, Martelly I, Barritault D. Growth factors in skeletal muscle regeneration. *Cytokine Growth Factor Rev* 1996;7(3):249-58.
- Barton ER, Morris L, Musaro A, Rosenthal N, Sweeney HL. Muscle-specific expression of insulin-like growth factor I counters muscle decline in mdx mice. *J Cell Biol* 2002;157(1):137-48.
- Wozniak AC, Anderson JE. Nitric oxide-dependence of satellite stem cell activation and quiescence on normal skeletal muscle fibers. *Dev Dyn* 2007;236(1):240-50.
- Pisconti A, Brunelli S, Di Padova M, De Palma C, Deponi D, Baesso S, et al. Follistatin induction by nitric oxide through cyclic GMP: a tightly regulated signaling pathway that controls myoblast fusion. *J Cell Biol* 2006;172(2):233-44.
- Wehling-Henricks M, Oltmann M, Rinaldi C, Myung KH, Tidball JG. Loss of positive allosteric interactions between neuronal nitric oxide synthase and phosphofructokinase contributes to defects in glycolysis and increased fatigability in muscular dystrophy. *Hum Mol Genet* 2009;18(18):3439-51.
- McCullough AR. Four-year review of sildenafil citrate. *Rev Urol* 2002;4(Suppl 3):S26-38.
- Huang LJ, Yoon MH, Choi JI, Kim WM, Lee HG, Kim YO. Effect of sildenafil on neuropathic pain and hemodynamics in rats. *Yonsei Med J* 2010;51(1):82-7.
- Kobinger GP, Louboutin JP, Barton ER, Sweeney HL, Wilson JM. Correction of the dystrophic phenotype by in vivo targeting of muscle progenitor cells. *Hum Gene Ther* 2003;14(15):1441-9.
- Fanin M, Tasca E, Nascimbeni AC, Angelini C. Sarcolemmal neuronal nitric oxide synthase defect in limb-girdle muscular dystrophy: an adverse modulating factor in the disease course? *J Neuropathol Exp Neurol* 2009;68(4):383-90.
- Derici H, Kamer E, Unalp HR, Diniz G, Bozdog AD, Tansug T, et al. Effect of sildenafil on wound healing: an experimental study. *Langenbecks Arch Surg* 2010;395(6):713-8.
- Shin HS, Bae SK, Lee MG. Pharmacokinetics of sildenafil after intravenous and oral administration in rats: hepatic and intestinal first-pass effects. *Int J Pharm* 2006;320(1-2):64-70.
- Abramov Y, Golden B, Sullivan M, Botros SM, Miller JJ, Alshahrour A, et al. Histologic characterization of vaginal vs. abdominal surgical wound healing in a rabbit model. *Wound Repair Regen* 2007;15(1):80-6.
- Webster C, Blau HM. Accelerated age-related decline in replicative life-span of Duchenne muscular dystrophy myoblasts: implications for cell and gene therapy. *Somat Cell Mol Genet* 1990;16(6):557-65.
- Niebrój-Dobosz I, Hausmanowa-Petrusewicz I. The involvement of oxidative stress in determining the severity and progress of pathological processes in dystrophin-deficient muscles. *Acta Biochim Pol* 2005;52(2):449-52.
- Lai Y, Thomas GD, Yue Y, Yang HT, Li D, Long C, et al. Dystrophins carrying spectrin-like repeats 16 and 17 anchor nNOS to the sarcolemma and enhance exercise performance in a mouse model of muscular dystrophy. *J Clin Invest* 2009;119(3):624-35.
- Reid MB. Role of nitric oxide in skeletal muscle: synthesis, distribution and functional importance. *Acta Physiol Scand* 1998; 162(3):401-9.
- Takimoto E, Champion HC, Belardi D, Moslehi J, Mongillo M, Mergia E, et al. cGMP catabolism by phosphodiesterase 5A regulates cardiac adrenergic stimulation by NOS3-dependent mechanism. *Circ Res* 2005; 96(1):100-9.
- Asai A, Sahani N, Kaneki M, Ouchi Y, Martyn JA, Yasuhara SE. Primary role of functional ischemia, quantitative evidence for the two-hit mechanism, and phosphodiesterase-5 inhibitor therapy in mouse muscular dystrophy. *PLoS One* 2007;2(8):e806.