

Harvesting of the Radial Artery with Carbon Dioxide Gas Insufflation for Coronary Artery Bypass Grafting: Invited Commentary

Koroner Arter Bypass Greftleme İçin Radyal Arterin Çıkarılmasında Karbondioksit Kullanılması

Gökhan ÖZERDEM, MD^a
Ahmet AKGÜL, MD^b

^aCardiovascular Surgery Clinic,
Çağ Hospital, Ankara
^bCardiovascular Surgery Clinic,
Bakırköy Dr. Sadi Konuk Training and
Research Hospital, İstanbul

Yazışma Adresi/Correspondence:
Gökhan ÖZERDEM, MD
Çağ Hospital,
Cardiovascular Surgery Clinic, Ankara,
TÜRKİYE/TURKEY
ozerdemkvc@yahoo.com

Key Words:
Radial artery, CO₂ insufflation

Anahtar Kelimeler:
Radyal arter, CO₂ insüflasyon

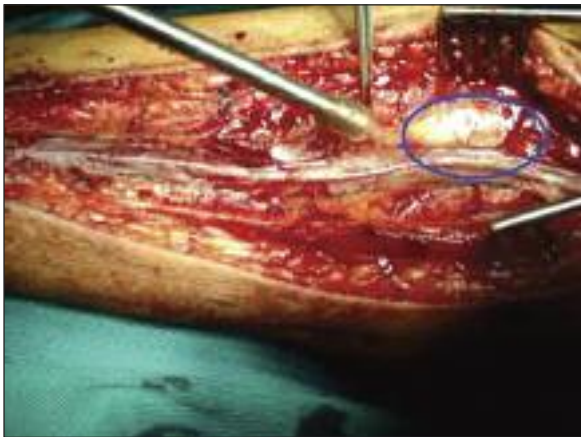
Using the radial artery (RA) as an arterial conduit was first proposed by Carpentier and colleagues in 1973¹ but thereafter, some surveys showed high occlusion rates.^{2,3} Because of vasospasm in RA, which induced vessel occlusion in as much as 35% of patients, this procedure was abandoned quickly.²

Perioperative spasm of RA is a common experience in coronary artery bypass grafting (CABG) surgery and it can lead to severe perioperative morbidity and even death in high-risk patients.³ The vasospasm was thought to be a consequence of the trauma during the harvesting procedure and thermal injury due to electrocautery.⁴ In order to decrease potential complications, we decided to utilize a less-invasive and less traumatic carbon dioxide gas insufflation technique for radial artery harvesting.

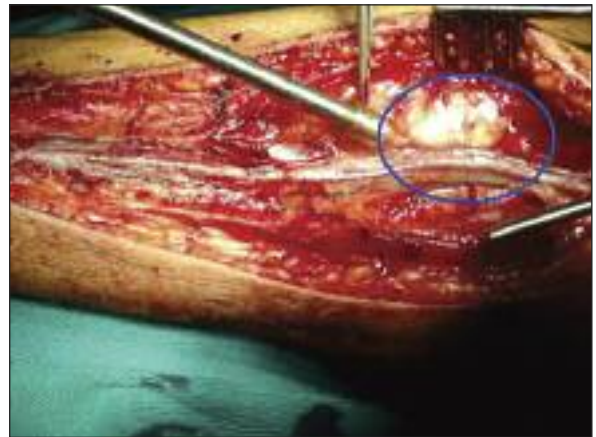
TECHNIQUE

Preoperative status of the circulation of the hand was assessed by the modified Allen's test. Allen's test was performed as follows: The patient was asked to keep his hand elevated as a fist for about 30 seconds and pressure was applied over both ulnar and radial arteries in order to occlude the blood flow totally. Then, still elevated, the fist was opened and ulnar pressure was released. Normally, the color of hand should return in 10 seconds. Preferentially non-dominant arms were selected for radial access.

A full-length forearm incision along the course of the RA was performed as described by Reyes et al.⁵ During the preparation of the RA, CO₂ was insufflated into the deep fascia (Figures 1a-1b, 2a-2b). After RA was exposed, a 15-mm blunt-tipped probe was inserted into the deep arterial fascia and adipose tissue around RA, to create a seal for CO₂ insufflation through a side port in the trocar. We used a low flow for CO₂ insufflation at 4 L/min at a pressure of 12 mmHg. Exposure was enhanced using CO₂ insufflation in an open system. Eventually, this led enabled and easy scissor dissection of the RA without any need for electrocautery (Figure 3).

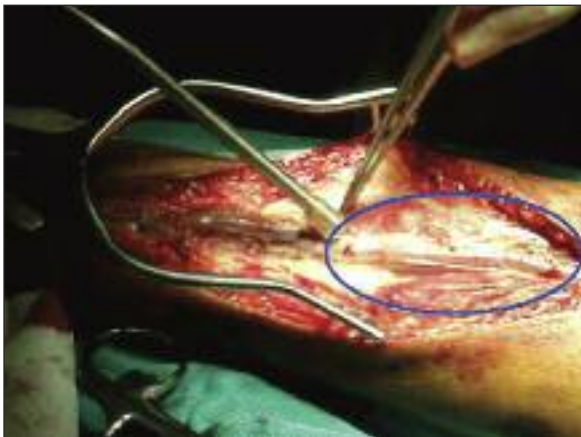

a

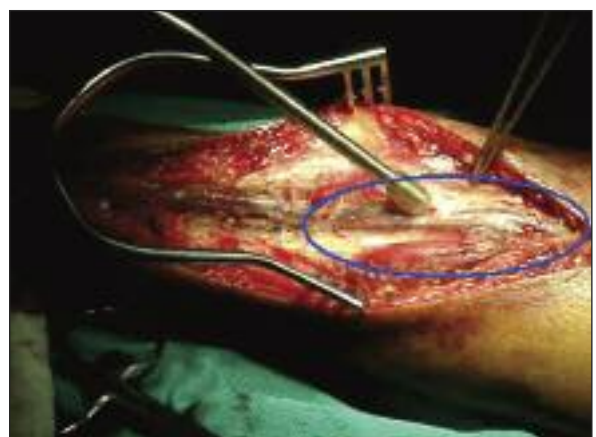


b

FIGURE 1a: Before and after CO₂ insufflation and creating a seal around radial artery.



a



b

FIGURE 2a: The dissection of the surrounding tissues from radial artery by CO₂ insufflation and the distribution of the CO₂ in the soft tissue.

All the branches were clipped and cut along the RA. With its proximal end still connected, the harvested RA remained in situ, covered with gauze soaked in warm isotonic saline solution with papaverine and diltiazem, until the final coronary artery anastomosis was accomplished. The RA grafts were warmed by wrapping with a soaked gauze. Following the completion of wound repair, the forearm was wrapped with an elastic bandage. The circulation of the left hand was continuously monitored by pulse oximetry. The elastic bandage was removed on the third postoperative day.

COMMENT

The revival of the RA for CABG was pioneered by Acar and colleagues, who reported good patency

rates of RA conduits.⁶ Then, the radial artery turned out to be a very popular conduit during CABG due to favorable data regarding its continuing high patency rates. Calafiore et al. identified nearly perfect patency after three years when the radial artery was used to revascularize the lateral wall.⁷ The radial artery graft is more prone to vasospasm than the other arterial grafts, possibly due to its abundant muscle cells. The main reason for spasm in arterial conduits is generally thermal and mechanical trauma. During harvesting procedures, thermal injury is generally caused by electrocautery and mechanical trauma inflicted by the selected harvesting technique. Topical or intraluminal administration of vasodilator agents was commonly preferred to eliminate arterial spasm and to increase the RA di-

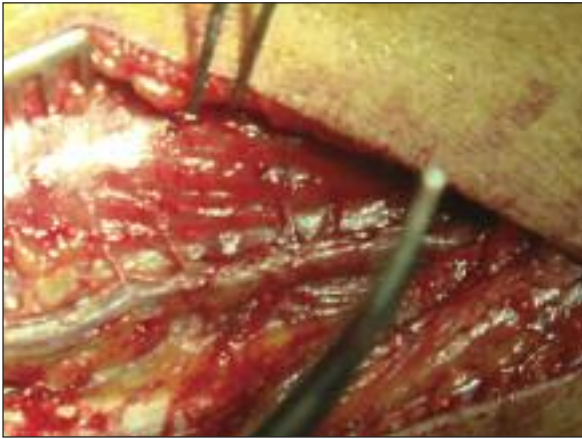


FIGURE 3: Venous and arterial branches seen clearly and procedure allows dividing branches with minimal damage.

ameter and flow. Despite this disadvantage, the use of the RA has been widely accepted by many surgeons because of its beneficial characteristics such as sufficient length, ease of concurrent harvesting during other grafting procedures, thick wall, and lumen wide enough to suit many grafting applications.^{8,9}

The insufflation of CO₂ in perivascular area of the RA facilitates easy and minimally traumatic ar-

terial harvesting by gas dissection. CO₂ insufflation at 4 L/min with a pressure between 10 and 12 mmHg is almost always sufficient to prevent development of subfascial emphysema with excellent visibility. Dilation of the RA and its branches due to CO₂ also improves the visualization of the branches, which could decrease the number of hemoclips for side branches. This might also help expedite the harvesting of the RA with minimal mechanical trauma and consequent vasospasm. The CO₂ insufflation also provided better control of bleeding, which was accomplished without use of potentially traumatic thermal injury associated with the use of electrocautery. CO₂ insufflation shows a significant vasodilator effect on RA flow. Ozkan et al. showed that carbon dioxide insufflation prevented the vasospasm of the internal mammary artery segments.¹⁰ In our patients, harvesting time was significantly less compared to the conventional technique, and we did not observe hypercapnia.

We believe this harvesting technique with carbon dioxide gas insufflation of the radial artery is minimally traumatic, simple and easier than the conventional technique.

REFERENCES

1. Carpentier A, Guermontez JL, Deloche A, Frechette C, DuBost C. The aorta-to-coronary radial artery bypass graft. A technique avoiding pathological changes in grafts. *Ann Thorac Surg* 1973;16(2):111-21.
2. Curtis JJ, Stoney WS, Alford WC Jr, Burrus GR, Thomas CS Jr. Intimal hyperplasia. A cause of radial artery aortocoronary bypass graft failure. *Ann Thorac Surg* 1975;20(6):628-35.
3. Fisk RL, Brooks CH, Callaghan JC, Dvorkin J. Experience with the radial artery graft for coronary artery bypass. *Ann Thorac Surg* 1976; 21(6):513-8.
4. Sarabu MR, McClung JA, Fass A, Reed GE. Early postoperative spasm in left internal mammary artery bypass grafts. *Ann Thorac Surg* 1987;44(2):199-200.
5. Reyes AT, Frame R, Brodman RF. Technique for harvesting the radial artery as a coronary artery bypass graft. *Ann Thorac Surg* 1995;59(1):118-26.
6. Acar C, Jebara VA, Portoghese M, Beyssen B, Pagny JY, Grare P, et al. Revival of the radial artery for coronary artery bypass grafting. *Ann Thorac Surg* 1992;54(4):652-9.
7. Calafiore AM, Di Mauro M, D'Alessandro S, Teodori G, Vitolla G, Contini M, et al. Revascularization of the lateral wall: long-term angiographic and clinical results of radial artery versus right internal thoracic artery grafting. *J Thorac Cardiovasc Surg* 2002;123(2):225-31.
8. He GW. Arterial grafts for coronary artery bypass grafting: biological characteristics, functional classification, and clinical choice. *Ann Thorac Surg* 1999;67(1):277-84.
9. Manabe S, Sunamori M. Radial artery graft for coronary artery bypass surgery: biological characteristics and clinical outcome. *J Card Surg* 2006;21(1):102-14;115.
10. Ozkan M, Aslan A, Oguz M, Yildirim C, Oktar L, Ergül G, et al. A carbon dioxide insufflation technique for preparation of the internal thoracic artery. *J Thorac Cardiovasc Surg* 2003; 125(4):963-4.