

Topographic Changes After Suture Removal in Patients with Penetrating Keratoplasty

Penetran Keratoplastili Hastalarda Sütür Alımı Sonrası Topografik Değişiklikler

Bora YÜKSEL,^a
Umut Duygu UZUNEL,^a
Damla AYDIN,^a
Tuncay KÜSBECİ^a

^aClinic of Ophthalmology,
İzmir Bozyaka Training and
Research Hospital,
İzmir

Geliş Tarihi/Received: 25.06.2016
Kabul Tarihi/Accepted: 06.01.2017

Yazışma Adresi/Correspondence:
Bora YÜKSEL
İzmir Bozyaka Training and
Research Hospital,
Clinic of Ophthalmology, İzmir,
TÜRKİYE/TURKEY
drborayuksel@gmail.com

ABSTRACT Objective: To investigate the changes in topographic parameters after suture removal in patients with penetrating keratoplasty (PK) and to assess the predictability of these changes. **Material and Methods:** This prospective study included 88 eyes of 88 corneal graft patients. Fifty-one were male and 37 female. Mean age was 52.5±18.3 years. Main indications were keratoconus (23) and bullous keratopathy (18). Donor corneas were cut from the endothelial side with a disposable donor punch and sutured into the recipient bed with single 10-0 nylon running suture. Sutures were removed at 1 year. Corneal topographies were acquired with Keratograph (Oculus, Wetzlar, Germany) immediately before and one month after suture removal. Flattest and steepest keratometry (K) values (Diopter:D), magnitude and axis of the astigmatism, eccentricity (Ecc), Q value, analyzed area and topographic patterns were recorded. **Results:** Mean K value increased from 42.18±4.97 (30.65-53.20) to 44.46±4.10 (29.45-55.20) D (p=0.001). Mean astigmatism increased from 4.66 to 5.68 D (p=0.017). Ecc value decreased from 0.48 to 0.11 (p=0.000). Analyzed area increased from 36.90 to 41.44% (p= 0.012). Prolate topographic patterns decreased from 42.0% to 36.4%, oblate patterns increased from 26.1% to 39.8% after suture removal. **Conclusion:** Mean K value increased 2.3 D after suture removal, meaning a myopic shift in refraction. Topographic analysis can be acquired in a wider area. Overall oblate and ellipsoid geometry of the cornea, determined by the Q and Ecc values, remains the same after suture removal.

Keywords: Keratoplasty, penetrating; corneal topography

ÖZET Amaç: Penetran keratoplastili (PK) hastalarda sütür alımı sonrası topografik parametrelerdeki değişimleri incelemek ve bu değişikliklerin öngörülebilirliğini değerlendirmek. **Gereç ve Yöntemler:** Bu prospektif çalışma 88 korneal greft hastasının 88 gözünü içermektedir. Bu hastaların 51'i erkek ve 37'si kadındı. Ortalama yaş 52.5 ± 18.3 yıldır. Başlıca endikasyonlar keratokonus (23) ve bül-löz keratopati (18) idi. Donör kornealar tek kullanımlık donör punch ile endotel yüzünden kesildi ve alıcı yatağa 10-0 naylon sütür ile kontinü olarak sütüre edildi. Sütürler 1. yılda alındı. Korneal topografiler Keratograph (Oculus, Wetzlar, Germany) ile sütür alımından hemen önce ve 1 ay sonra yapıldı. En düz ve en dik keratometri (K) değerleri (Diyoptri: D), astigmatizmanın gücü ve aksı, ekzantrisine (Ecc), Q değeri, analize edilen bölge, topografik paternler kaydedildi. **Bulgular:** Sütür alımından sonra ortalama K değeri 42,18±4,97 (30,65-53,20) D'den 44,46±4,10 (29,45-55,20) D'ye (p=0,001), ortalama astigmatizma 4,66 D'den 5,68 D'ye yükseldi (p=0,017). Ecc değeri 0,48'den 0,11'ye düştü (p<0,001). Analize edilen alan %36,90'dan %41,44'e yükseldi (p=0,012). Sütür alımı sonrası prolat topografik paternler %42,0'den %36,4'e düşerken, oblat paternler %26,1'den %39,8'e yükseldi. **Sonuç:** Ortalama K değeri sütür alımı sonrası 2,3 D arttı, bu refraksiyonda miyopik değişim demektir. Topografik analiz daha geniş bir alanda elde edilebilmektedir. Korneanın Q ve ekzantrisine değerlerinin gösterdiği oblat ve elipsoid geometri, sütür alımı sonrasında da değişiklik göstermedi.

Anahtar Kelimeler: Keratoplasti, penetran; kornea topografisi

Although component layer grafting of the cornea is available, penetrating keratoplasty (PK) remains a viable option especially in diseases involving all layers of the cornea.¹ However, corneal astigmatism is a common complication of PK that can prevent a good visual outcome in an eye with a clear graft.²⁻⁵ In recent studies, mean postoperative topographic astigmatism exceeding 6 diopters (D) has been reported in patients undergone PK.^{6,7} Factors influencing the amount of astigmatism include the severity of underlying disorder (eg keratoconus), oval or eccentric trephination, graft size, donor recipient disparity, corneal thickness mismatch between donor and the recipient, a poor suturing technique and time of suture removal or adjustment.⁸

Astigmatism can be evaluated by using manifest refraction, keratometry, corneal topography and occasionally wavefront analysis. Refraction and keratometry indicate only one steep and one flat meridian, which is inaccurate in keratoplasty patients who have irregular or complex astigmatism.³ Corneal topography is a better guide to assess a wider surface area of the cornea and provides more information in cases of irregular astigmatism.^{9,10}

Previous studies have described the unique topographic patterns seen after PK.¹¹ These patterns may show substantial changes after suture removal and these changes are usually unpredictable.¹² An improvement may be seen in some cases after suture removal whereas a worsening of the astigmatism may occur in others. Aim of this study is to investigate the changes in topographic parameters after suture removal in patients with PK and assess the predictability of these changes.

MATERIAL AND METHODS

This prospective study included 103 eyes of 103 PK patients operated between September 2011 and February 2015. Consecutive patients with readable corneal topographic maps acquired immediately before and 1 month after suture removal were assessed. Five patients whose topography couldn't be acquired before suture removal and 10 patients

after suture removal were excluded. Cases with wound dehiscence and infection after suture removal were also excluded from the study. Thus, statistical analysis was performed on the data of remaining 88 PK patients. An informed consent was taken from all patients. The study was conducted under the considerations of Helsinki Declaration.

TECHNIQUE

All patients were operated under general anesthesia. Operations were performed by one surgeon (BY) using the same suturing technique in all cases. The donor tissue was prepared by trephining the donor cornea from the endothelial side with a disposable donor punch (Altomed, Boldon Business Park, UK). The donor button was trephined 0.25 mm larger than the host in keratoconus patients and 0.50 mm larger in the rest of the cases. Recipient trephination was performed with a Hessburg-Barron vacuum trephine (Altomed, Boldon Business Park, UK). The donor cornea was sutured into the recipient bed with a 16-20 bite, single 10-0 nylon running suture. Intraoperative suture adjustment was performed in patients with smooth epithelial surface by using an Avni-Bartov Disc (Morcher, Stuttgart, Germany).

Postoperative care: Topical steroids were administered hourly initially and then reduced to four times daily. The dose tapered further depending on the condition of the eye. At the end of six months, prednisolone acetate 1% switched to fluoromethalon 5% two times daily and antibiotics ceased. Mydriatics were used for two weeks or longer if the uveitis persists. Oral acyclovir was used in herpes simplex cases to minimize the risk of recurrences. Intraocular pressure was closely monitored in the postoperative period and antiglaucomatous agents were started if it's high.

At the end of one year, running sutures were removed. A corneal topography was acquired with Keratograph (Oculus, Wetzlar, Germany), immediately before suture removal and repeated one month after suture removal. Topographic parameters including the flattest K (K1), the steepest K (K2) values, magnitude and axis of the astigmatism, eccentricity (Ecc), Q value (Q cor) and analyzed

area (AA) were recorded. Topographic patterns were classified as described by Karabatsas et al.¹¹ All the data were recorded into a Microsoft Excel sheet.

STATISTICAL ANALYSIS

Data were analyzed with SPSS 17.0 for Windows software. The topographic data prior to and following suture removal of PK cases were compared with paired samples t test. Data were analyzed under 95% confidence interval. P value under 0.05 was considered statistically significant.

RESULTS

Fifty-one of the PK patients were male and 37 were female. Mean age was 52.5 ± 18.3 (range, 15-84) years. PK indications of the cases are shown in Table 1. Major indications for PK were keratoconus (26.5%) and bullous keratopathy (20.5%).

Mean K increased from 42.18 ± 4.97 D (30.65-53.20) D to 44.46 ± 4.10 (29.45 – 55.20) D after suture removal. Mean increase in K value was 2.28 ± 5.14 (1.02 – 3.54) D. This increase was found statistically significant ($p=0.001$). Changes in the topographic parameters before and after suture removal are shown in Table 2. A statistically significant increase in both mean flat K ($p=0,001$) and steep K ($p=0,001$) values was observed after suture removal. Mean astigmatism increased by 1,02 D. It increased from 4.66 to 5.68 D after suture removal. This change was also statistically significant ($p=0,017$).

Topographic astigmatism increased more than 5.0 D in 8 cases (9.1%). PK indication was bullous keratopathy in 3, keratoconus in 2, leucoma in 2 and stromal dystrophy in 1 of these eight eyes. As a subgroup analysis, keratoconus and bullous keratopathy groups were compared in terms of changes in astigmatism before and after suture removal. However, no statistically significant was found between two groups ($p=0.380$, independent t test). An increase in astigmatism ≥ 5.0 D occurred in 2/23 (8.7%) of keratoconus cases and 3/18 (16.7%) of BKP cases. Corneal astigmatism decreased more than 5.0 D in 2 cases (2.3%) following suture removal. The proportion of the area analyzed by topography device enlarged significantly after suture removal ($p=0.012$). A statistically significant decrease in mean Ecc was observed following suture removal ($p=0.000$). The increase in astigmatism axis and the decrease in mean Q cornea values were not statistically significant.

TABLE 1: Indications for penetrating keratoplasty.

Indication for surgery	Number	%
Keratoconus	23	26.1
Bullous keratopathy	18	20.5
Stromal dystrophies	10	11.4
Herpetic scar	10	11.4
Leucoma	9	10.2
Regraft	7	7.9
Fuchs dystrophy	5	5.7
Traumatic scar	3	3.4
Trachoma	3	3.4
Total	88	100

TABLE 2: Changes in mean values of the topographic parameters before and after suture removal.

Parameter (n= 88)	Before suture removal	After suture removal	p value*
Kmin (D)	39.93 ± 5.25 (23.30-51.00)	42.11 ± 4.48 (27.9-56.1)	0.001
Kmax (D)	44.43 ± 5.30 (31.40-58.30)	46.82 ± 4.92 (31.00-59.40)	0.001
Astigmatism (D)	4.66 ± 3.32 (0.20-25.40)	5.68 ± 3.32 (0.20-19.10)	0.017
Axis (degree)	85.39 ± 55.13 (1.00-179.40)	91.65 ± 55.77 (5.30-179.50)	0.368
Eccentricity	0.48 ± 0.60 (-2.35-1.16)	0.11 ± 0.58 (-1.17-1.60)	0.000
Q cornea	11.58 ± 0.65 (9.60-14.10)	11.38 ± 1.35 (0.00-13.60)	0.137
Analyzed area (%)	36.90 ± 13.80 (5.00-61.00)	41.44 ± 13.91 (0.00 – 69.00)	0.012

* Paired t test

Values were showed as mean±standard deviation (min-max). Statistically significant p values were written in bold. K: keratometry, D:dioptr.

TABLE 3: Changes in topographic patterns, according to Karabatsas classification, before and after suture removal.

Topographic patterns	Before suture removal	After suture removal
	n (%)	n (%)
Regular patterns	35 (39.8)	43 (48.9)
PSBT	3 (3.4)	2 (2.3)
PABT	18 (20.5)	15 (17.0)
OSBT	3 (3.4)	3 (3.4)
OABT	9 (10.2)	21 (23.9)
Oval	2 (2.3)	2 (2.3)
Irregular patterns	53 (60.2)	45 (51.1)
PI	16 (18.2)	15 (17.0)
OI	11 (12.5)	11 (12.5)
Other	5 (5.7)	5 (5.7)
Unclassified	21 (23.8)	14 (15.9)
Total	88 (100.0)	88 (100.0)

PSBT: Prolate symmetric bow tie; PABT: Prolate asymmetric bow tie; OSBT: Oblate symmetric bow tie; OABT: Oblate asymmetric bow tie; PI: Prolate irregular; OI: Oblate irregular.

The changes in topographic patterns, according to Karabatsas classification, before and after suture removal are shown in Table 3. Abbreviations in the table are as follows: Prolate symmetric bow tie (PSBT), prolate asymmetric bow tie (PABT), oblate symmetric bow tie (OSBT), oblate asymmetric bow tie (OABT), prolate irregular (PI) and oblate irregular (OI). As may be seen in the table, prolate patterns decreased in number from 37/88

(42.0%) to 32/88 (36.4%) after suture removal whereas oblate patterns increased from 23/88 (26.1%) to 35/88 (39.8%). Figure 1 shows topographies of a typical case. Before suture removal (on the left hand side): Pattern: OI. K1: 32.60D, K2: 37.90D, astigmatism: 5.4D and K: 35.25D. After suture removal (right hand side): Pattern: OABT. K1:41.5 D, K2:50.40 D, astigmatism 8.9D and K 45.95D.

Changes in the distribution of regular, irregular or unclassified patterns before and after suture removal was not found statistically significant ($p=0.192$, Chi-square test). In two main indications (keratoconus and BKP) transition from prolate (P) pattern to oblate (O) pattern while all sutures out were analyzed. In keratoconus group ($n=23$) P to O transformation occurred in 3 eyes (13.0%), whereas O to P change was not observed. In BKP eyes ($n=18$), P to O transformation occurred in 1 eye (5.5%) and O to P change in 2 eyes (11.1%). Although number of eyes are not sufficient for statistical analysis, transition from O to P pattern was more frequent in BKP. This may be a result of more central steepening and peripheral flattening occurring in BKP eyes following suture removal. In two eyes from each group O pattern did not change before and after suture removal. P pattern remained the same in 4 eyes (17.4%) in keratoconus group and 2 eyes (11.1%) in BKP group.

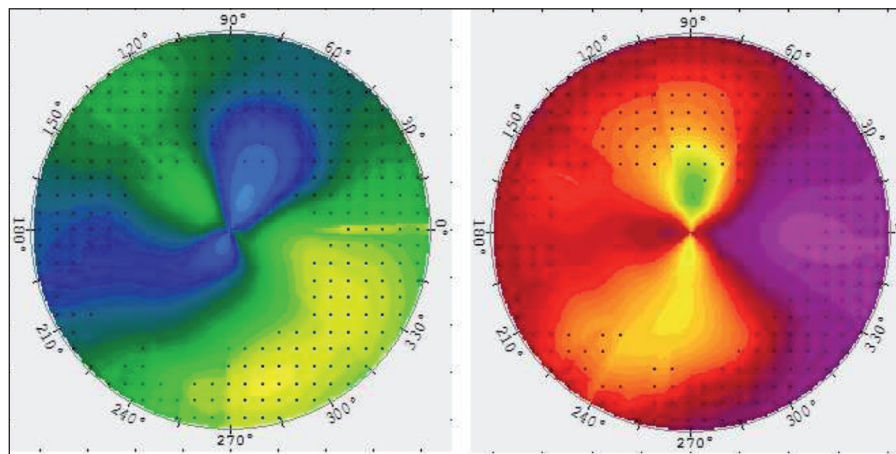


FIGURE 1: Corneal topographic maps of a typical PK case before and after suture removal. Although, some steepening took place, oblate asymmetric bow-tie pattern persisted after suture removal.

DISCUSSION

Sutures were removed at one year in our study, since complete wound healing occurs in one year in most of the cases. Late removal may be associated with complications including spontaneous loosening and infection.¹³ Besides, Goren et al. reported unpredictable changes in patients whose sutures were removed 20 months after surgery.¹⁴ Wound dehiscence after suture removal requiring additional sutures may be encountered in the elderly.¹⁵ Such cases excluded from the study, since surface topography drastically change in these cases.

In our study, K1, K2 and mean K values increased significantly indicating a corneal steepening after suture removal. The explanation for this observation may be the disappearance of flattening compression of the running sutures. A progressive corneal steepening and an increase in astigmatism was reported after suture removal in keratoconus patients with PK.¹⁶ However, these changes only differed from the changes in Fuchs dystrophy patients 10 years after PK. Additionally, keratoconus patients comprised only 26.1% of our cases. Therefore, corneal steepening after suture removal can not be attributed solely to the changes observed in keratoconus patients.

Various results have been reported about the change in astigmatism after removal of keratoplasty sutures. Lin et al reported no change from a mean of 5.3 D corneal astigmatism after suture removal.¹⁷ Graft size and centration, suture tension and wound adaptation are important factors affecting postoperative astigmatism.¹⁸ Mean topographic astigmatism increased from 4.66 D to 5.68 D after suture removal in our patients, this change (+1,02 D) was statistically significant ($p=0.017$). An increase in astigmatism $> 5,0$ D was observed in bullous keratopathy eyes (11,1%) more than keratoconus eyes (8,7%) in our study. This finding may be a result of the distorted corneal surface secondary to previous complicated cataract surgery. This irregularity masked by running sutures while sutures are in place may become obvious following the removal of the sutures. In Seitz et al's study, nonmechanical excimer laser PK has been per-

formed on patients without previous surgery. They used 0.1mm oversized graft and double running cross-stitch suture. First running suture has been removed at 14 months and second suture at 20 months. Mean astigmatism after laser PK for keratoconus was reported as 3.3 D when sutures were in place and 2.5 D after suture removal. These values were 3.5 D and 3.0 D in Fuchs dystrophy patients respectively. They found no statistically significant difference between Fuchs and keratoconus either before or after suture removal. These finding indicates that the irregularities of the host rim in keratoconus patients did not result in higher astigmatism as compared to patients with Fuchs (regular host rim).¹⁸ Since wound apposition and centralization is better in excimer laser PK, direct comparison of its outcomes with mechanical PK used in our study is not reliable. Shimazaki and Tsubota¹⁹ concluded that the suture removal after PK was advantageous for both reducing astigmatism and normalizing topography, especially in eyes with localized flattening at the midperipheral cornea. Eyes with skewed astigmatism axis or topographic astigmatism more than 1 dioptries showed significant decrease in astigmatism in their study.

Solomon et al. observed the maximum changes in dioptric power and axis of the flat and steep meridians in the first hour after suture removal.¹² 0.43 D decrease in steep K at the first hour and 0.70 D increase at the first week has been found after suture removal. They suggested that the corneal topographic pattern and changes in astigmatism were unpredictable and complex. Predictability of visual outcomes of a running suture removal may be improved by the use of topography.¹⁹ Most of the topographic changes occur immediately after suture removal. However, continued shifting in corneal curvature may take place over 4-6 weeks.¹⁴ Topographic instability might be expected to regularize in midterm.¹⁶ In our study, a statistically significant increase in AA was observed after suture removal. It suggests that the surface area analyzed by the topographer becomes wider. Additionally, proportion of regular patterns increased from 39.8% to 48.9%. While unclassified pattern was the most common pattern (23.8%) before suture re-

moval, oblate asymmetric bow tie became the most common after suture removal (23.9%). These findings indicate an improvement in surface regularity after suture removal. Asymmetric bow tie has been reported to be the most common topographic pattern both before and after suture removal.¹⁹ In parallel with this report, it was the most common pattern before 27/88 (30.1%) and after suture removal 36/88 (40.9%) in our cases.

Ecc is a topographic parameter indicating the shape of the cornea. The Ecc value designates the amount by which the cornea diverges from a perfect sphere. This value is 0 for a sphere, 0.1-0.9 for an ellipsoid and 0.3-0.6 for an average cornea.²⁰ In our study, the statistically significant decrease in Ecc from 0.48 to 0.11 suggests that the corneal surface becomes more spherical after suture removal, yet still an ellipsoid. Negative Ecc values may be seen following keratoplasty.²¹ Q value is an indicator of asphericity of the cornea. A spherical cornea has the same radius over the whole cornea. Prolate means (negative Q cor) the radius in the periphery is larger than the center, oblate (positive Q cor) is the opposite. Average Q cor for a normal cornea is -0.26 to -0.42 and 0 for a sphere.²² Almost all postkeratoplasty corneas have been reported to be oblate.³ In parallel with this observation, mean Q cor was found 11.58 before and 11.38 after suture removal in our patients. Both of these values mean oblate corneas and this pattern did not change significantly after suture removal ($p=0.137$).

The results of our study suggest that, the mean corneal power increases approximately 2.3 D after suture removal following PK meaning a myopic shift in patient's refraction. Astigmatism may increase after suture removal. Topographic analysis can be acquired in a wider area after suture removal. Ellipsoid geometry of the cornea, judged by the Ecc value, remains the same, although it becomes closer to a sphere after suture removal. Oblate shape of the grafted corneas doesn't change. Finally, regular topographic patterns increase, while irregular patterns decrease after removal of a single running 10-0 nylon suture. In conclusion, PK operated patients should be informed about possible refractive changes after suture removal. Especially increase in myopia and astigmatism may require correction.

Acknowledgements

Special thanks to our eye bank staff for their efforts in acquisition of the topographic analyses.

Conflict of Interest

Authors declared no conflict of interest or financial support.

Authorship Contributions

Idea/Concept: Bora Yüksel; **Design:** Bora Yüksel; **Control/Supervision:** Tuncay Küsbeci; **Data Collection and/or Processing:** Bora Yüksel, Damla Aydın; **Analysis and/OR Interpretation:** Bora Yüksel, Umut Duygu Uzunel; **Literature Review:** Bora Yüksel, Damla Aydın; **Writing the Article:** Bora Yüksel; **Critical Review:** Tuncay Küsbeci.

REFERENCES

1. Angunawela RI, Riau A, Chaurasia SS, Tan DT, Mehta JS. Manual suction versus femtosecond laser trephination for penetrating keratoplasty: intraocular pressure, endothelial cell damage, incision geometry, and wound healing responses. *Invest Ophthalmol Vis Sci* 2012;53(6):2571-9.
2. Fares U, Sarhan AR, Dua HS. Management of post-keratoplasty astigmatism. *J Cataract Refract Surg* 2012;38(11):2029-39.
3. Sarhan AR, Dua HS, Beach M. Effect of disagreement between refractive, keratometric, and topographic determination of astigmatism on suture removal after penetrating keratoplasty. *Br J Ophthalmol* 2000;84(8):837-41.
4. Cleary C, Tang M, Ahmed H, Fox M, Huang D. Beveled femtosecond laser astigmatic keratotomy for the treatment of high astigmatism post-penetrating keratoplasty. *Cornea* 2013;32(1):54-62.
5. Wade M, Steinert RF, Garg S, Farid M, Gaster R. Results of toric intraocular lenses for post-penetrating keratoplasty astigmatism. *Ophthalmology* 2014;121(3):771-7.
6. Wetterstrand O, Holopainen JM, Krootila K. Treatment of postoperative keratoplasty astigmatism using femtosecond laser-assisted intrastromal relaxing incisions. *J Refract Surg* 2013;29(6):378-82.
7. Birnbaum F, Wiggermann A, Maier PC, Böhringer D, Reinhard T. Clinical results of 123 femtosecond laser-assisted penetrating keratoplasties. *Graefes Arch Clin Exp Ophthalmol* 2013;251(1):95-103.
8. Feizi S, Zare M. Current approaches for management of postpenetrating keratoplasty astigmatism. *J Ophthalmol* 2011;2011:708736.
9. Tomidokoro A, Oshika T. Quantitative assessment of videokeratography data using fourier series harmonic analysis. *Cornea* 2004;23(8 Suppl):S71-7.
10. Naydis I, Klemm M, Hassenstein A, Richard G, Katz T, Linke SJ. [Postkeratoplasty astigmatism: comparison of three suturing techniques]. *Ophthalmologie* 2011;108(3):252-9.

11. Karabatsas CH, Cook SD, Sparrow JM. Proposed classification for topographic patterns seen after penetrating keratoplasty. *Br J Ophthalmol* 1999;83(4):403-9.
12. Solomon A, Siganos CS, Frucht-Pery J. Corneal dynamics after single interrupted suture removal following penetrating keratoplasty. *J Refract Surg* 1999;15(4):475-80.
13. Bor E, Kremer I. Endophthalmitis and wound dehiscence following late removal of penetrating keratoplasty sutures. *Ophthalmic Surg Lasers Imaging* 2011;42(3):234-40.
14. Goren MB, Dana MR, Rapuano CJ, Gomes JA, Cohen EJ, Laibson PR. Corneal topography after selective suture removal for astigmatism following keratoplasty. *Ophthalmic Surg Lasers* 1997;28(3):208-14.
15. Das S, Whiting M, Taylor HR. Corneal wound dehiscence after penetrating keratoplasty. *Cornea* 2007;26(5):526-9.
16. Raecker ME, Erie JC, Patel SV, McLaren JW, Hodge DO, Bourne WM. Long-term keratometric changes after penetrating keratoplasty for keratoconus and Fuchs Endothelial dystrophy. *Am J Ophthalmol* 2009;147(2):227-33.
17. Lin DT, Wilson SE, Reidy JJ, Klyce SD, McDonald MB, Insler MS, et al. Topographic changes that occur with 10-0 running suture removal following penetrating keratoplasty. *Refract Corneal Surg* 1990;6(1):21-5.
18. Seitz B, Langenbucher A, Szentmary N, Naumann GO. Corneal curvature after penetrating keratoplasty before and after suture removal: a comparison between keratoconus and Fuchs' dystrophy. *Ophthalmologica* 2006;220(5):302-6.
19. Shimazaki J, Tsubota K. Analysis of videokeratography after penetrating keratoplasty: topographic characteristics and effects of removing running sutures. *Ophthalmology* 1997;104(12):2077-84.
20. Courville CB, Kleyce SD. Corneal topography. In: Smolin G, Foster CS, Azar DT, Dohlman CH, eds. *Smolin and Thoft's the Cornea: Scientific Foundations and Clinical Practice*. 4th ed. Philadelphia: Lippincott Williams & Wilkins; 2005. p.181.
21. Gruenauer-Kloevekorn C, Fischer U, Kloevekorn-Norgall K, Duncker GI. Pellucid marginal corneal degeneration: evaluation of the corneal surface and contact lens fitting. *Br J Ophthalmol* 2006;90(3):318-23.
22. Dr. Agarwal's textbook on corneal topography. Agarwal A, Agarwal A, Jacop S editors. New Delhi: Jaypee Bros Medical P Ltd; 2010. p.123.