

A Case of Tuberos Sclerosis

İbrahim KÖKÇAM
Sevil BAKIR
Melda BOLAT

BİR TUBEROUS SCLEROSIS OLGUSU

Fırat University, Department of Dermatology

Geliş Tarihi: 4 Nisan 1989

Kabul Tarihi: 2 Eylül 1989

SUMMARY

Tuberos sclerosis (TS) is a rare and an autosomal dominant neurocutaneous syndrome. The classic features of this disorder are mental retardation, epilepsy, and adenoma sebaceum. The incidence of this disease is estimated to be approximately 1/109.000. Here, an 11 years old patient diagnosed as TS is presented. The patient was examined by using clinical, laboratory, and radiological methods and TS was discussed in all aspects.

KeyWords: Tuberos sclerosis lipilepsy
Adenoma sebaceum.

T J Research Med Sci V.8, US, 1990,447-150

ÖZET

Tuberos seterosis (TS), klasik belirtileri; mental retardasyon, epilepsi ve adenoma sebaceum olan, otozomal dominant geçiş gösteren ve ender görülen nörocutanöz bir sendromdur. Hastalığın iridansının 1/100.000 olduğu tahmin edilmektedir. Burada TS tanısı konulmuş 11 yaşında bir hasta takdim edildi. Hasta klinik, laboratuvar ve radyolojik olarak incelendi ve sonuçları tartışıldı.

Anahtar Kelimeler: Tuberos sclerosis Epilepsi
Adenoma sebaceum.

T Kİ Tıp Bil Araş Dergisi C.8, SS, 19W, 447450

TS is a complex developmental defect with multiple hamartomas in many organs, but particularly the skin, brain, eye, kidney, and heart. The characteristic skin lesions are adenoma sebaceum, epilepsy, and mental retardation. The incidence of the disorder in the U.S. and Western Europe is in the region of 1/100.000. Since the disorder is seen occasionally, we would like to present a case of TS seen in our clinic.

CASE REPORT

An 11 year-old girl was admitted to our clinic complaining of erythema and papules on her face. She developed convulsions three times at the age of 9 months with normal body temperature. Adenoma sebaceum on her face first appeared when she was four years old and increased gradually by the time. There was no remarkable evidence in her family history.

Her physical examination showed; the lesions on her face were firm, discrete, pink papules with telangiectatic vessels. They were distributed symmetrically and were most numerous around the nose and malar areas (Figure 1) These papules were on the gums and lips. Ovoid and ash-leaf-shaped depigmented macules were presented on the extremities, lumbosacral region, and abdomen (Figure 2). She had multiple shagreen patches on the lumbosacral region and the abdomen (Figure 3). She appeared to be of normal abnormalities. There were no systemic symptoms on the physical examination. Ophthalmologic examination showed; on the right retina 2 yellow piques, and retinal oedema in both eyes.

Laboratory studies revealed; Hb, sedimentation rate, fasting blood sugar, platelets, liver function tests, and urinalysis with normal findings. Roentgenograms of skull, elbow, hands, legs, and feet were normal. EEG and echo-cardiography showed no abnormality.

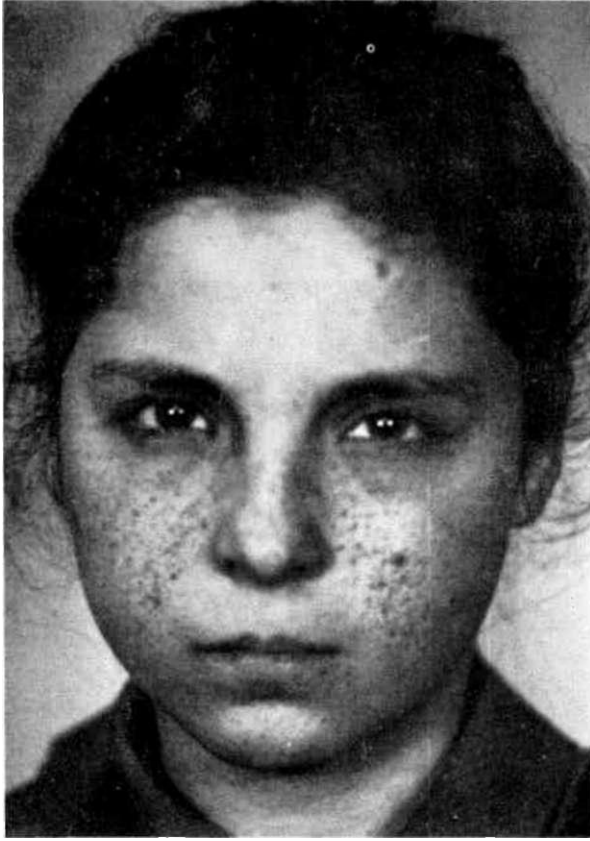

Figure 1. Adenoma sebaceum on the face

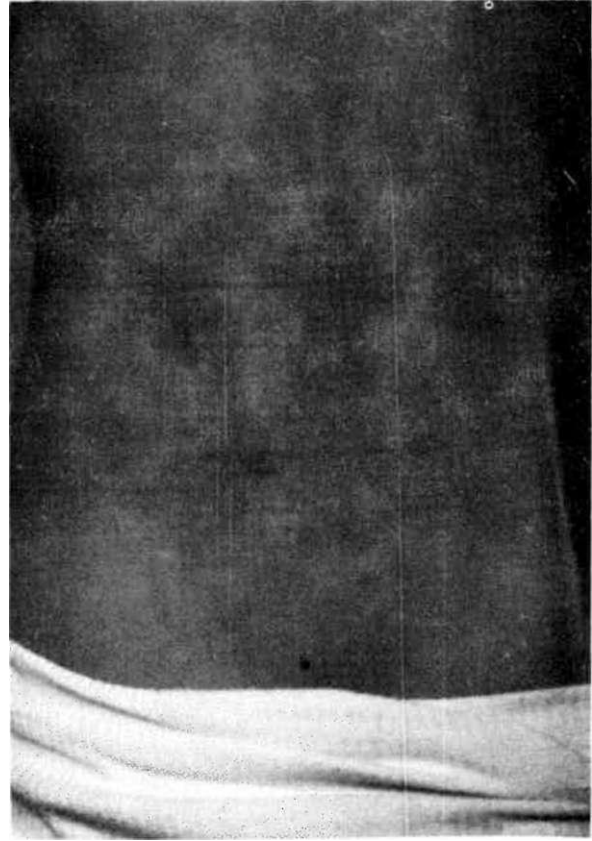


Figure 2. Shagreen patches on the lower back

DISCUSSION

TS is a dominantly inherited disorder commonly manifested in the skin and central nervous system but affecting several other organ systems as well. Both sexes are affected equally and the syndrom has been reported to occur among all race. A round 86 % cases are thought to be the result of new mutation (4,9).

The basic lesion in TS is a neuroectodermal tumor or hamartoma that contain blood vessels, adipose tissue smooth muscle and fibrous tissue (1,3,4,6).

Skin lesions are found in about two-thirds of the patients with TS. Lesions of four types are patognomonic.

The facial cutaneous lesions, the so-called adenoma sebaceum or angiofibroma, may rarely be present at birth, or develop in infancy, but usually appear between the ages 3 and 10. The earliest manifestations of facial angiofibromatosis may be a

mild erythema over the cheeks, nose and forehead. They gradually increase in size but may grow rapidly at puberty and then remain unchanged. Angiofibromas are firm, discrete, yellowish or telangiectatic papules, 4 mm in diameter, extend from the nasolabial furrows to the cheeks and chin, are rarely found in eyelids and in the ears. Fibromatous tumours are occasionally on the gums and palate and very rarely are found on the tongue, larynx and fharynx (1,3,6).

Shagreen patch, an irregularly thickened, slightly elevated, soft, skin-colored plaque, is usually in the lumbosacral region. They usually appear during childhood. It is present in 70 % of adults and in 21 % of children with TS (5-6).

Depigmented patches occur in 50 % of the cases with TS. These lesions are ovoid or ash-leaf-shaped, and most easily detectable by examination under Wood's light, are frequently present on the trunk or limbs. They are very valuable physical

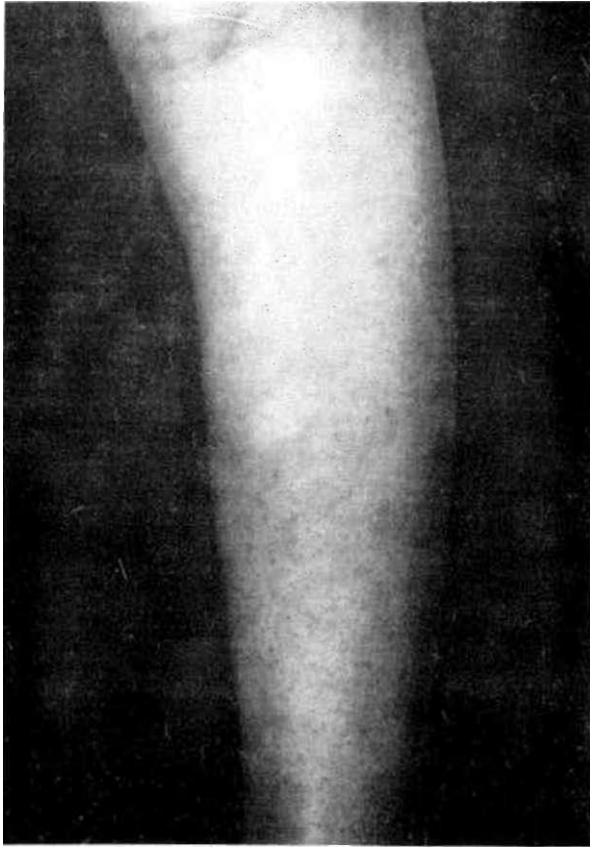


Figure 3. Depigmented macules on the leg

signs, for they may be found at birth or in early infancy, some years before other cutaneous signs of the disease develop, may suggest the correct diagnosis in infants with convulsions (7,8).

Other skin lesions seen frequently but non-pathognomonic, include fibroepithelial tags, café au lait spots, hemangiomas, pigmented nevi, poliosis, lipomas, and syngocystadenomas (4,6).

Periungual and subungual fibromata (Koenen's tumors) occur in about 50 % of patients and appear at or after puberty. They are often multiple (1,4,6).

Mental retardation is present in 60-70 % of cases may also be progressive. Mental development may be found normal throughout childhood but subsequent deterioration is uncommon (3). Same cases have presented graduated from university has been reported (2).

Epilepsy is seen in almost all mentally retarded patients. In most cases it begins in infancy or early

childhood, thus often preceding the skin lesions by many years. Occasionally epilepsy begins at puberty or adult life. Epilepsy becomes more frequent and severe with TS have a history of spasms in infancy (9). Our case had a history of infantile spasms. Intracranial tumors are uncommon. These lesions are presumably responsible for epilepsy, retardations, and psychotic changes (6).

Retinal lesions known as phakomas, occur in 50 % of cases, but may be hard to detect. Pigmentary and the other retinal anomalies can occur (1,4,9).

Renal and cardiac hamartomas are usually asymptomatic unless by reason of their size or site. Renal lesions increase in size and number with age. They may simulate polycystic disease (3,8,9).

Pulmonary lesions are rare and seldom cause symptoms. They may rupture and produce pneumothorax, pulmonary insufficiency, and death. Pulmonary changes may be detected by a chest film. It shows a coarse, mottled, honeycomb appearance in the lungs (3,6).

Laboratory findings: Intracranial lesions occasionally become calcified and are rarely detectable in infancy. They are usually not apparent until later childhood or adult life. Computerized axial tomography may facilitate the early diagnosis of intracranial lesions (3,7,9). Cortical thickening is seen in long bones. Cystic lesions of the phalanges and irregular thickening of the cortex of metatarsals and metacarpals have been reported, and similar lesions localized in vertebrae, pelvis are seen (1,4,6).

A high percentage of patients have electroencephalographic abnormalities, but the changes are not specific (6).

The diagnosis of TS is apparent when the classical triad of adenoma sebaceum, epilepsy, and mental retardation is present. In the absence of the latter two components of the syndrome, diagnosis depends on the cutaneous lesions, particularly those considered characteristic (adenoma sebaceum, Koenen's tumors, shagreen patch and depigmented macules). Retinal phakomas are also diagnostic. Affected patients with normal intelligence have been described (2,7).

Prognosis is good in patients with only skin lesions. Survival of the case which is fully developed in infancy is poor, 3 % of the patients die in the first year, 28% under 10 and 75% before 28. Death may result from epilepsy, intercurrent infection but occasionally from an acute heart failure, or renal or pulmonary insufficiency (3,6).

Adenoma sebaceum can be improved by diathermy or dermabrasion. Gingival and subungual fibromas can be treated similarly. Epilepsy may be controlled by anticonvulsants. The treatment of lesions in other organs is unsatisfactory; surgical interventions may be required to relieve the symptoms (1,4,6).

REFERENCES

1. Adams RD: Neurocutaneous diseases. In Fitzpatrick TB., Eisen AZ., Wolf K. et al eds Dermatology in General Medicine. McGraw-Hill Book Co., New York, vol.2 pp: 2029-2032,1987.
2. Aras N, Memişoğlu H, Arslan M.: Yüksek Tahsili Bir Hastada Behçet Hastalığı ile Birlikte Görülen Tuberos Sclerosis, 8. Ulusal dermatoloji kong. 484490, 1982.
3. Burton JL, Rook A.: Genetics in dermatology. In Rook A, Wilkinson DS., Ebling FJG. et al eds Textbook of Dermatology. Blackwell Scientific Publ, pp: 122-125,1986.
4. Carter DM, O'Keefe EJ.: Hereditary cutaneous disorders. In Moschella S., Pillsbury D., Hurley H. eds Dermatology. W.B. Saunders Co., Philadelphia, pp: 1188-1192,1986.
5. Domonkos AN, Arnold HL, Odom RB.: Diseases of the Skin, W. B. Co., Philadelphia, pp: 695-697,1982.
6. Koblenzer CS.: Tuberos sclerosis. In Demis DS. ed Clinical Dermatology. Harper and Row. Publ. Philadelphia, Vol. 4 Unit 24-1 pp:1-10, 1987.
7. Nagib MO., Haines SJ., Erickson DL, Mastri A.: Tuberos sclerosis: A review for the neurosurgery. 14/1: 93-98, 1984.
8. O'Callaghan TJ., Edwards JA., Tobin M, et ail.: Tuberos sclerosis with striking renal involvement in al family. Arch Inter Med. 135:1082-1087,1975.
9. Wilson RD, Hall JG, McGilivray BC: Tuberos sclerosis: case report and investigation of family members. Can Med Assoc J, 132: 107-809,1985.