

Calcified Chronic Subdural Hematoma: Case Report

Kronik Kalsifiye Subdural Hematom

Şanser GÜL, MD,^a
Ferda ÇAĞAVI, MD,^a
Murat KALAYCI, MD,^a
Bektaş AÇIKGÖZ, MD^a

^aDepartment of Neurosurgery,
Zonguldak Karaelmas University,
School of Medicine, ZONGULDAK

Geliş Tarihi/Received: 01.09.2008
Kabul Tarihi/Accepted: 03.11.2008

Yazışma Adresi/Correspondence:
Şanser GÜL, MD
Zonguldak Karaelmas University
Medical School,
Department of Neurosurgery,
ZONGULDAK
drsanser@yahoo.com

ABSTRACT Calcified chronic subdural hematoma (CCSDH) is a relatively rare condition. It is unknown why some chronic subdural hematomas (CSDH) calcify and some do not. Obviously, calcification does not depend on the persistence of the hematoma alone. A 35 years old man with a history of head trauma at 5 years old presented with headache and nausea. Neurological examination revealed a left sided sequel spastic hemiparesis, more pronounced on the distal part of the extremities. Computerized Tomography (CT) and Magnetic Resonance Imaging (MRI) scan revealed a huge CCSDH covering the right hemisphere. The calcified hematoma was evacuated by right frontotemporoparietal craniotomy resulting in disappearance of the headache and nausea symptoms.

Key Words: Calcification, subdural hematoma, computed tomography

ÖZET Kalsifiye kronik subdural hematom nisbeten nadir görülen bir durumdur. Neden bazı kronik subdural hematom'ların kalsifiye olduğu halde bazılarının olmadığı bilinmemektedir. Açıkçası kalsifikasyon tek başına hematomun varlığına bağlı değildir. Beş yaşında iken kafa travması geçirmiş olan 35 yaşındaki erkek hasta başağrısı ve bulantı şikayetleri ile başvurdu. Nörolojik muayenesinde, solda distalde belirgin sekel spastik hemiparezi saptandı. BT ve MRG'de, sağ hemisferik yerleşimli büyük boyutta kalsifiye kronik subdural hematom görüldü. Sağ frontotemporoparietal kraniotomi ile kalsifiye hematom boşaltılmasını takiben başağrısı ve bulantı semptomları düzeldi.

Anahtar Kelimeler: Kalsifikasyon, subdural hematom, bilgisayarlı tomografi

Türkiye Klinikleri J Neur 2008;3(3):145-8

Calcified Chronic Subdural Hematoma (CCSDH) is an uncommon condition.^{1,2} There are about a hundred reported cases in the literature. Calcification or ossification can be found in 0.3%-2.7% of CCSDH.^{3,4} and is mostly found in children and young adults.^{3,5,6} Pathogenesis and mechanism of slow calcification by and large remains unclear.

CASE REPORT

A 35 years old man was admitted to our hospital with headache, nausea and muscle spasms on left lower extremity. In his history, he had head trauma at 5 years old. He had fallen down from the first floor of the house and lost his consciousness for a while. He had no seizures. He has had left hemiparesis since then, as a sequel to trauma.

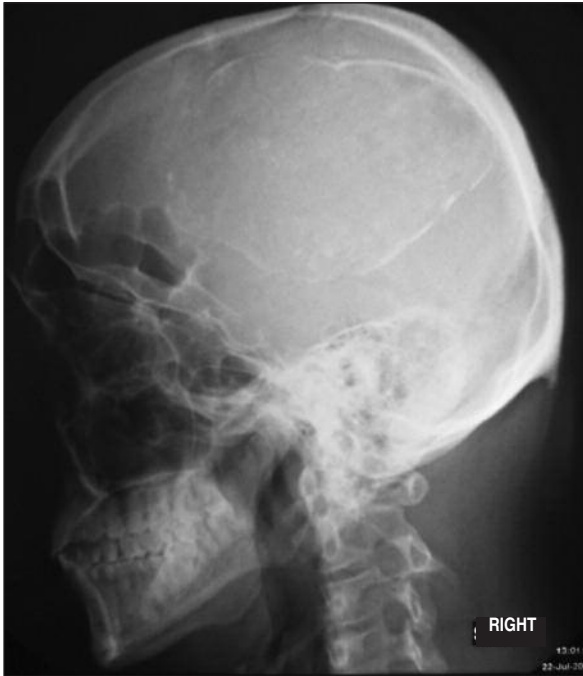

FIGURE 1: Lateral view of skull X-ray film. A large calcified mass is seen over the right fronto-temporo-parietal region.

Neurological examination at our clinic revealed a left sided spastic hemiparesis more pronounced on the distal part of the extremities. He had flexion contracture on his left wrist. His left leg muscles were atrophied and this leg was 3 cm

shorter than the right one. Babinski sign was not present on the left side. Skull X-ray films demonstrated a large calcified mass in the right frontotemporoparietal region (Figure 1). In addition, the computerised tomography (CT) scan showed a CCSDH with a significant mass effect (Figure 2). Craniotomy and excision of CCSDH was performed under general anesthesia.

Right frontotemporoparietal craniotomy was performed with a large skin flap. When duramater was opened, a hard, calcified, dirty yellow-brown mass with paste-like content was encountered in the subdural space (Figure 3a and 3b). The hematoma was not evacuated totally because of excessive hemorrhage from the nearby superior sagittal sinus, which needed 8 units of blood transfusion. Postoperative CT brain scan three days after the operation demonstrated significant relief in the compressive effect of the partially excised CCSDH (Figure 2b). He had no additional focal neurologic deficits apart from the previous hemiparesis.

DISCUSSION

Von Rokitansky described a CCSDH in 1884 and more than a hundred cases have been reported since then.^{7,8} It is unknown why some CCSDHs cal-

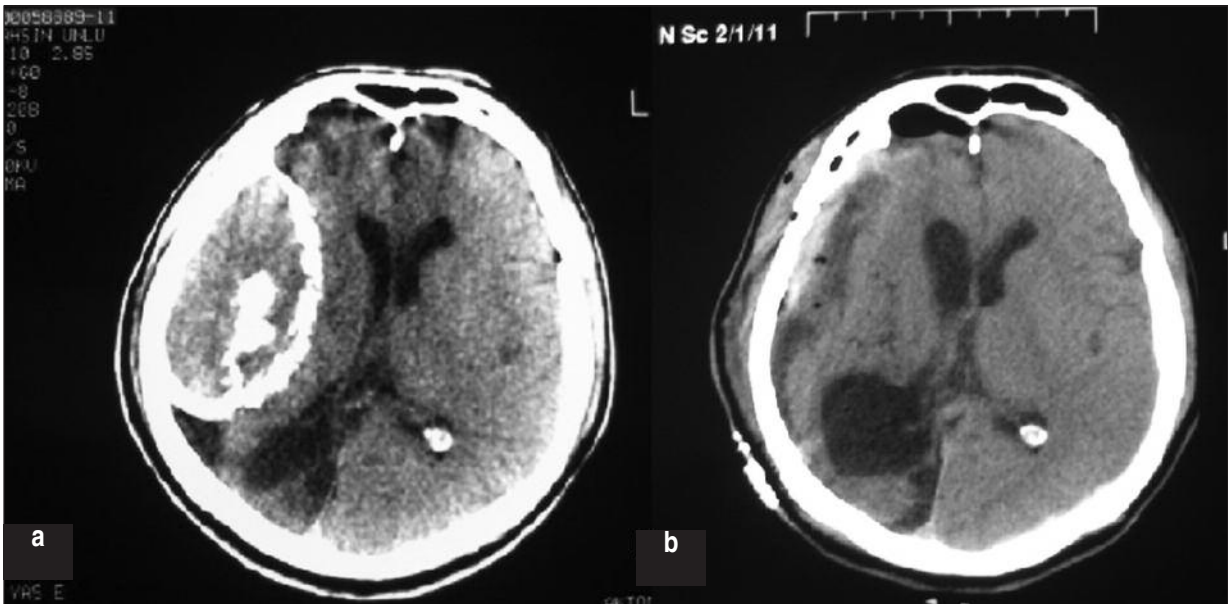


FIGURE 2: (a) Axial brain computerized tomography (CT) image of the large calcified subdural hematoma in the right fronto-temporo-parietal region. (b) Post-operative axial brain CT image showing significant relief in the compressive effect of the partially excised calcified subdural hematoma.

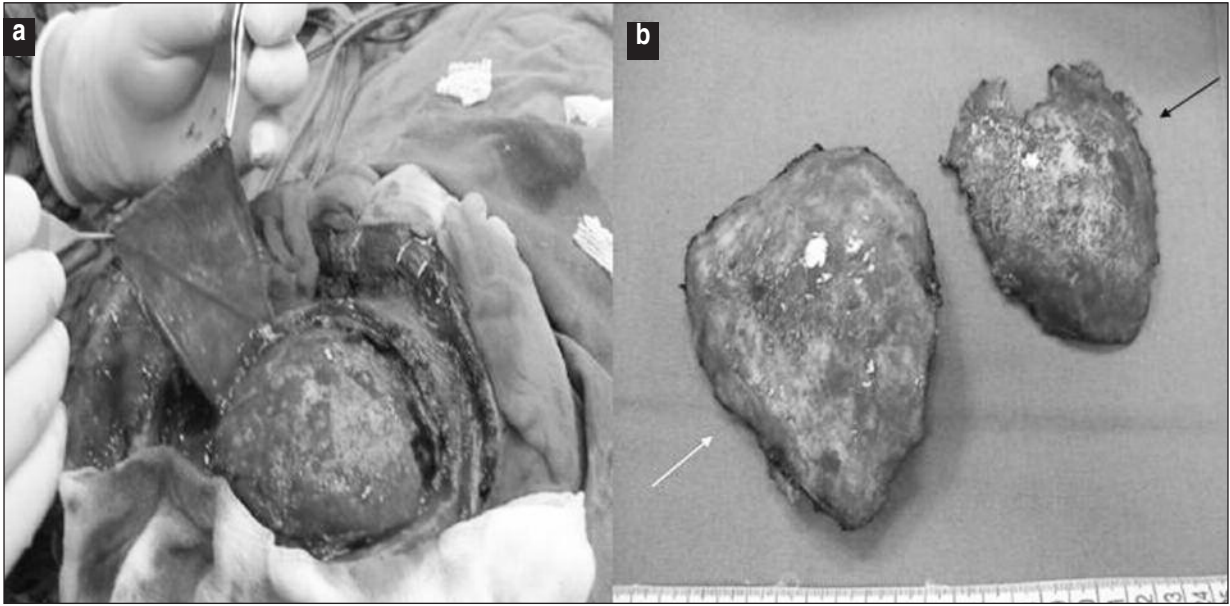


FIGURE 3: (a) Intraoperative photograph showing a huge calcified subdural mass. (b) The mass after removal (black arrow) (white arrow shows craniotomy flap) scale is metric.

cify and some do not. Obviously, calcification does not depend on the persistence of the hematoma alone. In these cases atrophy or brain damage secondary to the initial trauma or inflammatory changes is responsible for the symptoms.¹ The interval between hemorrhage and the development of calcification is generally longer than six months.^{1,3,5,7} Calcification can occur in unilateral or bilateral CCSDHs.^{9,10} Calcification is reported in CCSDH of various etiologies. Several authors have reported calcification in traumatic subdural hematoma (SDH),^{3,4} which is relatively more common than other causes of SDH. Rarely, calcifications are noticed in SDH or subdural effusion secondary to ventricular shunting procedures.^{1,2,11} Calcification is also reported in subdural effusions due to pyogenic meningitis in infants and children.^{1,11} If the calcified wall covers the surface of the cerebrum, this situation is defined as “armored brain”.^{1,3}

Direct surgical treatment to the CCSDH is somewhat controversial.^{3,4,12} In patients with acute or progressing neurological disorders, surgical treatment should be considered; however, it is generally

nonprogressive. Our patient had chronic stable neurological deficits for 30 years and on postoperative 28 months there was not any improvement in the hemiparesis, despite disappearance of the headache and nausea symptoms. We believe that the most significant reason in the late diagnosis was the low sociocultural level and unawareness of the relatives of the patient. CCSDH should be among the reasons in differential diagnosis in the patients with long duration neurological deficits after this type of trauma like our patient.

CSH, calcified epidural hematoma and calcified convexity of the duramater with acute epidural hematoma should be considered in differential diagnosis of an extra-axial calcified lesion.

In conclusion, the result of our case and a review of the literature suggest that proper surgical treatment is recommended for symptomatic patients with CCSDHs.^{2,3,7,12}

Acknowledgement

I would like to thank you Şule Hayırlioğlu for contribution.

REFERENCES

1. Ludwig B, Nix W, Lanksch W. Computed tomography of the "armored brain". *Neuroradiology*. 1983;25:39-43.
2. Sharma RR, Mahapatra AK, Pawar SJ, Sousa J, Athale SD. Symptomatic Calcified Subdural Hematomas *Pediatr Neurosurg* 1999;31:150-4.
3. İplikçioğlu AC, Akkaş O, Sungur R. Ossified chronic subdural hematoma: case report. *J Trauma*. 1991;31:272-5.
4. Waga S, Sakakura M, Fujimoto K. Calcified subdural hematoma in the elderly. *Surg Neurol*. 1979;11:51-2.
5. Chusid JG, de Gutierrez-Mahoney CG. Ossifying subdural hematoma. *J Neurosurg*. 1953;10:430-4.
6. Erşahin Y, Mutluer S. Concerning the article by Sharma et. al., *Pediatr Neurosurg* 1999; 31:150-154. Calcified subdural hematoma. *Pediatr Neurosurg*. 2000;32: 165-6.
7. Kobayashi H, Hayashi M, Kawano H, Handa Y, Noguchi Y, Hayakawa K. Calcified chronic subdural hematoma. Case report. *Zentralbl Neurochir*. 1988;49:119-23.
8. Yamashima T, Ito H, Kubota T, Yamamoto S. Numerous Weibel-Palade bodies in a calcified chronic subdural haematoma. *Neurochirurgia (Stuttg)*. 1987;30:95-8.
9. Spadaro A, Rotondo M, Di Celmo D, Simpatico S, Parlato C, Zotta DC, et al. Bilateral calcified chronic subdural hematoma. Further pathogenetic and clinical consideration on the so-called "armored brain". *J Neurosurg Sci*. 1987;31:49-52.
10. Mosberg WH Jr, Smith GW. Calcified solid subdural hematoma; review of literature and report of an unusual case. *J Nerv Ment Dis*. 1952;115:163-73.
11. He XS, Zhang X. Giant calcified chronic subdural haematoma: a long term complication of shunted hydrocephalus. *J Neurol Neurosurg Psychiatry*. 2005;76:367.
12. Watts C. The management of intracranial calcified subdural hematomas. *Surg Neurol*. 1976;6:247-50.