

# A Rare Type of Testicular Metastasis of Small Cell Carcinoma from the Lung: Case Report and Review of the Literature

<sup>id</sup> Erdinç DİNÇER<sup>a</sup>, <sup>id</sup> Osman Murat İPEK<sup>b</sup>, <sup>id</sup> Burcu HANCI<sup>a</sup>,  
<sup>id</sup> Şükran KAYIPMAZ<sup>c</sup>, <sup>id</sup> Oktay AKÇA<sup>a</sup>

<sup>a</sup>Clinic of Urology, Kartal Dr. Lütfi Kırdar City Hospital, İstanbul, TURKEY

<sup>b</sup>Clinic of Pediatric Urology, Şişli Hamidiye Etfal Training and Research Hospital, İstanbul, TURKEY

<sup>c</sup>Clinic of Pathology, Kartal Dr. Lütfi Kırdar City Hospital, İstanbul, TURKEY

**ABSTRACT** Testicular neoplasms are approximately one percent of all malignancies in men and seen mostly second-to-fourth decade of life. Testicular metastasis is seen very rare in all literature. Most common metastasis site to testis is prostate except hematologic malignancies. However, from lung cancer is seen rarely either. To our knowledge, herein we report one of the rarest case describing a sixty-two year old male patient with the history of small cell carcinoma (SCC) of the lung and underwent chemotherapy-radiotherapy who admitted to the clinic with testicular mass undergone radical orchiectomy. The histopathologic examination revealed metastatic SCC of the lung.

**Keywords:** Testicular neoplasms; small cell carcinoma; tumor metastasis

Testicular neoplasms are approximately one percent of all malignancies in men.<sup>1</sup> Testicular malignancies are the most common solid tumor in men at second-to-fourth decade of life.<sup>2</sup> While 90% of all testicular tumors are germ cell tumors, metastatic tumor of the testis was seen very rare.<sup>3</sup> The primary site that metastasis to testicle is the prostate, the second is the lung except lymphoma and leukemia.<sup>4,5</sup> Besides small cell carcinoma (SCC) of the lung has been reported less than adenocarcinoma.<sup>4,5</sup> To our knowledge, here we report one of the rarest case describing a patient with the history of SCC of the lung and underwent chemotherapy-radiotherapy who admitted to the clinic with testicular mass undergone radical orchiectomy. Based on the patient's medical history and histopathologic examination results, testicular metastasis of SCC of the lung was detected.

## CASE REPORT

A 62-year-old male patient was admitted with a palpable testicular mass. He had a history of SCC of the lung and chemotherapy-radiotherapy with cisplatin-etoposide. Biopsy was performed in 2016 and diagnosed with SCC of the lung. After receiving chemotherapy with cisplatin-etoposide, radiotherapy was applied. The patient presented with testicular swelling after 8 months without recurrence. On physical examination, a painless, approximately 5 cm diameter mass was palpated in left testis. The prostate gland had normal size and shape with digital rectal examination. Scrotal doppler ultrasonography revealed a 4x2 cm solid, hypervascular, heterogeneous mass. Pre-operative alpha-fetoprotein was 6 ng/mL and human chorionic gonadotropin was <1 mIU/mL. The patient underwent

**Correspondence:** Erdinç DİNÇER

Clinic of Urology, Kartal Dr. Lütfi Kırdar City Hospital, İstanbul, TURKEY

**E-mail:** drerdincincer@gmail.com

Peer review under responsibility of Türkiye Klinikleri Journal of Case Reports.

**Received:** 23 Nov 2020

**Received in revised form:** 09 Jan 2021

**Accepted:** 14 Jan 2021

**Available online:** 23 Feb 2021

2147-9291 / Copyright © 2021 by Türkiye Klinikleri. This is an open access article under the CC BY-NC-ND license (<http://creativecommons.org/licenses/by-nc-nd/4.0/>).



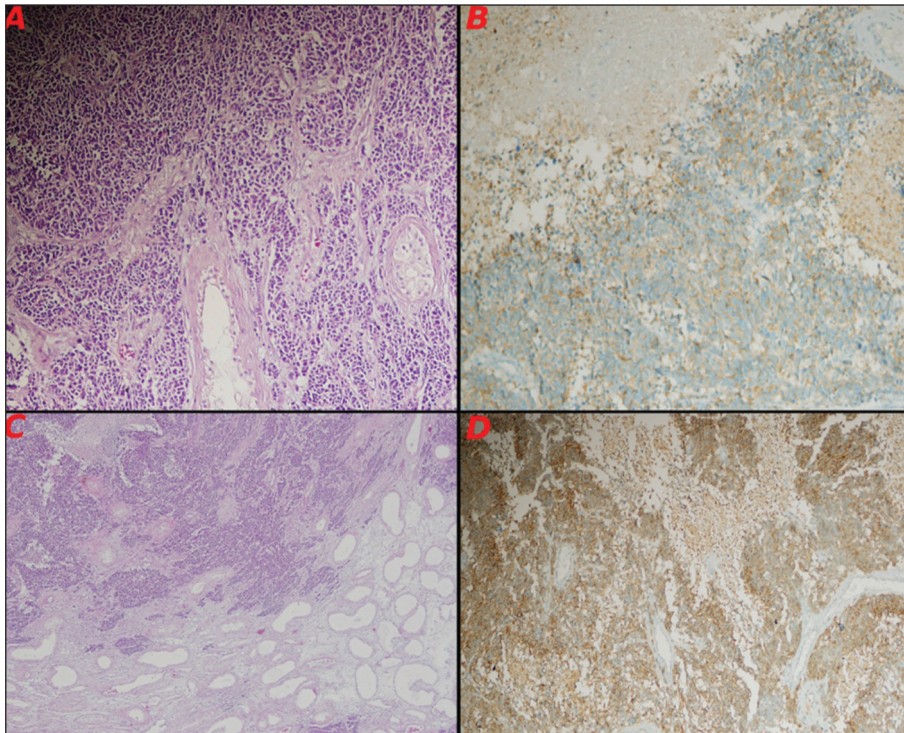
left inguinal radical orchiectomy. He was discharged on postoperative 1. day with no complication. Histopathologic examination revealed a well-circumscribed, 5.2x4.5x3.5 cm tumor with negative surgical margins and involvement to the spermatic cord. The tumor showed positive immunohistochemical staining to CD 56 and the synaptophysin but negative for chromogranin, LCA, TTF-1, napsin-A and SALL4. CK was positive in focal area (Figure 1). This all immunohistochemical pattern and patient's history with the lung cancer supported the diagnosis was metastasis of SCC of the lung with neuroendocrine differentiation. The patient refused additional treatment recommendations and passed away 16 months after radical orchiectomy. Informed consent was obtained from the patient.

## DISCUSSION

Tumors of the testis include metastasis very rarely. In an autopsy series, the incidence of the metastasis from solid tumors to the testis were reported as

0.49%-2.5%.<sup>4,5</sup> Moreover, Garcia-Gonzalez et al. showed that five cases with metastasis to the testis with another autopsy series of 738 patients consists of pancreatic endocrine carcinoma, three from bronchial carcinoma and one from melanoma.<sup>6</sup> Patel and coworkers reported that 13(6%) of 209 patients presented with occult primary testicular tumor similar to our case. Additionally, none of those 13 patients had primary lung cancer.<sup>4</sup>

Among the cases of all literature, the most common primary sites that metastasized to the testis were the prostate, lung, kidney, colon and stomach, respectively.<sup>3</sup> Besides, the reason why prostate cancer has a high frequency of metastasis to testis was probably due to orchiectomy therapeutically.<sup>3</sup> Until now, 11 cases were found with testicular metastasis from lung cancer that was diagnosed without autopsy series.<sup>5</sup> One of this cases was diagnosed with bilateral testicular metastasis. Only 2 cases reported testicular metastases from SCC of the lung.<sup>7,8</sup> To our knowledge, our case is the third



**FIGURE 1:** A- Tumor tissue consists of small round shaped narrow cytoplasm with atypical cells showing frequent mitosis, B- Tumor cells have positive staining with neuroendocrine marker synaptophysin, C- Tumor tissue with large areas of necrosis and infiltrated into the testicle shows diffuse growth pattern, D- Tumor cells have positive staining with neuroendocrine marker CD56.

case that metastasis of SCC in the literature diagnosed in “lifetimes”.

The reasons for the low rate of metastasis to testis has not been clarified. In Smallman’s and Odedra’s review, it was reported that the reason was low temperature of the scrotum.<sup>9</sup> Because of the low temperature, the conditions were unsuitable for the metastasis of metastatic tumor cells to testis.<sup>9</sup> Several routes of mechanism to testicular involvement have been described; direct invasion from the lesion, arterial or venous embolization, lymphatic extension from paraaortic lymph nodes and extension from the vas deferens.<sup>3</sup> Route of metastasis from lung cancer to testis has been regarded hematogenously.<sup>3</sup>

Determining of the type of intratesticular mass is very difficult with physical examination and radiological imaging. The most common age of primary testicular tumor is between the ages of 20-40. Over the age of 50, the rate of primary testicular tumor decreases and the rate of testicular lymphoma and metastasis to testis increases. In our case, the patient is 62 years old with lung cancer and chemotherapy-radiotherapy history. After the chemotherapy and radiotherapy had been completed, testicular metastasis was detected. In a study reviewing cases with testicular metastasis after chemotherapy, these cases were found to have acute lymphoblastic leukemia, small-cell carcinoma and Merkel cell carcinoma.<sup>2</sup> In these cases, the primary tumor was regressed after treat-

ment but the testicular metastatic tumor progressed.<sup>2</sup> It is considered that the testicular-blood barrier has a protective effect from chemotherapy.<sup>3</sup>

In conclusion, metastasis to testis is very rare but it should be considered that the patients who are older than 50 years of age with a history of malignancy present with the testicular tumor may have metastasis.

### Source of Finance

*During this study, no financial or spiritual support was received neither from any pharmaceutical company that has a direct connection with the research subject, nor from a company that provides or produces medical instruments and materials which may negatively affect the evaluation process of this study.*

### Conflict of Interest

*No conflicts of interest between the authors and / or family members of the scientific and medical committee members or members of the potential conflicts of interest, counseling, expertise, working conditions, share holding and similar situations in any firm.*

### Authorship Contributions

**Idea/Concept:** Erdoğan Dinçer, Osman Murat İpek; **Design:** Burcu Hancı; **Control/Supervision:** Oktay Akça; **Data Collection and/or Processing:** Şükran Kayıpmaz, Erdoğan Dinçer, Burcu Hancı; **Analysis and/or Interpretation:** Osman Murat İpek, Oktay Akça, Erdoğan Dinçer; **Literature Review:** Erdoğan Dinçer; **Writing the Article:** Erdoğan Dinçer, Osman Murat İpek; **Critical Review:** Oktay Akça.

## REFERENCES

1. Casciato DA. Manual of Clinical Oncology. 6<sup>th</sup> ed. Los Angeles: Wolters Kluwer/Lippincott Williams & Wilkins; 2009.
2. Buck DA, Byrd RH, Holmes CL, Pollock T. Testicular metastasis in a case of squamous cell carcinoma of the lung. *Case Rep Oncol.* 2015;8(1):133-7. [[Crossref](#)] [[PubMed](#)] [[PMC](#)]
3. Uchida K, Kurimura Y, Miyake M, Ando M, Tanaka T, Sasao T, et al. Testicular metastasis from squamous cell carcinoma of the lung. *Int J Urol.* 2003;10(6):350-2. [[Crossref](#)] [[PubMed](#)]
4. Kaplan MA, Kucukoner M, Inal A, Urakci Z, Firat U, Komek H, et al. Testicular Mass: An Initial Sign of Squamous Cell Carcinoma of the Lung. *World J Oncol.* 2012;3(6):291-3. [[PubMed](#)] [[PMC](#)]
5. Ozeki T, Fujiwara K, Shimonishi A, Nishimura J, Okawa S, Takada K et al. Bilateral Testicular Metastases from Lung Adenocarcinoma Showing an Objective Response to Nivolumab: A Case Report and Review of the Literature. *Intern Med* 2019;58(22):3277-82. [[Crossref](#)] [[PubMed](#)] [[PMC](#)]
6. García-González R, Pinto J, Val-Bernal JF. Testicular metastases from solid tumors: an autopsy study. *Ann Diagn Pathol.* 2000;4(2):59-64. [[Crossref](#)] [[PubMed](#)]
7. Suzuki K, Hatahuku H, Onari S, Hasegawa M, Hujioka T, Tamura G. Metastatic tumor of the spermatic cord arising from lung cancer: a case report. *The Nishinon Journal of Urology* 1996;58(2):133-5. [[Link](#)]
8. Rosser CJ, Gerrard E. Metastatic small cell carcinoma to the testis. *South Med J.* 2000;93(1):72-3. [[PubMed](#)]
9. Smallman LA, Odedra JK. Primary carcinoma of sigmoid colon metastasizing to epididymis. *Urology.* 1984;23(6):598-9. [[Crossref](#)] [[PubMed](#)]