

# Saint's Traid (A. Case report)

Zafer FERAHKOŞE  
Ersin ÖZDEMİR  
Bülent AYTAÇ  
Atilla ENGİN

Gazi Üniversitesi Tıp Fakültesi  
Genel Cerrahi Anabilim Dalı, Ankara

Geliş Tarihi: 3 Haziran 1984

## SUMMARY

*A 65 year-old male who presented with complete clinical and laboratory manifestations of Saint's triad is reported whose diagnosis was established prior to surgical intervention. Awareness as to the existence of this rare condition has practical clinical value.*

**Key Words:** Choletiazis, colon diverticules, hiatal hernia

T J Research Med Sel V.3, N.4, 361-363, 1985

*65 yaşında bir erkek hasta Saint'y triadının klinik ve laboratuvar belirtileri ile müracaat etti. Teşhis cerrahi girişimden önce kondu. Hastalığın vasıfları ve özellikleri gözönünde bulundurulursa, teşhisin konarak ve tedavide faydalı olunabileceği kanaatına varıldı.*

**Anahtar Kelimeler:** Kolelitiazis, kolon divertikülü, hiyatal herni

T Kİ Tıp Bil Araştırma Der C.3, S.4. 361-363,1985

Hiatus hernia, diverticula of colon and gallstone diseases linked in Saint's triad have similar epidemiological features (1). The three diseases have their maximal prevalence in economically developed countries and their prevalence is lowest in rural communities in developing countries (10). Without special search Saint's triad was recognized in 3.4% of 713 patients (2). Evidences in the literature suggested that the triad's lesions develop separately over a relatively long period of time (2-5). However in our case, all three elements participated in the symptomatic picture coincidentally and the diagnosis was established prior to surgical intervention.

## CASE REPORT

65 year-old male patient was admitted to the surgical clinics of Gazi University Hospital on 18 March 1983. With a one-year history of upper abdominal and retrosternal pain and burning sensation. There was jaundice in his past history to suggest obstructive biliary tract disease. On physical examination he was a well-developed man. His blood pressure was 130/60 mm Hg, pulse 96 per minute, respiration 22. His abdomen was soft but tender in the right upper quadrant and epigastrium. The remainder of his examination was within normal limits. Roent-

genologic studies revealed hiatal hernia, gallstones and diverticular disease of the colon (Fig. 1, Fig. 2).

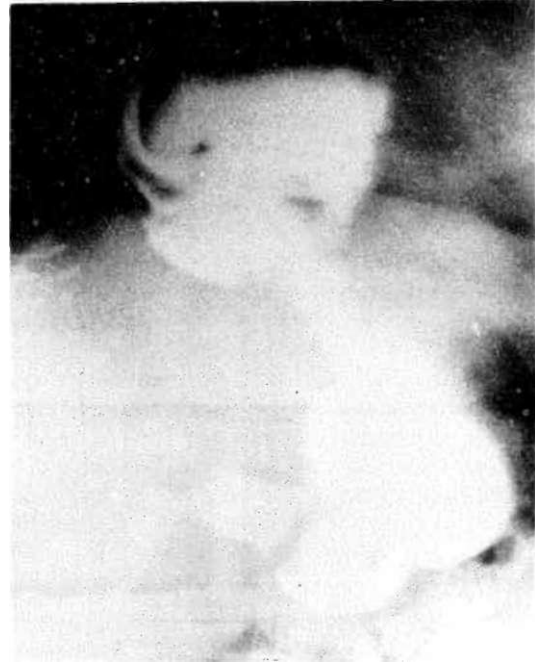

Figure-1.

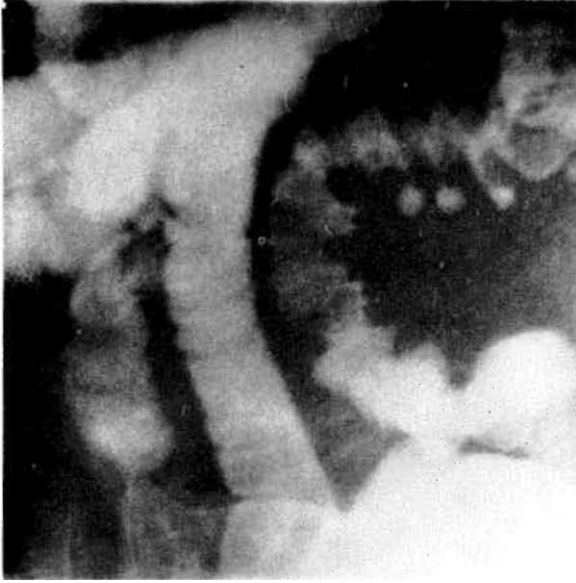


Figure-2.

He was taken to the operating room with the diagnosis of Saints triad. Exploration was initially performed on extrahepatic biliary system, A Cholecystectomy and external lateral choledochoduodenostomy were performed because of cholelithiasis and choledocholithiasis respectively (Fig. 3). The proximal portion of the stomach was in the thoracic cavity. The hernia content was reduced to the abdomen. A Nissen's fundoplication was performed successfully (Fig. 3). The patient's postoperative course was uneventful and he was discharged on the eighth postoperative day.

#### COMMI: NT

The clinician must be aware of the association of hiatal hernia, gallstones and diverticular disease of the colon. With gastroenterological problems there often seems to be little relationship between the patients' complaints and the organic lesions that are found (3). The classical symptoms of one of the lesions may indeed, be present but they are likely to be obscured by disturbances from the others. Because the patients' illness may be due to one or two of any combination of the three lesions, surgical correction of one or two lesions may not contribute drastically patient's (3). Some authors emphasized that the most striking complaint is referable to gallstones disease. But the symptomatic results of cholecystectomy are in general disappointing.

In considering reports on the triad's incidence, it is important to keep in mind that the hiatal hernia,

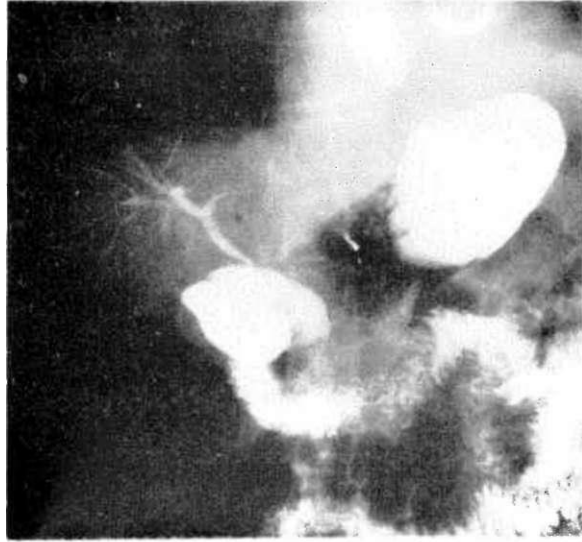


Figure-3.



Hgure-4.

gallstones and diverticular disease of the colon do not appear at the same time (2, 5).

However, when a patient has a history of cholelithiasis or demonstrable hiatus hernia, particularly if he is over 60 years of age, the probability of other triad elements being present is greatly increased (2).

## REFERENCE

1. Burkitt DP, ARP Walker: Saint's triad: Confirmation and explanation. S. Afr. M. cd. J.50:2136-2138, 1976.
2. Poster JJ, DI. Knulson: Association of cholelithiasis, hiatus hernia and diverticulosis coli, .[.A.M.A. 168: 257-261, 1958.
3. Palmer KD, MC Colonel: Further experiences with Saint's triad, Amer. J. Med. Seien. 244:108-112, 1962,
4. Capron JP, H Payenneville, M Dumont, JL Dupas, A Lorriaux: Kvidence for an association between cholelithiasis and hiatus hernia, Lancet 2:329-331, 1978.
5. Capron JP, R Piperaud, JL Dupas, J Delamarre, A Lorriaux: Evidence for an association between cholelithiasis and diverticular disease of the colon, Diges. Disease Scien. 26:523-526, 1981.