

Efficacy of Arcuate Keratotomy Incisions in Correction of High Post-Keratoplasty Astigmatism

Yüksek Post-Keratoplasti Astigmatizmanın Düzeltmesinde Arkuat Keratotomi İnsizyonlarının Etkinliği

Bora YÜKSEL,^a
Ömer KARTI,^a
Tekin AYDIN,^a
Tuncay KÜSBECİ^a

^aClinic of Ophthalmology,
Bozyaka Training and Research Hospital,
İzmir

Received: 17.07.2017
Received in revised form: 31.10.2017
Accepted: 06.11.2017
Available online: 10.08.2018

Correspondence:
Ömer KARTI
Bozyaka Training and Research Hospital,
Clinic of Ophthalmology, İzmir,
TURKEY/TÜRKİYE
kartiomer@gmail.com

This work was also presented as poster at the
7th World Congress on Ophthalmology Dispute
(COPHy), March 31 - April 2, 2016, Warsaw,
Poland.

ABSTRACT Objective: To evaluate the efficacy of paired arcuate keratotomy (AK) incisions to correct high astigmatism after penetrating keratoplasty. **Material and Methods:** 28 eyes of 27 patients operated between October 2011 and January 2015 were included. Paired arcuate incisions (at an 80-90% depth, and arc lengths of 60 to 90 degrees) were performed with a diamond knife. Incisions were placed within the corneal graft. Results were analyzed at the third month postoperatively. **Results:** The mean age of the patients was 49.1 years. 12 of 27 patients were male and 15 were female. Primary indication for penetrating keratoplasty was keratoconus in 16 eyes, stromal dystrophy or leucoma in 8 eyes and bullous keratopathy in 4 eyes. After arcuate keratotomy, mean best corrected visual acuity with log MAR improved from 0.72 ± 0.43 to 0.46 ± 0.29 and un-corrected visual acuity from 1.19 ± 0.36 to 1.01 ± 0.46 . Mean topographic astigmatism decreased from 7.4 ± 3.2 D to 4.8 ± 2.7 D. K min increased from 40.9 ± 3.9 D to 44.4 ± 3.6 D. K max decreased from 48.7 ± 3.3 D to 48.3 ± 3.9 D. Mean spherical equivalent increased from -2.6 ± 1.9 D to -3.1 ± 2.5 D. **Conclusion:** AK incisions provide fast reduction in post-keratoplasty astigmatism and improvement in visual acuity. The magnitude of the reduction of astigmatism was highly correlated with preoperative astigmatism. However, to achieve successful results, proper patient selection is necessary.

Keywords: Astigmatism; keratoplasty, penetrating

ÖZET Amaç: Penetran keratoplastiden sonra arkuat keratotomi (AK) insizyonlarının yüksek astigmatizmayı düzeltme etkinliğini değerlendirmek. **Gereç ve Yöntemler:** Ekim 2011 ile Ocak 2015 tarihleri arasında opere edilen 27 hastanın 28 gözü dahil edildi. Arkuat insizyonlar (%80-90 derinlikte ve 60 ile 90 derece arasında ark uzunluklarında) bir elmas bıçak ile gerçekleştirildi. İnsizyonlar kornea grefti içine yerleştirildi. Sonuçlar operasyon sonrası 3.ayda incelendi. **Bulgular:** Hastaların ortalama yaşı 49.1 yıl idi. 27 hastanın 12'si erkek, 15'i kadın idi. Penetran keratoplasti için primer endikasyon 16 gözde keratokonus, 8 gözde stromal distrofi veya lökom ve 4 gözde büllöz keratopati idi. Arkuat keratotomiden sonra, Log MAR ile ortalama düzeltilmiş en iyi görme keskinliği 0.72 ± 0.43 'den 0.46 ± 0.29 'a ve düzeltilmemiş görme keskinliği 1.19 ± 0.36 'dan, 1.01 ± 0.46 'ya yükseldi. Ortalama topografik astigmatizma 7.4 ± 3.2 D'den 4.8 ± 2.7 D'ye düştü. K min, 40.9 ± 3.9 D'den 44.4 ± 3.6 D'ye arttı. K max, 48.7 ± 3.3 D'den 48.3 ± 3.9 D'ye düştü. Ortalama sferik eşdeğer -2.6 ± 1.9 D'den -3.1 ± 2.5 D'ye yükseldi. **Sonuç:** AK insizyonları post-keratoplasti astigmatizmasında hızlı azalma ve görme keskinliğinde iyileşme sağlamaktadır. Astigmatizma azalmasının büyüklüğü ameliyat öncesi astigmatizma ile yüksek korelasyona sahiptir. Bununla beraber, başarılı sonuçlar elde etmek için, uygun hasta seçimi gereklidir.

Anahtar Kelimeler: Astigmatizm; keratoplasti, penetran

Astigmatism is the most common cause of impaired vision after penetrating keratoplasty (PK) despite a clear corneal graft.¹ Postoperative astigmatism higher than 5 diopters (D) has been reported in 15-38% of patients undergoing PK.^{1,2} Various approaches have been used to deal with this problem including manual, mechanized or femtosecond laser

arcuate keratotomy (FLAK), compression sutures, laser in situ keratomileusis, wedge resection, toric phakic intraocular lenses, and finally regranting.³⁻⁹ Manual arcuate keratotomy (AK) has been the most widely used procedure for the treatment of astigmatism greater than 4-6 D.¹⁻³ The main principle of AK is based on flattening the steep corneal meridian by placing one or two incisions perpendicular to the steep axis. This flattens the given meridian with reciprocal steepening of the meridian 90° away, known as “coupling effect”. The efficacy of astigmatic incisions is dependent on the length and depth of incisions.² A wide range of corrections between 3.2 D and 9.7 D has been reported with this approach.^{1,3} This study was conducted to evaluate the efficacy of paired AK incisions for correction of high astigmatism after PK.

MATERIAL AND METHODS

In this single center, retrospective interventional case series, performed at the Department of Ophthalmology, Bozyaka Training and Research Hospital, Turkey, between October 2011 and January 2015. The study adhered to the tenets of the Declaration of Helsinki, and informed consent was obtained from all participants. An informed consent was obtained from all the patients to perform the original measurements and to review their medical records.

SUBJECTS

28 eyes of 27 patients included and demographic features of the individuals were recorded. In addition, all the patients underwent a detailed ophthalmic examination, including auto keratometry (Topcon RK 8000PA, auto-refractometer, Topcon, Tokyo, Japan), uncorrected visual acuity testing (UCVA), best corrected visual acuity testing (BCVA), slit-lamp biomicroscopy, intraocular pressure (IOP) measurement and dilated fundus examination. IOP was measured using a slit lamp-mounted Goldmann applanation tonometry (GAT) with the prisms in the vertical and horizontal meridian. Averaging vertical and horizontal GAT readings were performed to improve the accuracy of IOP measurement in patients with regu-

lar corneal astigmatism and the mean values were recorded. Spherical equivalent (SE) was calculated according to auto-refractometry results as follows: spherical value (diopter) + 1/2 cylindrical value (diopter). The efficacy index was calculated as the ratio of the mean postoperative UCVA to the mean preoperative BCVA. In addition, corneal topographies were acquired with Keratograph III (Oculus, Wetzlar, Germany). Flat keratometry (K min), steep keratometry (K max) and topographic astigmatism was noted. Corneal thickness was measured with PacScan 300 (Sonomed Inc., NY, USA) preoperatively and postoperatively.

INCLUSION AND EXCLUSION CRITERIA FOR STUDY GROUP

Inclusion criteria were post-keratoplasty astigmatism higher than 3.0 D, complete removal of sutures at least 6 months before AK, and a stable refractive error. Eyes with regular or moderately skewed topographic bowtie astigmatism were included, but irregular topographic patterns of astigmatism were excluded.

SURGICAL TECHNIQUE

Paired AK incisions at an 80-90% depth, and arc lengths of 60 to 90 degrees were performed with a diamond knife (Geuder AG, Heidelberg, Germany). Paired AK incisions were placed within the corneal graft and parallel to the graft-host junction. Incisions were made on the steep axis on topography. Under topical anesthesia, microscope light was set to minimum, planned AK tracts were marked with a surgical pen, and manual AK incisions were made (Figure 1). Incisions were opened and irrigated with a 27 G cannula. In cases of skewed astigmatism, skewed incisions corresponding to the steep astigmatic meridians on topography were used. Asymmetric arc lengths were used to correct asymmetric bowtie astigmatism. The effect of the incisions was monitored intraoperatively with a hand-held keratoscope. All surgical procedure was performed by one surgeon (B.Y). Topical antibiotic and artificial tears were given 4 times daily. Patients were followed up and examined at first day, first week, first month, 3 months after the procedure.

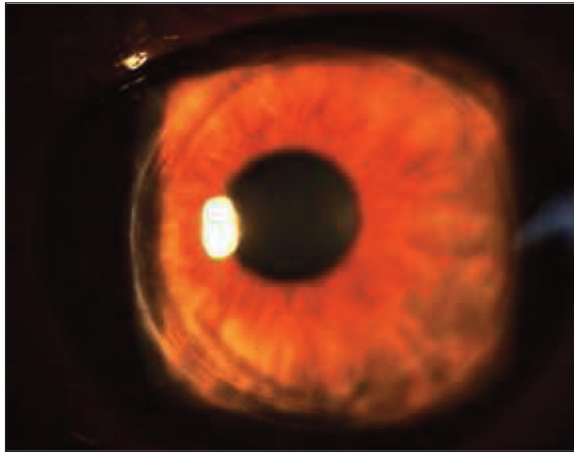


FIGURE 1: Left eye of a 45-year-old female with PK for keratoconus. Trephine sizes were 8.0 x 8.25 mm. Paired arcuat incisions, placed at 8 and 2 clock axes, at arc length of 60 degrees are visible.

STATISTICAL ANALYSES

Statistical analyses were performed with SPSS 18.0 software. For each continuous variable, normality was determined by Kolmogorov–Smirnov test. The Kolmogorov–Smirnov test showed a normal distribution for K min, K max, UCVA, BCVA, SE and topographic astigmatism parameters. Paired t test was used for comparison of preoperative and postoperative values. Pearson correlation analysis was used to determine the relationship between the magnitude of reduction in astigmatism and preoperative parameters. A p value <0.05 was considered statistically significant.

RESULTS

Mean age was 49.1 ± 17.9 years (range, 26–75 years). Twelve were male and 15 female. Primary indication was keratoconus in 16 eyes, stromal dystrophy or leucoma in 8 and bullous keratopathy in 4 eyes. Mean preoperative central corneal thickness was $559.2 \pm 48.9 \mu$ (range, 485–700 μ). Mean knife depth was $488.4 \pm 58.1 \mu$ (range, 430–595 μ) which corresponds to 87.3% of corneal thickness. Mean preoperative UCVA and BCVA were 0.72 ± 0.43 D and 1.19 ± 0.36 D, respectively. Mean postoperative UCVA and BCVA were 0.46 ± 0.29 D and 1.01 ± 0.46 D, respectively. A statistically significant improvement was achieved in both mean BCVA ($p < 0.001$) and UCVA ($p = 0.009$) at postoperative 3 months. Mean preoperative and postopera-

tive topographic astigmatism were 7.4 ± 3.2 D and 4.8 ± 2.7 D, respectively. Mean reduction in astigmatism was 2.6 D. This reduction was statistically significant ($p < 0.001$). Efficacy index was 0.71 at 3 months. Postoperative change in magnitude of astigmatism was significantly correlated with preoperative astigmatic value on topography ($R = 0.659$, $p = 0.000$, Pearson correlation analysis). A 3.5 D steepening was achieved in flat axis which was statistically significant ($p = 0.001$). A 0.5 D flattening was achieved in mean steep axis, however, this was not statistically significant ($p = 0.506$). A 0.5 D myopic shift occurred postoperatively. This change in refraction was not statistically significant ($p = 0.415$) (Table 1). A reduction of 2.0 D or more in topographic astigmatism was achieved in 17 of 28 eyes (60.7%). Table 2 shows postoperative changes in refractive and topographic astigmatism as well as visual acuity.

Refractive astigmatic cylinder could not be measured in 8 eyes preoperatively. So that, comparison of preoperative and postoperative values could not be made in these eyes (Table 2, bottom row). After surgery, manifest refraction has become measurable in 6 of these eyes. An improvement ≥ 2 Snellen lines in BCVA was achieved in 13 (46.4%) of 28 eyes.

Mean reduction was 2.5 D in 7.0 mm (4 eyes), 2.7 D in 7.5 (16 eyes) and 2.6 D in 8.0 mm (8 eyes) recipient trephine size. No correlation was found between the magnitude of reduction in astigmatism and trephine size ($p = 0.995$, ANOVA test). Association between the symmetry of the bowtie pattern on topography and reduction in astigmatism was also investigated. Topographic pattern of astigmatism was symmetric bow-tie in 8 (28.6%) and asymmetric bow-tie in 20 eyes (71.4%). Mean reduction in astigmatism was 3.1 D in eyes with symmetric bowtie pattern and 2.4 D in asymmetric bowtie pattern. However, that difference was not statistically significant ($p = 0.630$, ANOVA).

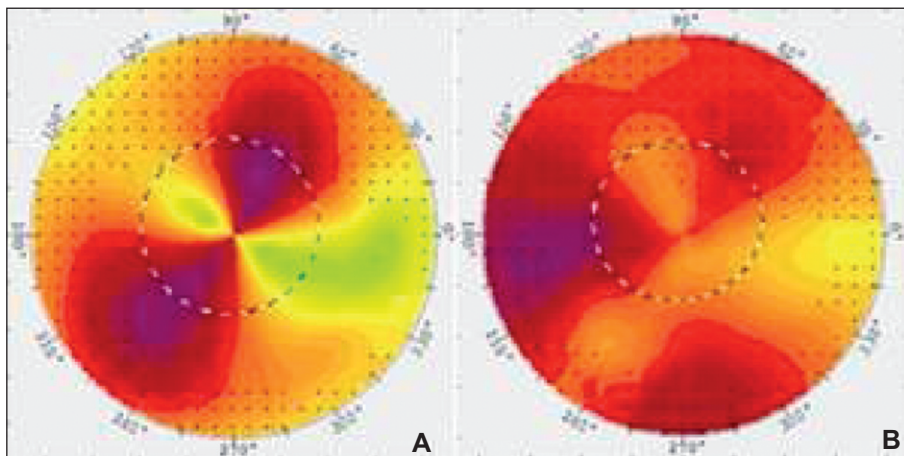
Skewing of the axes on corneal topography occurred in 4 eyes (14.3%) postoperatively. Macroperforation requiring suturing occurred in 1 eye (3.6%). Preoperative central corneal thickness was 589 μ and knife depth was 450 μ in that eye.

TABLE 1: Postoperative changes in visual, refractive and topographic parameters.

	Preoperative Mean \pm SD (min-max)	Postoperative Mean \pm SD (min-max)	p value ¹
BCVA (logMAR)	0.72 \pm 0.43 (range, 0.00-1.60)	0.46 \pm 0.29 (range, 0.00-1.00)	<0.001
UCVA (logMAR)	1.19 \pm 0.36 (range, 0.54-2.00)	1.01 \pm 0.46 (range, 0.18-2.00)	0.009
Topographic Astigmatism (D)	7.4 \pm 3.2 (range, 3.40 – 15.0)	4.8 \pm 2.7 (range, 0.9 – 9.3)	<0.001
Kmin (D)	40.9 \pm 3.9 (range, 32.0-48.0)	44.4 \pm 3.6 (range, 37.6-51.7)	0.001
Kmax (D)	48.7 \pm 3.3 (range, 41.2-56.6)	48.3 \pm 3.9 (range, 42.2-59.3)	0.506
SE (D)	-2.6 \pm 1.9 (range, -6.5 – 1.5)	-3.1 \pm 2.5 (range, -8.0 – 1.0)	0.415

¹Paired t testValues are mean \pm standard deviation**Abbreviations;** SD: Standard deviation, **BCVA:** Best corrected visual acuity, **UCVA:** Uncorrected corrected visual acuity, **Kmin:** Minimum keratometry, **Kmax:** Maximum keratometry, **SE:**Spherical equivalent.**TABLE 2:** Postoperative changes in refractive astigmatism, topographic astigmatism, corrected and uncorrected visual acuity (n=28).

Change	Refractive Astigmatism eyes (%)	Topographic Astigmatism eyes (%)	BCVA eyes (%)	UCVA eyes (%)
Decrease	16 (57.1)	22 (78.5)	2 (7.1)	2 (7.1)
Increase	3 (10.7)	5 (17.9)	21 (75.0)	18 (64.3)
No change	1 (3.6)	1 (3.6)	5 (17.9)	8 (28.6)
Unavailable	8 (28.6)	-	-	-

Abbreviations; **BCVA:** Best corrected visual acuity, **UCVA:** Uncorrected corrected visual acuity.**FIGURE 2:** **A.** Preoperative topography of the patient shown at Figure 1. K: 48.5 x 40.8 D. Topographic astigmatism: 7.6 D. UCVA: 1.0 (log MAR) and BCVA: 0.2 (log MAR) (+2.75, -7.50 x 160°). Pattern: Prolate symmetric bowtie. **B.** Postoperative topography: K: 45.5 x 44.1 D. Astigmatism decreased to 1.3 D. UCVA: 0.2 (log MAR), BCVA: 0 (log MAR) (-1.50 x 10°).

Another patient experienced postoperative visual distortion because one of the incisions entered into the pupillary zone due to patient's eye movement during keratotomy. Re-grafting was performed on this patient later on. An example of pre- and postoperative topography of a patient is shown in Figure 2.

DISCUSSION

In current study, a statistically significant reduction in astigmatism and improvement in both UCVA and BCVA in more than 60% of the patients were achieved at 3 months. Similar improvement in BCVA and UCVA³ has been reported in previous studies.^{3,10} A mean 2.6 D (35.1%) reduction in astigmatism was achieved using paired AK. Hoffart et al. reported 30% reduction in astigmatism with mechanized AK which is lower than our result.¹¹ Poole et al. and Kubaloğlu et al. and Wilkins et al. reported 4.28 D (46.9%), 3.18 D and 7.66 D reduction in astigmatism, respectively.^{3,10,12} Greater reductions up to 70% of astigmatism have been reported with incisions at 600 µm depth. However, it is associated with a high-risk of perforation.² Geggel achieved at least 50% reduction in astigmatism in 81% of the eyes.¹³ Relatively low efficacy achieved in our study may be due to the low ratio of patients (29%) with symmetric bowtie astigmatism compare to that study (58%).¹³

Low predictability associated with AK for post-PK astigmatism has been reported in several studies.^{1,14,15} This is likely due to the variability of the wound healing and variable tension present within the graft.² The sharpness and type of the diamond knife, velocity in performing the incisions and intraocular pressure are contributing factors in depth and regularity of the incisions.¹⁶ In parallel with previous reports, the magnitude of the reduction was found highly correlated with preoperative astigmatism in current study.^{12,17} Standardized nomograms developed for congenital astigmatism cannot be applied to the correction of post-PK astigmatism.^{1,12} Although, a myopic shift up to 1.5 D may be seen after AK¹, other studies reported no change in mean spherical equivalent.^{2,10,12} Postoperative myopic shift (0.53D) observed in our study

wasn't statistically significant either. Efficacy index was 0.71 at 3 months.

One macro-perforation and 1 off-center incision occurred in our study. Reported complications of AK include under-correction, overcorrection, corneal perforation, wound dehiscence, irregular astigmatism, recurrence and prolonged instability of corneal topography.^{1,2} To increase safety and efficacy, FLAK has been recently introduced in clinical practice. However, in a series of 62 eyes, Fadlallah et al. reported 2 micro-perforation, 3 infectious keratitis, 3 graft rejection episodes, 1 endophthalmitis and 12 overcorrection. Efficacy index was reported as 0.81 at 6 months.⁵ Kook et al. reported 2.8 D (30%) regression in topographic astigmatism with FLAK. Hoffart et al. compared mechanized AK with FLAK and reported 30% and 55% regression respectively, without any visual gain.^{11,18} Misalignment during mechanized AK was reported as a contributing factor to the low efficacy. They also reported micro-perforation and 1 case with off-center incision after mechanized AK.

Bayramlar et al. reported a frequent need for repeat or combined procedures in AK such as lengthening of the incisions for under-correction or compression sutures for overcorrection.¹⁴ Fares et al. combined AK with compression sutures.⁶ They achieved 4.37 D decrease in eyes with a preoperative astigmatism between 6-9 D and 6.23 D decrease in eyes with a preoperative astigmatism between 9-16.5 D. They found AK safe and effective and suggested an arc length of 60° for astigmatism of 6-9 D, and 75° for astigmatism >9 D. Sy et al. combined AK with conductive keratoplasty for astigmatism >5 D and achieved a regression of 5.5 D.¹⁹

Böhringer et al. in their study have reported that AK is an effective tool to reduce post-keratoplasty astigmatism with better results in regular corneal astigmatism but limited predictability of refractive results.²⁰ They have suggested that AK may still be an elegant option to reduce postoperative astigmatism after PK. FLAK surgery which is able to create quality arcuate incisions with precise length, depth, radius, and symmetry that were pre-

viously hard to achieve by manual techniques is commonly used to correct post-keratoplasty astigmatism. Although the FLAK surgery may be widespread, some clinics do not still have this technology. Therefore, manual AK may be a good alternative procedure. If the laser technology can not be available.

Although, the conclusions that can be drawn from this study are limited by relatively small number of patients and short follow-up, the reduction in astigmatism achieved in this study is comparable with previous post-PK AK results. Our results suggest that AK allows a fast reduction in astigmatism and an improvement in vision with few complications. Despite its low predictability, manual AK remains a viable procedure for treating post-PK astigmatism with satisfactory safety and efficacy.^{2,3,6,10,13,14} Selection of patients with symmetric bowtie astigmatism and proper alignment during surgery are key factors to achieve intended correction.

Source of Finance

During this study, no financial or spiritual support was received neither from any pharmaceutical company that has a direct connection with the research subject, nor from a company that provides or produces medical instruments and materials which may negatively affect the evaluation process of this study.

Conflict of Interest

No conflicts of interest between the authors and / or family members of the scientific and medical committee members or members of the potential conflicts of interest, counseling, expertise, working conditions, share holding and similar situations in any firm.

Authorship Contributions

Idea/Concept: Bora Yüksel; **Design:** Bora Yüksel, Tuncay Küsbeci; **Control/Supervision:** Bora Yüksel, Tuncay Küsbeci, Ömer Kartı; **Data Collection and/or Processing:** Ömer Kartı, Tekin Aydın; **Analysis and/or Interpretation:** Ömer Kartı, Bora Yüksel, Tuncay Küsbeci, Tekin Aydın; **Literature Review:** Ömer Kartı, Tekin Aydın, Bora Yüksel, Tuncay Küsbeci; **Writing the Article:** Bora Yüksel, Tuncay Küsbeci, Ömer Kartı; **Critical Review:** Bora Yüksel, Tuncay Küsbeci.

REFERENCES

1. Feizi S, Zare M. Current approaches for management of postpenetrating keratoplasty astigmatism. *J Ophthalmol* 2011;2011:708736.
2. Cleary C, Tang M, Ahmed H, Fox M, Huang D. Beveled femtosecond laser astigmatic keratotomy for the treatment of high astigmatism post-penetrating keratoplasty. *Cornea* 2013; 32(1):54-62.
3. Kubaloglu A, Coskun E, Sari ES, Guneş AS, Cinar Y, Piñero DP, et al. Comparison of astigmatic keratotomy results in deep anterior lamellar keratoplasty and penetrating keratoplasty in keratoconus. *Am J Ophthalmol* 2011;151(4):637-43.e1.
4. Hoffart L, Touzeau O, Borderie V, Laroche L. Mechanized astigmatic arcuate keratotomy with the Hanna arcitome for astigmatism after keratoplasty. *J Cataract Refract Surg* 2007; 33(5):862-8.
5. Fadlallah A, Mehanna C, Saragoussi JJ, Chelala E, Amari B, Legeais JM. Safety and efficacy of femtosecond laser-assisted arcuate keratotomy to treat irregular astigmatism after penetrating keratoplasty. *J Cataract Refract Surg* 2015;41(6): 1168-75.
6. Fares U, Mokashi AA, Al-Aqaba MA, Otri AM, Miri A, Dua HS. Management of postkeratoplasty astigmatism by paired arcuate incisions with compression sutures. *Br J Ophthalmol* 2013;97(4): 438-43.
7. Bahar I, Kaiserman I, Mashor RS, McAllum P, Slomovic A, Rootman D. Femtosecond LASIK combined with astigmatic keratotomy for the correction of refractive errors after penetrating keratoplasty. *Ophthalmic Surg Lasers Imaging* 2010;41(2):242-9.
8. Akcay L, Kaplan AT, Kandemir B, Gunaydin NT, Dogan OK. Toric intraocular Collamer lens for high myopic astigmatism after penetrating keratoplasty. *J Cataract Refract Surg* 2009;35(12): 2161-3.
9. Szentmáry N, Seitz B, Langenbucher A, Naumann GO. Repeat keratoplasty for correction of high or irregular postkeratoplasty astigmatism in clear corneal grafts. *Am J Ophthalmol* 2005; 139(5):826-30.
10. Poole TR, Ficker LA. Astigmatic keratotomy for post-keratoplasty astigmatism. *J Cataract Refract Surg* 2006;32(7):1175-9.
11. Hoffart L, Proust H, Matonti F, Conrath J, Ridings B. Correction of postkeratoplasty astigmatism by femtosecond laser compared with mechanized astigmatic keratotomy. *Am J Ophthalmol* 2009;147(5):779-87.
12. Wilkins MR, Mehta JS, Larkin DF. Standardized arcuate keratotomy for postkeratoplasty astigmatism. *J Cataract Refract Surg* 2005; 31(2):297-301.
13. Geggel HS. Arcuate relaxing incisions guided by corneal topography for postkeratoplasty astigmatism: vector and topographic analysis. *Cornea* 2006;25(5):545-57.
14. Bayramlar H, Karadag R, Cakici O, Ozsoy I. Arcuate keratotomy on post-keratoplasty astigmatism is unpredictable and frequently needs repeat procedures to increase its success rate. *Br J Ophthalmol* 2016;100(6):757-61.
15. Lee GA, Pérez-Santonja JJ, Maloof A, Ficker LA, Dart JK. Effects of lamellar keratotomy on postkeratoplasty astigmatism. *Br J Ophthalmol* 2003;87(4):432-5.
16. Merlin U, Bordin P, Rimondi AP, Sichirollo R. Factors that affect keratotomy depth. *Refract Corneal Surg* 1991;7(5):356-9.

17. Price FW, Grene RB, Marks RG, Gonzales JS. Astigmatism reduction clinical trial: a multicenter prospective evaluation of the predictability of arcuate keratotomy. Evaluation of surgical nomogram predictability. ARC-T Study Group. Arch Ophthalmol 1995;113(3): 277-82.
18. Kook D, Bühren J, Klaproth OK, Bauch AS, Derhartunian V, Kohnen T. [Astigmatic keratotomy with the femtosecond laser: correction of high astigmatism after keratoplasty]. Ophthalmologie 2011;108(2):143-50.
19. Sy ME, Kovoov TA, Tannan A, Choi D, Deng SX, Danesh J, et al. Combined astigmatic keratotomy and conductive keratoplasty to correct high corneal astigmatism. J Cataract Refract Surg 2015;41(5):1050-6.
20. Böhringer D, Dineva N, Maier P, Birnbaum F, Kirschkamp T, Reinhard T, et al. Long-term follow-up of astigmatic keratotomy for corneal astigmatism after penetrating keratoplasty. Acta Ophthalmol 2016;94(7): e607-e11.