

# Ligneous Conjunctivitis: Clinical and Histopathological Features and Response to Treatment: Case Report

## Lignöz Konjonktivit: Klinik ve Histopatolojik Özellikleri ve Tedaviye Yanıt

Tülay ALPAR AKÇETİN,<sup>a</sup>  
Kübra SARICI,<sup>a</sup>  
Kadir ELTUTAR,<sup>a</sup>  
Esra PAŞAOĞLU,<sup>b</sup>  
Erol Rüştü BOZKURT,<sup>b</sup>  
T. Tiraje CELKAN<sup>c</sup>

Clinics of

<sup>a</sup>Ophthalmology,

<sup>b</sup>Pathology,

İstanbul Training and Research Hospital,

<sup>c</sup>Department of Pediatrics,

İstanbul University

Cerrahpaşa Faculty of Medicine,

İstanbul

Geliş Tarihi/Received: 27.03.2012

Kabul Tarihi/Accepted: 20.11.2012

Yazışma Adresi/Correspondence:

Kübra SARICI

İstanbul Training and Research Hospital,

Clinic of Ophthalmology, İstanbul,

TÜRKİYE/TURKEY

kubrakesekler@hotmail.com

**ABSTRACT** Discussion of ligneous conjunctivitis, a rare form of conjunctivitis that appears in the form of pseudomembranous lesions in the upper tarsal conjunctiva, in terms of its clinical and histopathologic features and its response to treatment. Membrane excision was performed on a 4-year-old male patient who had developed membranous conjunctivitis showing multiple recurrences following a varicella infection. A conjunctival culture was taken. Blood plasminogen level was checked. The diagnosis of ligneous conjunctivitis was made in the light of clinical, histopathologic and biochemical findings. The patient's blood plasminogen level was 16 mg/dl. The patient was given a single dose 15 mL/kg intravenous infusion from fresh-frozen plasma (FFP) with normal plasminogen level, as well as topical FFP. The membrane decreased in size with the treatment; however, it reappeared one month after the treatment was stopped. Therefore, single-dose systemic FFP (15ml/kg), topical FFP 4 times a day and topical cyclosporine 1% twice a day were readministered. The topical treatment was continued for eight months. The patient was followed up for two year. As a result of the systemically and topically-applied FFP treatment, the membrane disappeared and no relapse occurred. It was concluded that topically and systemically-applied FFP treatment rapidly resolves conjunctival membranes and prevents their recurrence.

**Key Words:** Conjunctivitis; plasminogen; plasma

**ÖZET** Üst tarsal konjonktivada tekrarlayan psödomembranöz lezyonlar şeklinde ortaya çıkan lignöz konjonktivitin klinik - histopatolojik özellikleri ve tedaviye verdiği yanıt açısından literatür bilgileri eşliğinde tartışılması amaçlandı. Suçiçeği enfeksiyonu tekrarlayıcı membranöz konjonktivit gelişen 4 yaşında erkek hastaya membran eksizyonu yapıldı. Konjonktival kültür alındı. Kan plazminojen seviyesine bakıldı. Klinik, histopatolojik ve biyokimyasal bulgularla lignöz konjonktivit olarak rapor edildi. Hastanın kan plazminojen seviyesi 16 mg/dl idi. Hastaya plazminojen seviyesi normal olan taze donmuş plazmadan (TDP) 15 ml/kg tek doz intravenöz infüzyon ve topikal TDP verildi. Tedavi sonrası membranın küçüldüğü gözlenirken, tedavi kesildikten 1 ay sonra membranın tekrar etmesi üzerine, 15 mL/kg tek doz sistemik intravenöz infüzyon TDP ve günde 4 kez topikal TDP ve günde %1'lik topikal siklosporin tedavisi yinelenildi. Topikal tedaviye 8 ay süre ile devam edildi. Hasta iki sene takip edildi. Sistemik ve topikal olarak verilen TDP tedavisi ile membran kayboldu ve nüks gelişmedi. Sonuç olarak topikal ve sistemik olarak uygulanan taze donmuş plazma tedavisi lignöz konjonktivitte konjonktival membranın hızla rezolüsyonunu sağlamaktave rekürrensini engellemektedir.

**Anahtar Kelimeler:** Konjonktivit; plazminojen; plazma

**Türkiye Klinikleri J Ophthalmol 2013;22(1):45-9**

The term "ligneous conjunctivitis" (LC) was first used by Borel in 1933 in order to define a rare form of chronic bilateral recurring conjunctivitis characterized by the development of "woody" and fibrin-rich pseudomembranous lesions, mainly in the upper tarsal conjunctiva and oc-

asionally in the lower palpebra and the bulbar conjunctiva. It develops in connection with type 1 plasminogen deficiency and can also appear as a systemic disease, affecting other mucous membranes than the conjunctiva.<sup>1,2</sup>

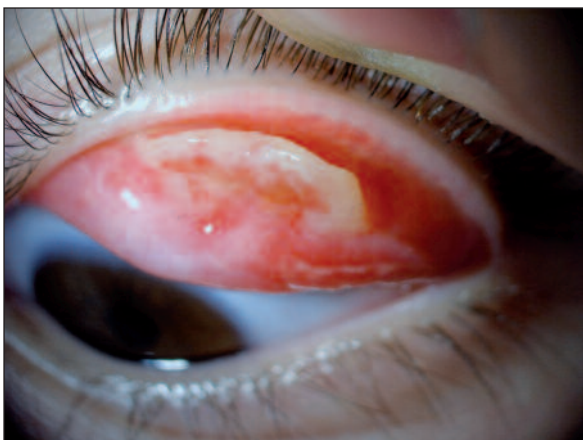Although the disease is defined as autosomal recessive, most cases are sporadic. Type 1 plasminogen deficiency is found to be related to homozygote or complex heterozygote mutations in the plasminogen gene.<sup>2,3</sup> These mutations cause rapid destruction of the plasminogen, the key component of the fibrinolytic system, thus preventing the dissolution of the temporary fibrin matrix formed during wound healing. These fibrin accumulations gather as small subepithelial masses and cause ulceration in the mucosa, resulting in a vicious cycle of tissue damage and fibrin accumulation.<sup>3,4</sup> Herein, we report a case of a 4-year-old male patient with ligneous conjunctivitis located in the upper tarsal conjunctiva who was treated successfully with systemically and topically applied fresh-frozen plasma (FFP).

## CASE REPORT

A 4-year-old male patient was brought to our clinic after a pinkish red membranous lesion appeared on his upper left palpebra following a varicella infection (Figure 1). It was learned that the patient had undergone membrane resection in the same eye in two different centers and was treated with topical

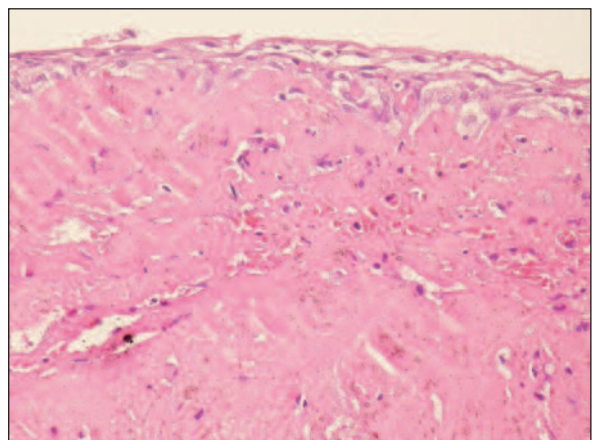
antibiotics and topical prednisolone acetate after the resection. The membrane reappeared within a short period after both resections.

In the external examination of the eyes, a mucopurulent discharge on the left side and a thickening of the upper eyelid were seen in the left eye. Biomicroscopic examination revealed a hypertrophic pseudomembrane in the upper left tarsal conjunctiva. The cornea and the lens were clear and the posterior segment examination was normal. A conjunctival culture was taken. The membrane was removed from tarsal conjunctiva by dissection under general anesthesia. The macroscopic examination of the specimen revealed a 0.6x0.3x0.3 cm bright pink lesion with a firm consistency and a smooth surface. In the histopathologic examination, a considerably thick acellular eosinophilic fibrinoid substance resembling patches of erosion was seen under the surface epithelium (Figure 2). In other areas, active chronic inflammation and focal hyalinization were seen. The histochemical test for amyloid revealed Congo red and Cresyl violet positivity (-). This accumulated material was considered to be fibrin. The free plasminogen level was found to be 16 mg/dL (normal value being 80-120 mg/dL). Based on the clinic, histopathologic and biochemical findings, the diagnosis of ligneous conjunctivitis was made. The plasminogen levels of the mother and father were 74 mg/dL and 76 mg/dL. This lower limit values suggested that mother and father may be carrier. No



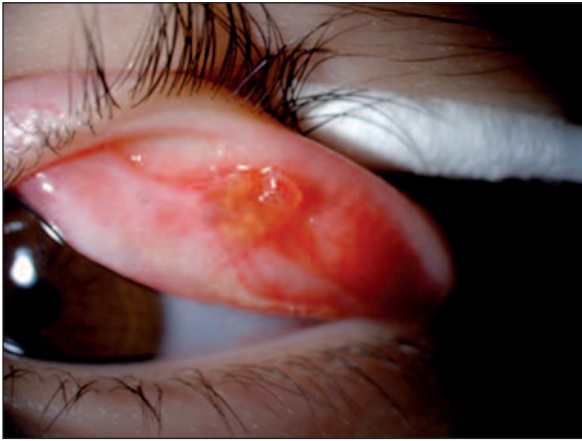**FIGURE 1:** Bright-pink colored membranous mass localized in the upper palpebral conjunctiva.

(See for colored form <http://oftalmoloji.turkiyeklinikleri.com/>)



**FIGURE 2:** Showing the bottom of epithelial accumulation, inflammatory cells, erythrocytes and amyloid-like fibrinoid material. (HEX200).

(See for colored form <http://oftalmoloji.turkiyeklinikleri.com/>)



**FIGURE 3:** The final appearance of the lesion which significant reduction with systemic and topical fresh frozen plasma treatment.

(See for colored form <http://oftalmoloji.turkiyeklinikleri.com/>)

similar lesions were seen in other mucous membranes and no other pathologies were found in the systemic examination. After the membrane resection, topical prednisolone acetate 1% 4 times a day and topical cyclosporine 0.05% twice a day were given to the patient. After one month, the lesion recurred and a single-dose intravenous infusion of FFP (15 ml/kg) was administered. In addition to that, topical FFP stored at  $-18^{\circ}\text{C}$  was drawn into 5 mL injectors and administered 5x/1 mL/day and topical cyclosporine 1% twice a day was administered for 4 weeks. The membrane decreased in size with the treatment; however, it reappeared one month after the treatment was stopped. Therefore, single-dose systemic FFP (15 ml/kg), topical FFP 4 times a day, and topical cyclosporine 1% twice a day were readministered. The topical treatment was continued for eight months. The patient was followed up for two year, in the course of which the membrane completely disappeared and no new membrane formation was observed (Figure 3).

## DISCUSSION

Ligneous conjunctivitis is a rarely seen form of idiopathic membranous conjunctivitis. It was first defined by Biusson in 1847, and the term "ligneous conjunctivitis" was first used by Borel in 1933.<sup>1</sup> Due to the fact that similar lesions can form in other mucous membranes, Mingers et al.<sup>5</sup> suggested the term "pseudomembraneous disease". The actual eti-

ology is unknown but the disease is thought to be connected to local damages, infections and surgical interventions.<sup>2</sup> Since it has been shown that external triggers such as injuries, lime burns, local infections, or foreign bodies, alone or in combination with infections, may induce formation of pseudomembranes in predisposed subjects. Although most of the ligneous conjunctivitis cases are sporadic, familial cases have also been reported. The latter shows autosomal recessive inheritance. In 1994, Mingers et al.<sup>5</sup> were the first to show that this disease develops in connection with hereditary type 1 plasminogen deficiency. Since 1997, Schuster and Seregad have proved that homozygote and complex heterozygote mutations of the plasminogen gene are frequent in patients with ligneous conjunctivitis, thus confirming the autosomal recessive nature of the disease.<sup>2</sup> Since no plasminogen deficiency was found in the mother or father of our patient and no similar lesions were present in his close relatives, it was concluded that his condition had developed sporadically.

The first sign of the disease is lacrimation followed by rubescence of the conjunctiva and mucopurulent discharge. Then, yellowish white or pink ligneous pseudomembranes are formed on the palpebral surfaces. The condition is characterized by recurrence after local excision. In most cases, infants and children are affected, but the condition can develop at any age.<sup>2,6,7</sup> In our case, the condition, which was triggered by a varicella infection, recurred within a short period after a local excision.

In 51% of the cases, both eyes are affected. Approximately 26-30% of the cases report vascularization, scarring, keratomalacia and corneal involvement that can cause blindness as a result of corneal perforation.<sup>2,7</sup> In patients with ligneous conjunctivitis, involvement of various systems including oral mucosa (especially gingiva), female genital system, ears, upper digestive system, kidney and dermis involvement was reported.<sup>2,3,8-12</sup> In our case, no involvement was seen in the other eye, cornea, or in any other organs. Our case was otherwise healthy.

Histological examination of pseudomembranes from affected eyes or mucosal tissue from the genital tract exhibits a disrupted epithelium replaced by a massive deposition of fibrin and amorphous hyalin-like eosinophilic material, accompanied by an inflammatory cellular infiltration.<sup>13</sup> The amorphous hyaline-like eosinophilic substance is similar to amyloid. However, staining with amyloid dyes such as Congo red and Cresyl violet are negative. The substance is shown to include such plasma proteins as fibrin, albumin and immunoglobulins (especially IgG).<sup>14</sup> In our case, the same morphologic features were observed in terms of histopathology, and the amyloid stains were also negative.

The plasma proteins that escape the blood vessels after mechanical damage and rapid fibrinogen coagulation play a central role in the formation of pseudomembranes.<sup>15,16</sup> These fibrin clots provide hemostasis in the damaged tissue areas and form a temporary matrix on their surface. During normal wound healing, infiltrative inflammatory cells are activated and the fibrin matrix is replaced by granulation tissue, which is then replaced by a collagen-rich secondary matrix.<sup>15,16</sup> Plasmin plays a role in the destruction of the fibrin-rich extracellular matrix. The destruction of the granulation tissue is dependent on the plasminogen activator system and matrix metalloproteases (MMP). In patients with ligneous conjunctivitis, the impaired wound healing in mucous membranes is permanently fixed in the granulation tissue formation phase. The basic component of pseudomembranes is fibrinogen, which points to defective plasmin mediated extracellular fibrinolysis.<sup>1,2</sup> The development of pseudomembranes in the conjunctiva of a patient taking tranexamic acid, an antifibrinolytic drug, supports the theory that plasminogen deficiency plays a role in the pathogenesis of ligneous conjunctivitis.<sup>17</sup>

Spontaneous regression of ligneous conjunctivitis is rare. Surgical excision is used occasionally; however, the post-surgery recurrence rate is extremely high and in some cases, surgery is seen as a trigger factor in the worsening of symptoms.<sup>18-20</sup> Since hypoplasminogenemia is a strong etiologic factor, in order to prevent the membrane develop-

ment in such patients, surgical interventions should be avoided as far as possible.<sup>2</sup> In our case, the membrane that developed after the varicella infection showed recurrence shortly after the surgical excisions performed twice in two different clinics and once in our clinic.

Barabino and Rolando suggest amnion membrane transplantation because of the antiangiogenic and anti-inflammatory effects of pseudomembrane excision.<sup>21</sup>

Although many kinds of local treatment have been attempted, the results have been largely disappointing. When cyclosporine A, an immunosuppressive drug, is used locally together with topical corticosteroids, it decreases the frequency and severity of the recurrences after surgical excision without having any systemic adverse effects.<sup>2,22</sup> In our case, after the lesion was excised, 0.05% topical cyclosporine treatment was started, but the membrane developed again after a short period of time. In their 1998 study, Schott et al.<sup>23</sup> showed that after an infant with homozygote plasminogen deficiency had intravenously received purified plasminogen replacement, the membrane rapidly dissolved from the eye and the respiratory tract. However, because its half-life is very short, plasminogen should be applied frequently. Watts et al.<sup>24</sup> examined three cases of ligneous conjunctivitis and reported that in two cases the membranes completely disappeared after topical plasminogen treatment (prepared from FFP), and that a significant reduction was seen in the third case. Heidemann et al.<sup>25</sup> administered topical plasmin to a 7-year-old male patient, but because no sufficient response was received they continued the topical plasminogen treatment and received a satisfactory response. This treatment softens the membranes and facilitates their dissolution. However, it has a high cost and is difficult to prepare. Tabbara has reported that FFP is effective when administered both topically and subconjunctivally after the excision of conjunctival membranes.<sup>26</sup> Gurlu et al.<sup>27</sup> treated a neonate who had bilateral conjunctival membranes with systemic and topical FFP with no recurrence of the membranes after membrane resection. FFP treatment has the risk of triggering immunologic reac-



tions such as allergy, anaphylaxis, hemolysis, and transfusion-related acute lung injury. No systemic adverse effects related to this treatment were seen in our patient. Despite its difficulty, FFP treatment has a shorter duration and may prevent the development of systemic symptoms. Promising results have been obtained with topical and systemic FFP

treatment.<sup>16</sup> In our case, a significant reduction in membrane size was seen after this treatment and no new membrane formation was observed. Replacement therapy with sustained-release plasminogen preparations and gene treatment may provide a final solution for patients with ligneous conjunctivitis in the future.<sup>2</sup>

## REFERENCES

- Rodríguez-Ares MT, Abdulkader I, Blanco A, Touriño-Peralba R, Ruiz-Ponte C, Vega A, et al. Ligneous conjunctivitis: a clinicopathological, immunohistochemical, and genetic study including the treatment of two sisters with multiorgan involvement. *Virchows Arch* 2007; 451(4):815-21.
- Schuster V, Seregard S. Ligneous conjunctivitis. *Surv Ophthalmol* 2003;48(4):369-88.
- Lotan TL, Tefs K, Schuster V, Miller J, Manaligod J, Filstead A, et al. Inherited plasminogen deficiency presenting as ligneous vaginitis: a case report with molecular correlation and review of the literature. *Hum Pathol* 2007;38(10):1569-75.
- Tefs K, Gueorguieva M, Klammt J, Allen CM, Aktas D, Anlar FY, et al. Molecular and clinical spectrum of type I plasminogen deficiency: A series of 50 patients. *Blood* 2006;108(9):3021-6.
- Mingers AM, Heimburger N, Zeitler P, Kreth HW, Schuster V. Homozygous type I plasminogen deficiency. *Semin Thromb Hemost* 1997;23(3):259-69.
- Girard LJ, Veselinovic A, Font RL. Ligneous conjunctivitis after pingueculae removal in an adult. *Cornea* 1989;8(1):7-14.
- Hidayat AA, Riddle PJ. Ligneous conjunctivitis. A clinicopathologic study of 17 cases. *Ophthalmology* 1987;94(8):949-59.
- Günhan O, Günhan M, Berker E, Gürgan CA, Yildirim H. Destructive membranous periodontal disease (Ligneous periodontitis). *J Periodontol* 1999;70(8):919-25.
- Scully C, Gokbuget AY, Allen C, Bagan JV, Efeoglu A, Erseven G, et al. Oral lesions indicative of plasminogen deficiency (hypoplasminogenemia). *Oral Surg Oral Med Oral Pathol Oral Radiol Endod* 2001;91(3):334-7.
- Kayikcioglu F, Bulbul D, Celiker S, Kucukali T. Ligneous inflammation of the cervix: a case report. *J Reprod Med* 2005;50(10):801-4.
- Hydén D, Latkovic S, Brunk U, Laurent C. Ear involvement in ligneous conjunctivitis: a rarity or an under-diagnosed condition? *J Laryngol Otol* 2002;116(6):482-7.
- Chowdhury MM, Blackford S, Williams S. Juvenile colloid milium associated with ligneous conjunctivitis: report of a case and review of the literature. *Clin Exp Dermatol* 2000;25(2):138-40.
- Scurry J, Planner R, Fortune DW, Lee CS, Rode J. Ligneous (pseudomembranous) inflammation of the female genital tract. A report of two cases. *J Reprod Med* 1993;38(5):407-12.
- Eagle RC Jr, Brooks JS, Katowitz JA, Weinberg JC, Perry HD. Fibrin as a major constituent of ligneous conjunctivitis. *Am J Ophthalmol* 1986;101(4):493-4.
- Drew AF, Kaufman AH, Kombrinck KW, Danton MJ, Daugherty CC, Degen JL, et al. Ligneous conjunctivitis in plasminogen-deficient mice. *Blood* 1998;91(5):1616-24.
- Kao WW, Kao CW, Kaufman AH, Kombrinck KW, Converse RL, Good WV, et al. Healing of corneal epithelial defects in plasminogen- and fibrinogen-deficient mice. *Invest Ophthalmol Vis Sci* 1998;39(3):502-8.
- Diamond JP, Chandna A, Williams C, Easty DL, Scully C, Eveson J, et al. Tranexamic acid-associated ligneous conjunctivitis with gingival and peritoneal lesions. *Br J Ophthalmol* 1991;75(12):753-4.
- Bierly JR, Blandford DL, Weeks JA, Baker RS. Ligneous conjunctivitis as a complication following strabismus surgery. *J Pediatr Ophthalmol Strabismus* 1994;31(2):99-103.
- François J, Victoria-Troncoso V. Treatment of ligneous conjunctivitis. *Am J Ophthalmol* 1968;65(5):674-8.
- Schuster V, Seidenspinner S, Zeitler P, Escher C, Pleyer U, Bernauer W, et al. Compound-heterozygous mutations in the plasminogen gene predispose to the development of ligneous conjunctivitis. *Blood* 1999; 93(10):3457-66.
- Barabino S, Rolando M. Amniotic membrane transplantation in a case of ligneous conjunctivitis. *Am J Ophthalmol* 2004;137(4):752-3.
- Coşkun M, Ayıntap E, Keskin U, İlhan Ö, Tuzcu E, Semiz H, et al. [The use of topical cyclosporine in ligneous conjunctivitis after membrane excision: A report of two cases]. *Türkiye Klinikleri J Ophthalmol* 2011;20(3):162-5.
- Schott D, Dempfle CE, Beck P, Liermann A, Mohr-Pennert A, Goldner M, et al. Therapy with a purified plasminogen concentrate in an infant with ligneous conjunctivitis and homozygous plasminogen deficiency. *N Engl J Med* 1998;339(23):1679-86.
- Watts P, Suresh P, Mezer E, Ellis A, Albisetti M, Bajzar L, et al. Effective treatment of ligneous conjunctivitis with topical plasminogen. *Am J Ophthalmol* 2002;133(4):451-5.
- Heidemann DG, Williams GA, Hartzler M, Ohanian A, Citron ME. Treatment of ligneous conjunctivitis with topical plasmin and topical plasminogen. *Cornea* 2003;22(8):760-2.
- Tabbara KF. Prevention of ligneous conjunctivitis by topical and subconjunctival fresh frozen plasma. *Am J Ophthalmol* 2004;138(2):299-300.
- Gürlü VP, Demir M, Alimgil ML, Erda S. Systemic and topical fresh-frozen plasma treatment in a newborn with ligneous conjunctivitis. *Cornea* 2008;27(4):501-3.