

Analysis of Anastomotic Line Perfusion with Fluorescent Molecular Imaging After Augmentation Ileocystoplasty in Open and Robot-Assisted Laparoscopic Surgery

Açık ve Robot Yardımlı Laparoskopik Cerrahi ile Yapılan Ögmentasyon İleosistoplasti Sonrası Anastomoz Hattı Perfüzyonunun Floresan Moleküler Görüntüleme ile Değerlendirilmesi

Aydın ŞENCAN,^a
Arzu ŞENCAN,^a
Brian J. MINNILLO,^a
Hiep T. NGUYEN^a

^aDepartment of Urology,
Harvard Medical School,
Boston Children's Hospital,
Robotic Research and Training Center,
Boston, MA, USA

Geliş Tarihi/Received: 03.09.2013
Kabul Tarihi/Accepted: 25.12.2013

Yazışma Adresi/Correspondence:
Aydın ŞENCAN
Harvard Medical School,
Boston Children's Hospital,
Robotic Research and Training Center,
Department of Urology,
Boston, MA, USA
aydin.sencan@yahoo.com.tr

ABSTRACT Objective: An important complication of the augmentation ileocystoplasty is bladder perforation. Some authors have proposed that perforations result from ischemic necrosis in the bladder-bowel anastomotic sites. The aim of this study was to evaluate the tissue perfusion in the anastomotic suture line in augmentation ileocystoplasty performed with various techniques. **Material and Methods:** Four swines were used. The animals were divided into two groups, in pairs. In group 1, augmentation ileocystoplasty with U patch single-layer anastomosis (SLA) and U patch two-layer anastomosis (TLA) were performed by open surgery (OS). In group 2, the same procedures were performed with robot-assisted laparoscopic surgery (RALS). The perfusion of the bladder-ileum anastomotic line was evaluated by photodynamic eye. **Results:** The median width of the ischemic zone in SLA was 5 mm (range 2-14 mm) in OS, and 3 mm (range 2-14 mm) in RALS. The median width of the ischemic zone in TLA was 13 mm (range 10-19 mm) in OS, and 8 mm (range 4-12 mm) in RALS. **Conclusion:** In augmentation ileocystoplasty, intraoperative evaluation of the ischemic zone in the anastomotic line by photodynamic eye is an effective and feasible method. Single or two-layer anastomosis, performed either by OS or RALS seems to be not causing significant change in the ischemic zones. However, long-term results of similar studies should be determined to show the role of ischemia in the etiology of bladder perforations after augmentation ileocystoplasty.

Key Words: Ischemia; intestinal perforation; urinary bladder diseases

ÖZET Amaç: Ögmentasyon ileosistoplastisinin önemli komplikasyonlarından biri mesane perforasyonudur. Bazı yazarlar perforasyonun, barsak-mesane anastomoz hattındaki iskemik nekrozun sonucu olarak geliştiğini öne sürmektedir. Bu çalışmada, çeşitli tekniklerle yapılan ögmentasyon sistoplastisinde anastomoz hattındaki doku perfüzyonunu değerlendirmek amaçlanmıştır. **Gereç ve Yöntemler:** Çalışmada 4 domuz kullanıldı. Denekler ikiye iki gruba ayrıldı. Grup I'de açık cerrahi yöntemle ilk deneye "U" yama tek tabaka, ikinci deneye "U" yama çift tabaka anastomoz yapılarak, ögmentasyon ileosistoplastisi oluşturuldu. Grup II'de robotik yardımlı laparoskopik cerrahi ile ilk deneye "U" yama tek tabaka, ikinci deneye "U" yama çift tabaka anastomoz yapılarak, ögmentasyon ileosistoplastisi oluşturuldu. Mesane-ileum anastomoz hattının perfüzyonu fotodinamik göz ile değerlendirildi. **Bulgular:** Açık cerrahi ile yapılan tek tabaka anastomozda iskemik zonun medyan genişliği 5 mm (aralık 2-14 mm), robotik teknikte ise 3 mm (aralık 2-14 mm) saptanırken, çift tabaka anastomozda iskemik zonun medyan genişliği açık cerrahide 13 mm (aralık 10-19 mm), robotik teknikte ise 8 mm (aralık 4-12 mm) idi. **Sonuç:** Ögmentasyon sistoplastisinde anastomoz hattındaki iskemik zonun fotodinamik göz ile intraoperatif değerlendirilmesi uygun ve etkili bir yöntemdir. Anastomozun tek veya çift tabaka ya da açık veya robotik cerrahi ile yapılması iskemik zonu etkilemiyor gibi gözükmektedir. Ancak ögmentasyon sistoplastisi sonrası görülen mesane perforasyonunda iskeminin rolünü değerlendirmek için, daha fazla denekte ve geç dönem sonuçları ortaya koyan yeni çalışmalarını yapılması gerekmektedir.

Anahtar Kelimeler: İskemi; intestinal perforasyon; mesane hastalıkları

doi: 10.5336/medsci.2013-37506

Copyright © 2014 by Türkiye Klinikleri

Türkiye Klinikleri J Med Sci 2014;34(3):328-33

Augmentation cystoplasty is a surgical procedure performed to increase the bladder capacity and compliance while reducing the storage pressure. The main goal of this surgery is to prevent the deterioration of upper urinary tract, and to achieve urinary continence by creating a compliant storage reservoir for urine.¹⁻⁴ Early and late complications may be encountered after augmentation cystoplasty. The most important and a potentially lethal complication is bladder perforation.⁵⁻⁸ The etiology of bladder perforation is not exactly known. However, some authors have suggested that it is related to ischemic changes at the ileal-anastomotic line.

Fluorescent molecular imaging is an important diagnostic tool which is commonly used for evaluating intraoperative tissue perfusion. Its most important advantage is that it allows evaluation of tissue perfusion during surgery. Determination of tissue ischemia during surgery is helpful for real-time surgical decision-making, and anastomotic revisions before completing the operation.⁹⁻¹¹

To our knowledge, no studies up to date evaluated the surgical techniques used for augmentation cystoplasty. Likewise, we do not know whether U-shaped bowel patch or single or two-layer anastomosis affect tissue perfusion, or these techniques have any association with postoperative spontaneous bladder perforations. This study aimed to evaluate the tissue perfusion peri-operatively using fluorescent molecular imaging in the anastomotic line after augmentation cystoplasty performed by various techniques.

MATERIAL AND METHODS

This research was performed in Boston Children's Hospital, Harvard Medical School, Research and Training Center for Robotic Surgery. The study was approved by our institution's Animal Research Committee, and animal rights were preserved.

In this study, 4 Yorkshire female swines weighed between 30-35 kg were used. The animals were divided into two groups of two subjects in each. In group 1, augmentation ileocystoplasty with U-patch single-layer anastomosis and U-patch

two-layer anastomosis were performed by open surgical technique. In group 2, the same procedures were performed by robotic-assisted laparoscopic surgery.

All animals were anesthetized with an intramuscular injection of tiletamine (4.4 mg/kg), zolazepam (6.6 mg/kg), xylazine (1.1 mg/kg) and atropine (0.04 mg/kg) for induction. The animals were then intubated, and isoflurane (1-4%) and oxygen (1-2L) were given endotracheally.

OPEN SURGICAL TECHNIQUE

Peritoneal cavity was entered through an infraumbilical transverse incision when the animal was positioned supine. An ileal segment measuring 20 cm in length with adequate mobility of the mesentery was isolated. Intestinal continuity was reestablished with end-to-end ileoileostomy. The isolated ileal segment was thoroughly irrigated and then opened along its antimesenteric border, and reconfigured into a U-shaped patch using running 4-0 Vicryl suture. The patch was folded over, and the lateral edges were sewn together. Using electrocautery, the bladder dome was incised in a medial to lateral and anterior to posterior fashion making 4 triangle shaped flaps. The U-shaped ileal patch was brought down to the bladder, and sewn in with 4-0 Vicryl running suture using single-layer closure in one animal, and two-layer closure in the other. The vascularity of the anastomosis site was evaluated with photodynamic eye.

ROBOTIC-ASSISTED LAPAROSCOPIC SURGERY

Peritoneal cavity was entered with a Veress needle 2 cm above the umbilicus in the midline, and CO₂ insufflation was done with a pressure of 10 mmHg. A 12-mm trocar was introduced through the radially expanding sheath into the abdomen to serve as the camera port. Two 8-mm trocars were placed into the abdomen, 1 cm below the camera port at the right, and left lateral border of the rectus abdominis muscle, to serve as ports for the robotic instruments. An additional 12-mm trocar was then placed lateral to the working port on the left side, approximately 5 cm inferiorly. This additional port was used for passing sutures and

eliminating the need to disengage the robot instruments from the 8-mm ports. The operating table was then positioned to make the animal in the Trendelenburg position, and the da Vinci (Intuitive Surgical Corp., Sunnyvale CA) robot system was engaged. Augmentation cystoplasty with U-shaped ileal patch was performed with the same technique as open surgery with single-layer anastomosis in one animal, and two-layer anastomosis in another. The U-patch was fashioned extra-corporeally followed by intra-corporeal intestinal-bladder anastomosis.

FLUORESCENT MOLECULAR IMAGING WITH PHOTODYNAMIC EYE

Molecular imaging was performed with photodynamic eye intraoperatively, under general anesthesia, after completion of the surgery in each animal. Since the photodynamic eye was too big to pass through the ports, an infraumbilical transverse incision was made to insert it into the abdominal cavity for the robotic procedures.

Right after the injection of 1 ml Indocyanine Green (Sigma-Aldrich), the perfusion of the bladder-ileum anastomotic line was evaluated using photodynamic eye (Hamamatsu Photo Dynamic Eye-Hamamatsu-Japan). The photodynamic eye was placed 15 cm above the anastomotic line, and images were obtained and recorded. The images were printed and longitudinal lines with 3-mm intervals were drawn on the images. The widths of the ischemic zones corresponding to the lines were measured with a linear scale, and the measured values were expressed as median [minimum-maximum (min-max)].



FIGURE 1: The ischemic zone in the single-layer bladder-bowel anastomotic line in open surgery.

After the operations were completed, the animals were euthanized according to United States Department of Agriculture regulations. Statistical analysis was not performed because there was only one swine in each of the different surgical groups.

RESULTS

Ileal augmentation cystoplasty was successfully completed in all animals by both open and robotic-assisted laparoscopic surgery.

The median (min-max) width of the ischemic zone in single-layer anastomosis was 5 mm (min 2-max 14 mm) in open surgery group (Figure 1) and 3 mm (min 2-max 14 mm) in robotic surgery group (Figure 2). The median width of the ischemic zone in two-layer anastomosis was 13 mm (min 10-max 19 mm) in open surgery group (Figure 3) and 8 mm (min 4-max 12 mm) in robotic surgery group (Figure 4) (Table 1).

The duration of the operation was 4 hours 20 minutes in single-layer anastomosis, and 5 hours 15 minutes in two-layer anastomosis in the open surgery group. The duration of the operation was 7 hours 12 minutes in single-layer anastomosis and 9 hours 10 minutes in two-layer anastomosis in the robotic surgery group. The operative time was much longer in two-layer anastomosis compared to single-layer anastomosis in both groups. Similarly, operative time was significantly longer in robotic-assisted laparoscopic surgery, compared to open surgery.

DISCUSSION

Bladder augmentation is associated with a number of short and long-term potential risks including bacteruria, mucosuria, bladder stones, metabolic

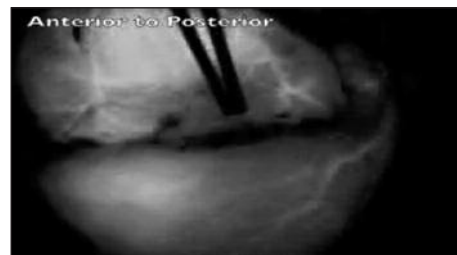


FIGURE 2: The ischemic zone in the single-layer bladder-bowel anastomotic line in robot-assisted laparoscopic surgery.

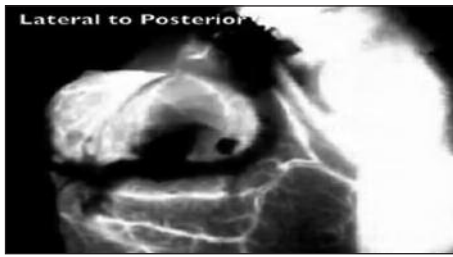

FIGURE 3: The ischemic zone in the two-layer bladder-bowel anastomotic line in open surgery.

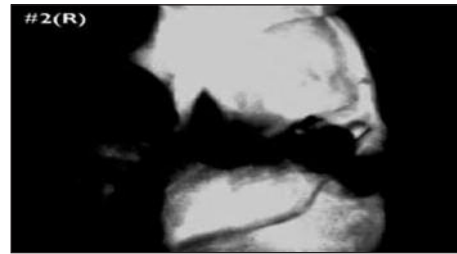


FIGURE 4: The ischemic zone in the two-layer bladder-bowel anastomotic line in robot-assisted laparoscopic surgery.

disorders, and bladder perforation.¹² Bladder perforation is a very important and life-threatening complication. Although various factors associated with bladder perforation have been proposed, its etiology is not exactly known.¹³ The aim of this study was to determine whether specific ischemic zones exist during augmentation ileocystoplasty at single-layer or two-layer anastomotic sites, and to evaluate whether different surgical techniques will yield any difference in severity of ischemia at the anastomotic site.

Perforation after augmentation enterocystoplasty has been reported to occur with an incidence of 5-13%.^{2,5,13} Perforations may occur months, even years after surgery, and multiple simultaneous perforations in the same patient are also possible.^{2,5} Some authors postulated that perforations resulted from direct catheter trauma at the time of intermittent catheterization or intraluminal adhesions causing distortion of the bladder. Other authors argued that increased intraluminal pressure or extraluminal adhesions between the augmenting segment and the abdominal wall were risk factors for perforation. Finally, some authors proposed that perforations resulted from ischemic necrosis.¹⁴⁻¹⁸

Peristaltic contraction of the applied bowel, detrusor hyperreflexia, and high micturation pressure are factors increasing the intraluminal pressure. Increased intraluminal pressure may induce ischemia by causing muscle tension. High pressure may also develop when mucus or debris prevents complete emptying.¹⁴⁻¹⁷ Elder et al. have theorized that intraluminal adhesions can distort and fix the bladder so that a catheter might contact and traumatize the same region repeatedly.⁶ However, the

TABLE 1: The median (minimum-maximum) values of the ischemic zones in the anastomotic line after augmentation ileocystoplasty in open and laparoscopy-assisted robotic surgery.

Surgical technique	SLA (ischemic zone) (mm)	TLA (ischemic zone) (mm)
Open surgery	5 (min 2-max 14)	13 (min 10-max 19)
Laparoscopy-assisted robotic surgery	3 (min 2-max 14)	8 (min 4-max 12)

SLA: single-layer anastomosis; TLA: two-layer anastomosis; min: Minimum; max: Maximum.

occurrence of perforations in patients who are never catheterized and perforations seen in patients who undergo catheterization at remote sites within the bladder undermine this hypothesis. Sheiner and Kaplan⁷ have suggested that perforation may occur when adhesions between the augmenting segment and the abdominal wall (extraluminal) are avulsed, as the bladder distends. The risk of perforation after augmentation is higher in neurogenic bladder. The need for intermittent catheterization because of high outlet resistance and the tendency for overdistension of the bladder due to diminished sensation put neurogenic bladder patients at risk for perforation.¹⁸ The interaction of multiple factors, of course, may cause perforation. However, the exact cause of bladder perforation in the postoperative period remains elusive.

Crane et al. have proposed the hypothesis of ischemic necrosis for the pathogenesis of spontaneously ruptured enterocystoplasty.¹⁴ They reported 3 episodes of spontaneously perforated sigmoid enterocystoplasty in two patients. The histopathological examination of tissue specimens of these ruptured enterocystoplasties revealed sig-

nificant vascular congestion, hemorrhage and accumulation of numerous hemosiderin-laden macrophages which reflect chronically abnormal vascular perfusion. Other markers, including mucosal atrophy and necrosis, bowel wall fibrosis and myofiber atrophy support bowel ischemia. We propose that enterocystoplasty rupture is associated with tissue ischemia, regardless of the increased intraluminal pressure or chronically abnormal vascular perfusion. To our knowledge, our study is the first to evaluate the presence of ischemic zones in the anastomotic lines in the early postoperative period, and to investigate whether different surgical techniques caused any difference in the ischemic zones, by molecular imaging technique.

Successful reports of the use of the fluorescent molecular imaging (Indocyanine Green) for the per-operative evaluation of tissue vasculature and perfusion in anastomosis have been increasing in the literature.⁹⁻¹¹ In this current study, U-shaped ileal enterocystoplasty was performed by both open and laparoscopy-assisted robotic surgery. Ischemic zones were identified in both groups, and they were similar in length. The ischemic zone in the two-layer anastomosis was slightly larger than that of the single-layer anastomosis, but it is not possible to make a definitive conclusion due to the small number of animals in this pilot study. Robotic surgery provides three-dimensional and magnified visualization of the operative field, helping more delicate and easier dissection. Despite these advantages of robotic surgery, there was no significant difference between the ischemic zones at the anastomotic lines of ileocystoplasty in the open surgery group and the robotic surgery group. In other words, if the ischemic zone in the anastomotic line is accepted to have a role in bladder perforations after ileocystoplasty, the type of surgical technique or single or two-layer anastomosis seems does not seem to contribute in the pathogenesis. However, performing ileocystoplasty by laparoscopy-assisted robotic surgery or making two-layer bladder-bowel anastomosis significantly increase the operative time.

There are some limitations to our study. There small number of animals was in each group. The low bladder compliance of swine compared to human bladder, and the lack of neurogenic bladder in these animals also may not represent the standard patients who undergo augmentation enterocystoplasty. Furthermore, quantitative assessment of the ischemic zone at all areas surrounding the anastomotic line is very difficult. The method of drawing millimetric lines on the picture of anastomotic line that we designed can just give an idea about the width of the ischemic zone, not exactly represent the actual size. The ischemic zones at the anastomotic lines were visualized at the very early stage (intraoperative). Collateral vessels may develop at the anastomotic line in the immediate postoperative healing phase. Therefore, the ischemic zones occurring in the anastomotic line in the early postoperative period may not have a role in the etiology of delayed perforations of augmented bladder. The size of the photodynamic eye is too big to pass through the trocars in laparoscopy-assisted robotic surgery. Therefore, the need to convert to open surgery for the evaluation of the vascularity of the anastomotic line seems to be another disadvantage. However, the development of technologically smaller sizes of photodynamic eye may help to overcome this problem.

CONCLUSION

The intraoperative evaluation of the ischemic zones in the anastomotic line in augmentation ileocystoplasty by a photodynamic eye is an effective and feasible method. Performing the bladder-bowel anastomosis in single-layer or two-layer, either by open surgery or robotic-assisted laparoscopic surgery seems does not seem to cause any significant change in the ischemic zones. However, larger studies with long-term results are needed to validate the role of ischemia in the etiology of bladder perforations after augmentation enterocystoplasty.

REFERENCES

- Gearhart JP, Albertsen PC, Marshall FF, Jeffs RD. Pediatric applications of augmentation cystoplasty: the Johns Hopkins experience. *J Urol* 1986;136(2):430-2.
- Shekarriz B, Upadhyay J, Demirebilek S, Barthold JS, González R. Surgical complications of bladder augmentation: comparison between various enterocystoplasties in 133 patients. *Urology* 2000;55(1):123-8.
- Flood HD, Malhotra SJ, O'Connell HE, Ritchey MJ, Bloom DA, McGuire EJ. Long-term results and complications using augmentation cystoplasty in reconstructive urology. *Neurourol Urodyn* 1995;14(4):297-309.
- Decter RM, Bauer SB, Mandell J, Colodny AH, Retik AB. Small bowel augmentation in children with neurogenic bladder: an initial report of urodynamic findings. *J Urol* 1987;138(4 Pt 2):1014-6.
- DeFoor W, Tackett L, Minevich E, Wacksman J, Sheldon C. Risk factors for spontaneous bladder perforation after augmentation cystoplasty. *Urology* 2003;62(4):737-41.
- Elder JS, Snyder HM, Hulbert WC, Duckett JW. Perforation of the augmented bladder in patients undergoing clean intermittent catheterization. *J Urol* 1988;140(5 Pt 2):1159-62.
- Sheiner JR, Kaplan GW. Spontaneous bladder rupture following enterocystoplasty. *J Urol* 1988;140(5 Pt 2):1157-8.
- Rushton HG, Woodard JR, Parrott TS, Jeffs RD, Gearhart JP. Delayed bladder rupture after augmentation enterocystoplasty. *J Urol* 1988;140(2):344-6.
- Mitsui Y, Shiina H, Arichi N, Hiraoka T, Inoue S, Sumura M, et al. Indocyanine green (ICG)-based fluorescence navigation system for discrimination of kidney cancer from normal parenchyma: application during partial nephrectomy. *Int Urol Nephrol* 2012;44(3):753-9.
- Tobis S, Knopf J, Silvers C, Yao J, Rashid H, Wu G, et al. Near infrared fluorescence imaging with robotic assisted laparoscopic partial nephrectomy: initial clinical experience for renal cortical tumors. *J Urol* 2011;186(1):47-52.
- van der Poel HG, Buckle T, Brouwer OR, Valdés Olmos RA, van Leeuwen FW. Intraoperative laparoscopic fluorescence guidance to the sentinel lymph node in prostate cancer patients: clinical proof of concept of an integrated functional imaging approach using a multimodal tracer. *Eur Urol* 2011;60(4):826-33.
- Austin JC. Long-term risks of bladder augmentation in pediatric patients. *Curr Opin Urol* 2008;18(4):408-12.
- Metcalfe PD, Casale AJ, Kaefer MA, Misseri R, Dussinger AM, Meldrum KK, et al. Spontaneous bladder perforations: a report of 500 augmentations in children and analysis of risk. *J Urol* 2006;175(4):1466-70; discussion 1470-1.
- Crane JM, Scherz HS, Billman GF, Kaplan GW. Ischemic necrosis: a hypothesis to explain the pathogenesis of spontaneously ruptured enterocystoplasty. *J Urol* 1991;146(1):141-4.
- Essig KA, Sheldon CA, Brandt MT, Wacksman J, Silverman DG. Elevated intravesical pressure causes arterial hypoperfusion in canine colocolocystoplasty: a fluorometric assessment. *J Urol* 1991;146(2 (Pt 2)):551-3.
- Sidi AA, Reinberg Y, Gonzalez R. Influence of intestinal segment and configuration on the outcome of augmentation enterocystoplasty. *J Urol* 1986;136(6):1201-4.
- Anderson PA, Rickwood AM. Detrusor hyperreflexia as a factor in spontaneous perforation of augmentation cystoplasty for neuropathic bladder. *Br J Urol* 1991;67(2):210-2.
- Braverman RM, Lebowitz RL. Perforation of the augmented urinary bladder in nine children and adolescents: importance of cystography. *AJR Am J Roentgenol* 1991;157(5):1059-63.