

Pseudoxanthoma Elasticum with Mallory-Weiss Syndrome: Case Report

Psödoksantoma Elastikum ile Mallory-Weiss Sendromu Birlikteliği

Fatma PAKSOY TÜRKÖZ, MD,^a
Turgay ULAŞ, MD, Assis.Prof.,^b
Cemal BES, MD,^c
Koray ÖZKAN, MD, Msc,^d
Damlanur SAKIZ, MD, Assoc.Prof.,^e
Mehmet Sinan DAL, MD, Msc,^f
Fatih BORLU, MD, Msc^g

^aDepartment of Medical Oncology,
Abdurrahman Yurtaslan Training and
Research Hospital, Ankara

^bDepartment of Internal Medicine,
Harran University Faculty of Medicine,
Şanlıurfa

^cDepartment of Rheumatology,
Abant İzzet Baysal University
Faculty of Medicine, Bolu

^dDepartment of Dermatology,
Medical Park Hospital, Gaziantep
Departments of

^ePathology,

^fInternal Medicine, İstanbul

^gDepartment of Internal Medicine,
Çınar State Hospital, Diyarbakır

Geliş Tarihi/Received: 20.12.2010

Kabul Tarihi/Accepted: 22.04.2011

Yazışma Adresi/Correspondence:

Turgay ULAŞ, MD, Assis.Prof.
Harran University Faculty of Medicine,
Department of Internal Medicine,
Şanlıurfa,
TÜRKİYE/TURKEY
turgayulas@yahoo.com

doi: 10.5336/medsci.2010-22259

Copyright © 2012 by Türkiye Klinikleri

ABSTRACT Pseudoxanthoma elasticum is a multi-systemic, genetic disorder of the connective tissue characterized by progressive calcification and fragmentation of elastic fibers in skin, retina, gastrointestinal and cardiovascular systems. Skin changes generally manifest in adulthood and rarely in childhood. Upper gastrointestinal hemorrhage occurs in some cases and is frequently resistant to nonsurgical methods of treatment. As the prognosis of pseudoxanthoma elasticum is related to the involvement of extracutaneous organs, early recognition of the disease is important to take preventive measures and to decrease the morbidity. Herein, we presented a case of pseudoxanthoma elasticum with Mallory-Weiss syndrome, who had repetitive and massive upper gastrointestinal bleeding. To our knowledge, there is no reported case of pseudoxanthoma elasticum with Mallory-Weiss syndrome in the literature.

Key Words: Elastic tissue; Mallory-Weiss syndrome; gastrointestinal hemorrhage

ÖZET Psödoksantoma elastikum, bağ dokusunun, cilt, retina, gastrointestinal ve kardiyovasküler sistemlerde elastik fibrillerin progresif kalsifikasyonu ve fragmantasyonu ile karakterize olan ve birden çok sistemi tutan genetik bir bozukluğudur. Cilt değişiklikleri genelde yetişkinlikte belirginleşmekte, çocukluk döneminde nadiren gözlenmektedir. Üst gastrointestinal kanama bazı olgularda ortaya çıkar ve cerrahi dışı yöntemlerle tedaviye genelde dirençlidir. Psödoksantoma elastikumun prognozu ekstrakutanöz organların tutulumuna bağlı olduğundan, erken tanı, önleyici girişimler ve morbiditeyi azaltmak yönünden önemlidir. Bu makalede, tekrarlayan ve masif üst gastrointestinal sistem kanamaları olan Mallory-Weiss sendromlu bir psödoksantoma elastikum olgusu sunulmuştur. Mevcut bilgilerimize göre literatürde, Mallory-Weiss sendromlu psödoksantoma elastikum olgusu daha önce bildirilmemiştir.

Anahtar Kelimeler: Elastik doku; Mallory-Weiss sendromu; gastrointestinal kanama

Türkiye Klinikleri J Med Sci 2012;32(3):887-90

Pseudoxanthoma elasticum (PXE) is a rare hereditary connective tissue disorder with an incidence rate of between 1/70 000 and 1/100 000 and 2:1 female to male ratio.¹ It is caused by mutations in the adenosine triphosphate-binding cassette subtype C number 6 (ABCC6) gene localized on the human chromosome 16p13.1, which is expressed primarily in the liver, kidneys and at very low levels in the affected tissues. The disease is genetically heterogenous; most cases are sporadic, but cases with autosomal recessive or dominant inheritance have been reported.^{2,3} PXE is characterized by the degeneration of the elastic tissue involving many organ

systems, with typical cutaneous, ocular, vascular and gastrointestinal manifestations. Gastrointestinal (GI) hemorrhage is a rare complication of PXE. We presented a case of PXE with Mallory-Weiss syndrome (MWS), who had repetitive and massive upper GI bleeding.

CASE REPORT

A 50-year-old woman was admitted to our hospital with melena and hematemesis. On admission, she appeared fatigued. The initial blood pressure was 100/60 mmHg, pulse rate was 96 beats/minute and digital rectal examination revealed melena. The chest, cardiovascular, gastrointestinal and genitourinary system examination were unremarkable. She was noted to have multiple yellowish papules of 1 to 4 mm diameter around the neck and on the inner aspect of the lower lip (Figure 1). Two weeks before admission, she had been hospitalized for acute upper gastrointestinal (GI) hemorrhage. Gastroscopy had revealed no evidence of bleeding. There were no predisposing causes for bleeding.

Laboratory investigations were as follows: haemoglobin 8.5 g/dL and hematocrit 26.5%. Biochemical tests including liver and renal function tests, serum electrolytes and proteins were within

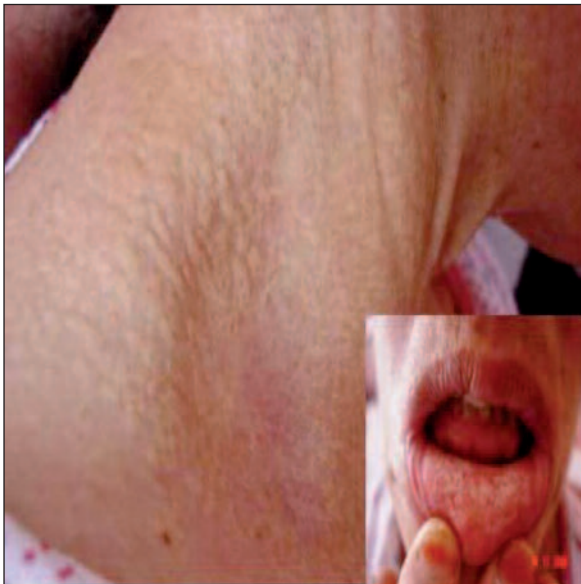

FIGURE 1: Multiple yellowish papules around the neck and on the lower lip. (see for colored form <http://dishekimligi.turkiyeklinikleri.com/>)

normal limits. Coagulation parameters and bleeding time were normal.

Upper GI endoscopy at admission revealed no active bleeding. Intravenous proton pump inhibitor (PPI) and oral antiacid treatments were initiated and two units of erythrocyte suspension were transfused. On the third day of hospitalization, she suddenly developed massive hematemesis and the upper GI endoscopy was repeated. It revealed Mallory-Weiss tear and fundal pool of fresh blood. Injection sclerotherapy was performed. Despite the medical and endoscopic treatment, she redeveloped massive hematemesis on the fourth day of hospitalization. The patient was successfully treated by sclerotherapy and therefore surgery was not required. Fourteen units of erythrocyte suspension and four units of fresh frozen plasma were transfused during hospitalization.

Biopsy by a dermatologist from the yellowish papules on the neck revealed small foci of calcification in the papillary and mid-reticular dermis with Hematoxylen-Eosin (H&E) stain and short, curled, fragmented basophilic elastic fibers around those foci with Verhoeff-Van Gieson (VVG) stain (Figure 2,3). Histopathological findings were consistent with PXE.

The funduscopic examination was normal. Echocardiography revealed degeneration and nodular calcification of mitral valve. She had experienced no further episodes of GI hemorrhage and no additional signs of systemic involvement were found during the 1-year follow-up period.

DISCUSSION

The most common presentation of skin lesions in PXE is yellowish-colored papules varying in size from 1 to 5 mm, which may coalesce into plaques with a cobblestone appearance. Typical skin lesions are located on the neck and in flexural areas. As the disease progresses the affected skin may become lax and wrinkled, hanging in folds. Mucosal lesions may be found on the inner aspect of the lower lip, on the cheeks or the palate, or on the genitalia, but also all along the mucous membrane of the digestive tract.^{2,4} We determined yellowish papules

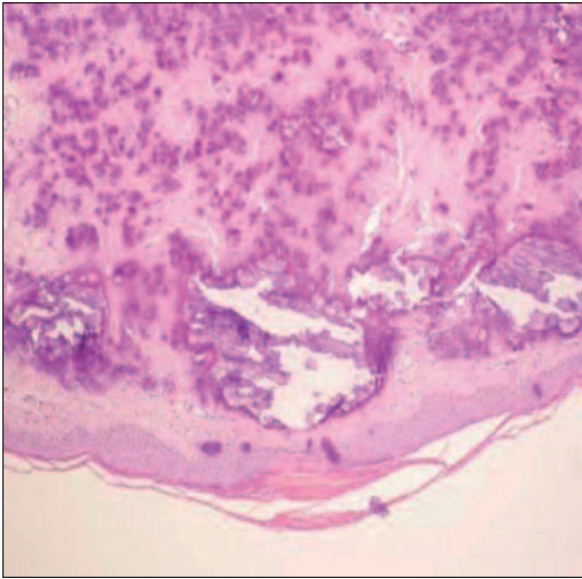


FIGURE 2: Small foci of calcification in the papillary and mid-reticular dermis of the yellowish papules on the neck (H&E \times 200).

(see for colored form <http://dishekimligi.turkiyeklinikleri.com/>)

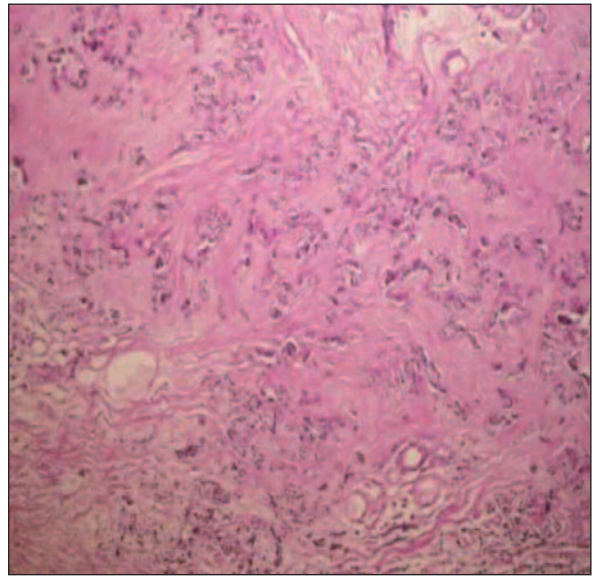


FIGURE 3: Short, curled, fragmented basophilic elastic fibers of the yellowish papules on the neck (VVG \times 400).

(see for colored form <http://dishekimligi.turkiyeklinikleri.com/>)

around the neck and on the inner aspect of the lower lip in our patient.

Angioid streaks are ruptures in the calcified Bruch's membrane in the retina and appear to be present in at least 85% of the patients.^{4,5} In the present case, no significant lesion was observed during the examination of the fundus oculi.

The cardiovascular manifestations of PXE include coronary artery disease, peripheral vascular disease, hypertension, mitral valve prolapse and stenosis, restrictive cardiomyopathy and sudden death.^{2,6,7} Our patient who was asymptomatic had degeneration and nodular calcification of the mitral valve.

GI hemorrhage, usually recurrent and gastric in origin, was reported in 13% of cases. Our patient had experienced the first episode of GI bleeding two weeks before admission. GI bleeding is thought to result from calcification of the elastic fibers in the thin-walled arteries located directly under the gastric mucosa, which leads to aneurysmal dilatation and subsequent rupture of the vessels. In addition to the internal elastic lamellar degeneration and dystrophic calcification, the presence of ultrastructurally abnormal collagen fibers in the gastric vascular bed may directly cause GI

hemorrhage. The inability of arterioles to retract also increases the risk of hemorrhage from unrelated causes such as peptic ulcer disease.^{8,9} In the presented case, Mallory-Weiss tear was thought to be caused by the disorganization of collagen and elastic fibers.

The characteristic endoscopic findings include distinctive yellow cobblestone appearance or nodular raised submucosal lesions, but frequently they have a normal appearance. The first upper GI endoscopy revealed normal appearance and the repeated endoscopy showed Mallory-Weiss tear in our patient. Although the hemorrhage due to MWS usually ceases spontaneously, MWS with PXE was repetitive in the present case.

Biopsy of the affected skin is mandatory for the diagnosis. The classic histopathological sign of PXE is the calcification and degeneration in elastic fibers in the mid and deep reticular dermis. The elastic fibers become pleomorphic, fragmented and clumped, which may be demonstrated by H&E or VVG staining. Deposition of calcium may be shown by von Kossa staining.^{4,10} The extent of fragmentation of affected elastic fibers is dramatically related with disease progression.¹⁰ In this case, the skin biopsy from the involved area revealed milia

like calcification in mid-reticular dermis with H&E stain and short, curled, fragmented elastic fibers with VVG stain consistent with PXE.

There is no specific treatment for PXE. To reduce the risk of bleeding, platelet inhibitors such as aspirin and non-steroidal anti-inflammatory drugs as well as warfarin should generally be avoided.⁴ Anti-secretory drugs and vasoconstricting agents are frequently unsuccessful in controlling bleeding. Despite the intravenous PPI and antacid treatment, the case developed repetitive and massive upper GI hemorrhage. Angiographic embolization of the involved vessels has been used with variable results. Partial gastrectomy, total gas-

trectomy, oversewing of the bleeding site and gastric devascularization are the surgical options in patients who have recurrent GI bleeding in PXE.^{1,4,8,9} The patient was successfully treated by sclerotherapy and therefore, surgery was not required.

Patients with repetitive and massive upper GI hemorrhage must be carefully examined physically for the typical yellowish papules of PXE, especially if endoscopic examination fails to reveal the cause. Ocular and cardiovascular damages are major causes of morbidity and mortality of the disease.^{2,4,11} In conclusion, early diagnosis and screening the asymptomatic family members are important for minimization of systemic complications.

REFERENCES

1. Hu X, Plomp AS, van Soest S, Wijnholds J, de Jong PT, Bergen AA. Pseudoxanthoma elasticum: a clinical, histopathological, and molecular update. *Surv Ophthalmol* 2003;48(4): 424-38.
2. Chassaing N, Martin L, Calvas P, Le Bert M, Hovnanian A. Pseudoxanthoma elasticum: a clinical, pathophysiological and genetic update including 11 novel ABCC6 mutations. *J Med Genet* 2005;42(12):881-92.
3. Polat M, Dikilitaş MC, Tamer E, Çınar L, Üstün H, Allı N. [Pseudoxanthoma elasticum]. *Turkiye Klinikleri J Dermatol* 2009;19(1):27-30.
4. Laube S, Moss C. Pseudoxanthoma elasticum. *Arch Dis Child* 2005;90(7):754-6.
5. Agarwal A, Patel P, Adkins T, Gass JD. Spectrum of pattern dystrophy in pseudoxanthoma elasticum. *Arch Ophthalmol* 2005;123(7):923-8.
6. Kocaman SA, Tavil Y, Yalçın MR. Severe coronary artery disease in a 21-year-old girl with pseudoxanthoma elasticum and anomalous origin of the right coronary artery. *Acta Cardiol* 2007;62(4):417-9.
7. Fukuda K, Uno K, Fujii T, Mukai M, Handa S. Mitral stenosis in pseudoxanthoma elasticum. *Chest* 1992;101(6):1706-7.
8. Spinzi G, Strocchi E, Imperiali G, Sangiovanni A, Terruzzi V, Minoli G. Pseudoxanthoma elasticum: a rare cause of gastrointestinal bleeding. *Am J Gastroenterol* 1996;91(8): 1631-4.
9. Costopanagiotou E, Spyrou S, Farantos C, Kostopanagiotou G, Smyrniotis V. An unusual cause of massive gastric bleeding in a young patient. *Am J Gastroenterol* 2000;95(9):2400-1.
10. Lebwohl M, Schwartz E, Lemlich G, Lovelace O, Shaikh-Bahai F, Fleischmajer R. Abnormalities of connective tissue components in lesional and non-lesional tissue of patients with pseudoxanthoma elasticum. *Arch Dermatol Res* 1993;285(3):121-6.
11. Bercovitch L, Terry P. Pseudoxanthoma elasticum 2004. *J Am Acad Dermatol* 2004;51(1 Suppl):S13-4.