

Neglected Urethral Stone's Catastrophic Outcome: Fournier's Gangrene

İhmal Edilen Üretral Taşın Katastrofik Sonucu: Fournier Kangreni

Mustafa SESLİ^a, Mert BAŞARANOĞLU^a, Melih BIYIKOĞLU^a, Erim ERDEM^a

^aMersin University Faculty of Medicine, Department of Urology, Mersin, Türkiye

ABSTRACT A 73-year-old male presented to the emergency department with urinary retention, penile swelling, and penile color changes, indicative of a critical condition. Physical examination revealed necrotic areas on the penile skin and subcutaneous crepitus extending to the suprapubic region. Computed tomography confirmed bilateral hydronephrosis, severe bladder distension, a stone in the mid-penile urethra, and air densities in the abdominal wall's subcutaneous fat layers, consistent with necrotizing fasciitis (NF). Prompt surgical debridement and cystourethroscopy were performed, addressing the infection through sequential debridements and parenteral antibiotics. Repair the urethral defect secondary to necrosis was performed, followed by reconstruction of the debrided area using a fasciocutaneous flap for the skin defect. Despite successful outcomes from rapid and multiple interventions, the case highlights the rare scenario where neglected urethral stones can potentially lead to NF.

ÖZET Yetmiş üç yaşındaki bir erkek hasta, idrar retansiyonu, penis şişmesi ve peniste renk değişiklikleri şikâyetleriyle acil servise başvurdu. Fiziksel muayenede penil deride nekrotik alanlar ve suprapubik bölgeye kadar uzanan subkütan kremitus tespit edildi, bu da ürolojik bir acili işaret ediyordu. Bilgisayarlı tomografi, bilateral hidronefroz, ciddi mesane distansiyonu, orta penis uretrasında taş opasitesi ve karın duvarının subkütan yağ tabakalarında pelvik girişe kadar uzanan hava dansitelerini gösteren nekrotizan fasiit ile uyumlu bulgular ortaya koydu. Hastaya acil cerrahi debridman uygulandı ve sistoüretroskopi yapıldı. Enfeksiyon tedavisinin ardından seri debridmanlar ve parenteral antibiyotik tedavisi ile tedavi edildikten sonra, nekroz kaynaklı üretral defekt onarıldı. Ardından debride edilen alan rekonstrüksiyon için hazırlandı ve cilt defekti, fasyokutanöz flep kullanılarak onarıldı. Hasta hızlı ve çoklu müdahalelerle tatmin edici sonuçlar elde etmiş olmasına rağmen ihmal edilen üretral taşların nadiren rastlanan bir durumu potansiyel olarak nekrotizan fasiite yol açabileceği unutulmamalıdır.

Keywords: Urinary stones; Fournier's gangrene; urinary retention

Anahtar Kelimeler: Üriner taşlar; Fournier kangreni; idrar retansiyonu

Urolithiasis is the third most prevalent pathology within the urinary system, following infectious and prostatic diseases. Approximately 0.3-2% of these stones are estimated to be in the urethra. Urethral stones are typically managed expectantly, with pain medications and hydration, as they often develop and grow slowly. However, stones that form in the upper urinary system and migrate to the urethra typically cause acute symptoms. Endoscopic stone extraction may be attempted if the stricture is amenable to internal urethrotomy and the stones are small.¹

necrotizing fasciitis (NF) and obstructive uropathy stand out as life-threatening complications associated with urolithiasis.^{2,3}

Fournier's gangrene (FG) is NF that affects the perineal, genital, perianal tissues, and abdominal wall. This rare, rapidly progressing, potentially life-threatening infection constitutes a urological emergency. Depending on the severity of its clinical presentation, FG carries a mortality rate ranging from 10% to 20% and was initially described by Jean Alfred Fournier in 1883.^{3,4} Isolated cases involving the

TO CITE THIS ARTICLE:

Sesli M, Başaranoğlu M, Biyikoğlu M, Erdem E. Neglected urethral stone's catastrophic outcome: Fournier's gangrene. J Reconstr Urol. 2024;14(1):30-4.

Correspondence: Mustafa SESLİ

Mersin University Faculty of Medicine, Department of Urology, Mersin, Türkiye

E-mail: Skafasvucut44@gmail.com



Peer review under responsibility of Journal of Reconstructive Urology.

Received: 19 Jan 2024

Accepted: 19 Feb 2024

Available online: 26 Feb 2024

2587-0483 / Copyright © 2024 by Türkiye Klinikleri. This is an open access article under the CC BY-NC-ND license (<http://creativecommons.org/licenses/by-nc-nd/4.0/>).

penis are scarce in the literature, with only a few single case reports reported. A thorough literature search unveiled twenty-one documented cases.^{5,6} Its etiology is no longer considered idiopathic and is generally linked to a pathological process originating from the skin, urinary tract, or colorectal region. NF has been demonstrated to have associations with diabetes, alcohol consumption, human immunodeficiency virus (HIV), and chronic steroid use. These factors contribute to decreased host immunity, allowing microorganisms to enter the perineum.^{7,8} Urogenital causes of NF include urethral strictures, internal catheters, traumatic catheterization, urethral stones, and prostate biopsies. Strictures and stones may manifest with minimal symptoms and can go unnoticed without appropriate examinations. Typically, treatment management involves a multimodal approach, encompassing early aggressive surgical debridement, urinary diversion, and antimicrobial therapy with broad-spectrum antibiotics. Generally, reconstructive surgeries are required after that. This study aims to contribute to the literature with a unique case diagnosed with sepsis secondary to NF due to a urethral stone.

CASE REPORT

A 73-year-old male patient was admitted to the emergency department with complaints of urinary retention, penile swelling, and changes in penile color. He had no history of urinary system stones in himself or his family. There was no known comorbidity and no history of prior surgery. The patient reported experiencing intermittent urinary retention and hematuria in the 5 days leading up to the emergency department visit. Upon physical examination, necrotic areas on the penile skin and subcutaneous crepitus extending to the suprapubic region and globe vesicale were identified (Figure 1). Laboratory results showed elevated serum creatinine (4.56 mg/dL), urea (232.5 mg/dL), C-reactive protein (408.95 mg/L), and procalcitonin (34.88 ng/mL). Sexually transmitted diseases panel tests were negative. Computed tomography revealed bilateral hydronephrosis, severe bladder distension, stone opacity in the mid-penile urethra, and air densities extending to the pelvic inlet in the anterior subcutaneous fat layers of the abdominal wall (Figure 2).

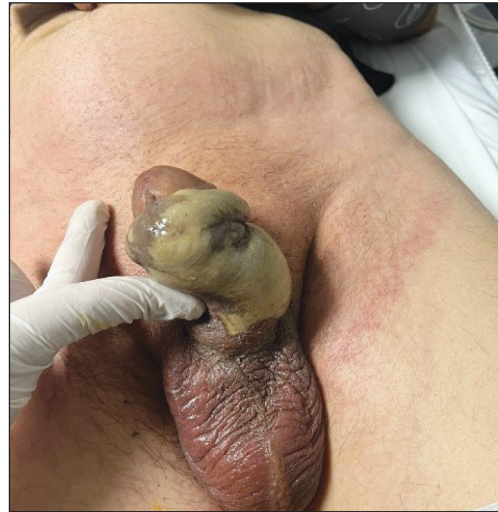

FIGURE 1: Preoperative necrotic penile tissues, suprapubic skin erythema, palpable globe vesicale.

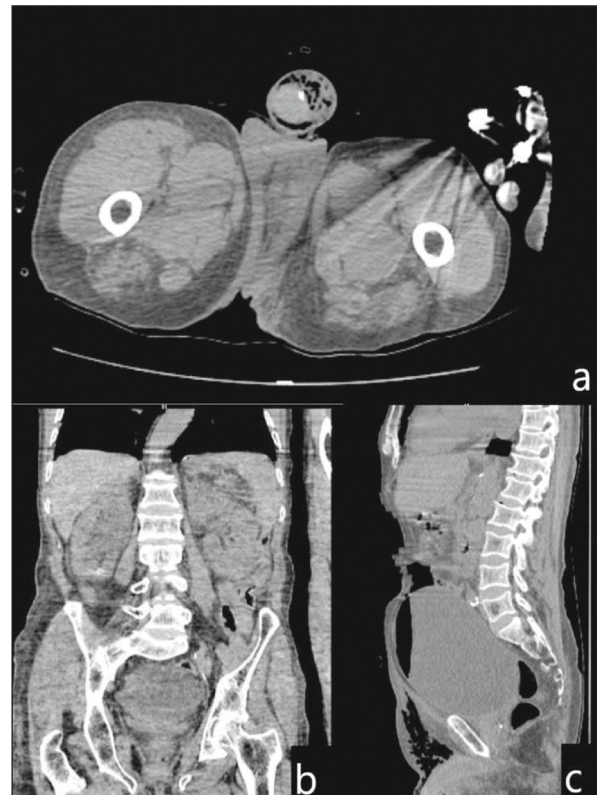


FIGURE 2: Bilateral hydronephrosis, bladder distension, stone opacity in the mid-penile urethra, and air densities in the subcutaneous fat layers of the anterior abdominal wall extending to the pelvic inlet are observed in the axial (a), coronal (b), sagittal (c) views.

The patient was diagnosed with sepsis secondary to NF due to an obstructive urethral stone and with acute kidney failure, and there was no need

for hemodialysis during follow-ups. Broad-spectrum antibiotic treatment (ertapenem and vancomycin) was initiated along with necessary fluid replacement, and an urgent wound debridement was performed. A suprapubic cystostomy catheter was placed before cystourethroscopy, and the urethral stone was fragmented (Figure 3). Necrotic tissues were debrided, revealing compromised integrity of the penile urethra due to NF (Figure 4). Tissue and urine samples were conducted for microbiological and pathological assessment. Histological analysis indicated an inflammatory cell infiltrate rich in polymorphonuclear leukocytes on a necrotic fibrotic background. Extended-spectrum- β -lactamase-producing *Escherichia coli* was isolated from tissue and urine cultures. Following a successful two-week treatment with serial debridements, dressings, and

parenteral antimicrobial therapy, the penile urethral defect was repaired. During the repair of the defect, tubularization of the left tunica vaginalis around an 18F foley urethral catheter resulted in the formation of a neo-urethra. After one month following urethroplasty, once the debridement site was ready for reconstruction surgery, the skin defect was repaired using an anterolateral femoral fasciocutaneous flap (Figure 5). After a two-year follow-up, a complication-free, successful, and satisfactory surgical outcome was obtained. A careful physical examination, appropriate imaging techniques, and a prompt, aggressive surgical intervention ensured successful treatment.

Patient informed consent was obtained to publish his information. The patient's private information remained confidential with the researchers.

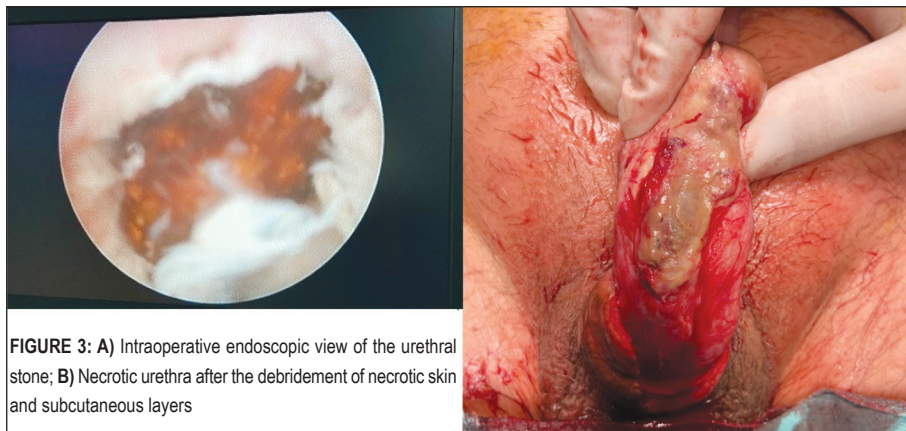


FIGURE 3: A) Intraoperative endoscopic view of the urethral stone; B) Necrotic urethra after the debridement of necrotic skin and subcutaneous layers

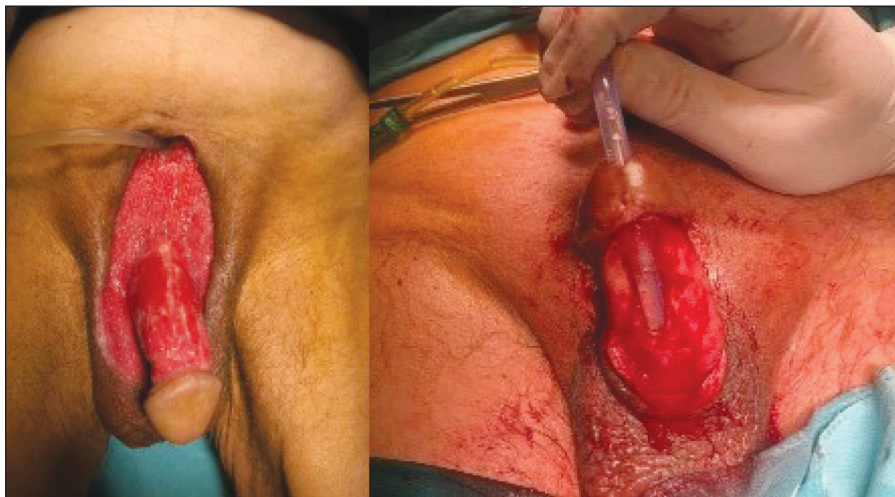


FIGURE 4: Penoscrotal site, urethra, and the suprapubic cystostomy catheter following the debridement.

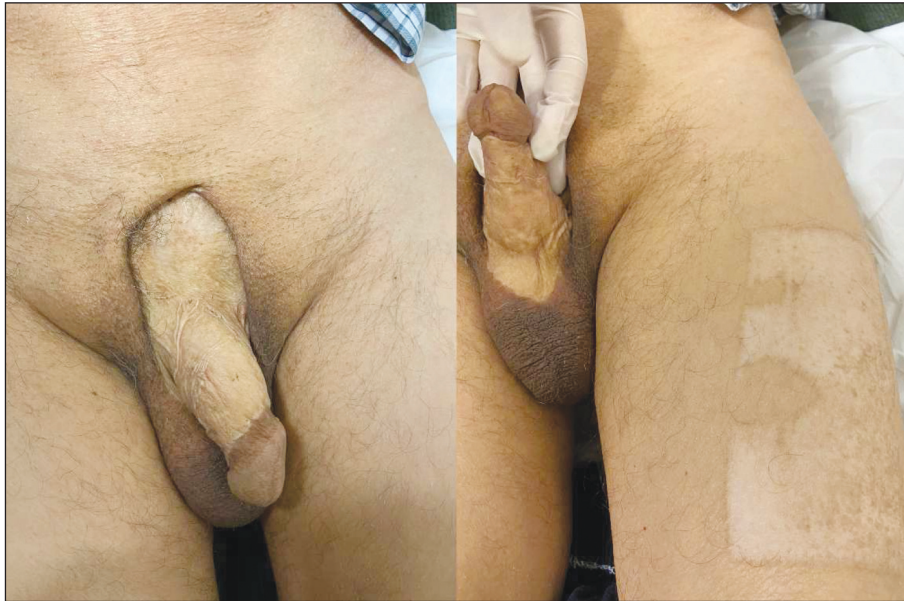

FIGURE 5: Healed penoscrotal debridement site following anterolateral femoral fasciocutaneous flap surgery.

DISCUSSION

As a secondary complication to obstructive urethral stones, FG is a rare occurrence.⁹ Rapid diagnosis and treatment of urethral stones are crucial to prevent such catastrophic complications and their metabolic consequences. In the presence of findings indicating infravesical obstruction, such as suprapubic pain and globe vesicale, the possibility of urethral stones should be considered.

As known from the patient's history, no additional comorbidities are present. In a comprehensive review, similarly, no predisposing factor for NF (such as immunosuppression, diabetes mellitus, HIV, etc.) could be identified etiologically in some patients.² Although NF typically initiates in the scrotum, isolated occurrences such as penile NF, albeit rare, bear no particular significance either etiologically or in terms of treatment.^{2,5,7,10} Moreover, we did not pursue any additional treatment modality specific to this condition in our patient's treatment. The patient, who reported acute-onset penile pain starting 5 days prior, exhibited the most severe necrosis in the penoscrotal tissues, primarily observed on the ventral aspect of the penis, leading us to consider the urethral stone as the likely origin of the current presentation.

We hypothesize that due to the patient's lack of self-care and delay in seeking medical attention, the urethral stone rapidly led to infection and subsequent tissue ischemia, resulting in such a catastrophic scenario. That indicates that the presence of an underlying chronic disease is not mandatory for the development of a condition as severe as FG.

Considering the frequent occurrence of lower urinary tract symptoms, such as difficulty urinating, in similar age groups, it's plausible that the urethral stone might have been overlooked until the patient presented to our facility.

Source of Finance

During this study, no financial or spiritual support was received neither from any pharmaceutical company that has a direct connection with the research subject, nor from a company that provides or produces medical instruments and materials which may negatively affect the evaluation process of this study.

Conflict of Interest

No conflicts of interest between the authors and / or family members of the scientific and medical committee members or members of the potential conflicts of interest, counseling, expertise, working conditions, share holding and similar situations in any firm.

Authorship Contributions

Idea/Concept: Mustafa Sesli; **Design:** Mert Başaranoğlu, Melih Bıyıkoğlu; **Control/Supervision:** Erim Erdem; **Data Collection and/or Processing:** Mustafa Sesli; **Analysis and/or Interpreta-**

tion: Erim Erdem; **Literature Review:** Melih Bıyıkoğlu; **Writing the Article:** Mustafa Sesli; **Critical Review:** Erim Erdem; **References and Fundings:** Mert Başaranoğlu; **Materials:** Mert Başaranoğlu.

REFERENCES

1. Verit A, Savas M, Ciftci H, Unal D, Yeni E, Kaya M. Outcomes of urethral calculi patients in an endemic region and an undiagnosed primary fossa navicularis calculus. *Urol Res.* 2006;34(1):37-40. [[Crossref](#)] [[PubMed](#)]
2. Eke N. Fournier's gangrene: a review of 1726 cases. *Br J Surg.* 2000;87(6):718-28. [[Crossref](#)] [[PubMed](#)]
3. Singam P, Wei KT, Ruffey A, Lee J, Chou TG. Fournier's gangrene: a case of neglected symptoms with devastating physical loss. *Malays J Med Sci.* 2012;19(3):81-4. [[PubMed](#)] [[PMC](#)]
4. Chernyadyev SA, Ufimtseva MA, Vishnevskaya IF, Bochkarev YM, Ushakov AA, Beresneva TA, et al. Fournier's gangrene: literature review and clinical cases. *Urol Int.* 2018;101(1):91-7. [[Crossref](#)] [[PubMed](#)] [[PMC](#)]
5. Obi AO. Isolated Fournier's gangrene of the penis. *Niger J Clin Pract.* 2016;19(3):426-30. [[Crossref](#)] [[PubMed](#)]
6. Schaeffer AJ, Schaeffer EM. Infections of the urinary tract. In: Wein AJ, ed. *Campbell-Walsh Urology.* 10th ed. Philadelphia, PA: Elsevier Saunders; 2012. p.324. [[Crossref](#)]
7. Vyas HG, Kumar A, Bhandari V, Kumar N, Jain A, Kumar R. Prospective evaluation of risk factors for mortality in patients of Fournier's gangrene: A single center experience. *Indian J Urol.* 2013;29(3):161-5. [[Crossref](#)] [[PubMed](#)] [[PMC](#)]
8. Fournier JA. Jean-Alfred Fournier 1832-1914. Gangrène foudroyante de la verge (overwhelming gangrene). *Sem Med* 1883. *Dis Colon Rectum.* 1988;31(12):984-8. [[Crossref](#)] [[PubMed](#)]
9. Bernstein SM, Celano T, Sibulkin D. Fournier's gangrene of the penis. *South Med J.* 1976;69(9):1242-4. [[Crossref](#)] [[PubMed](#)]
10. Rizos S, Filippou DK, Condilis N, Filippou G, Trigka A, Skandalakis P, et al. Fournier's gangrene. Immediate diagnosis and multimodality treatment is the cornerstone for successful outcome. *Ann Ital Chir.* 2005;76(6):563-7. [[PubMed](#)]