

Unilateral Acute Anterior Uveitis Associated with Mediterranean Spotted Fever: Case Report

Akdeniz Benekli Ateşi Hastalığına Eşlik Eden Tek Taraflı Akut Ön Üveit

Ayşe TEKİN BUYRUKCU,^a
Tuğrul ALTAN,^a
Kadir ELTUTAR,^a
Muzaffer FİNCANCI^b

Clinics of
^aOphthalmology
^bMicrobiology,
İstanbul Training and Research Hospital,
İstanbul

Geliş Tarihi/Received: 22.08.2012
Kabul Tarihi/Accepted: 16.10.2012

Yazışma Adresi/Correspondence:
Ayşe TEKİN BUYRUKCU
İstanbul Training and Research Hospital,
Clinic of Ophthalmology, İstanbul,
TÜRKİYE/TURKEY
aysetekinnn@gmail.com

ABSTRACT A 64 years old woman who was hospitalized for high fever, skin rash and malaise was referred to us for blurred vision in her left eye. Vision acuity at presentation was 20/63. She had conjunctival injection, anterior chamber cells (++), posterior synechia, iris pigments over the lens. Fundus examination was normal. Cells were aggregated around a possible fibrin core and were floating in the anterior chamber. History was notable for a tick bite followed by high fevers, skin rashes, fatigue and myalgia. Polymerase chain reaction analysis of skin lesion (tache noire) was positive for *Rickettsia conorii* whereas aqueous humor sample was negative. She was treated with systemic doxycycline (2x100 mg), topical dexamethasone, syclopentolate and phenylephrine. Vision acuity gradually improved to 20/20.

Key Words: *Rickettsia conorii*; uveitis

ÖZET Yüksek ateş, deride kızarıklık ve halsizlik nedeniyle yatırılan 64 yaşında kadın hasta, sol gözünde görme azalması şikayetiyle bize sevk edildi. Başvuruda görme keskinliği 20/63 idi. Konjunktival enjeksiyon, ön kamarada hücre (++), arka sinesi, lens üzerinde iris pigmentleri mevcuttu. Fundus muayenesi normal idi. Hücreler, olası bir fibrin çekirdek etrafında kümelenmişti ve ön kamarada içinde yüzüyordu. Hikayesinde kene ısırmasını takip eden yüksek ateş, deri döküntüsü, yorgunluk ve miyalji saptandı. Aköz hümör örneğinin Polimeraz zincir reaksiyonu analizi negatif iken deri lezyonundan (tache noire) yapılan analizde *Rickettsia conorii* pozitif saptandı. Hasta sistemik doksisisiklin (2x100 mg), topikal dekzametazon, siklopentolat ve fenilefrin ile tedavi edildi. Görme keskinliği kademeli olarak 20/20'e yükseldi.

Anahtar Kelimeler: Riketsiya konori; üveit

Türkiye Klinikleri J Ophthalmol 2013;22(1):68-70

R*ickettsiae* are intracellular Gram-negative coccobacilli. They are usually transmitted to humans via the bite of carrier arthropods, such as ticks. Mediterranean spotted fever (MSF), caused by *Rickettsia conorii*, is endemic in Mediterranean countries and Central Asia whereas Rocky Mountain spotted fever, caused by *R. rickettsii*, is encountered in America.¹

Rickettsial diseases are characterized by high fever, headache, malaise and skin rash. A skin lesion (tache noire) may develop at the site of arthropod bite. The initial clinical presentation of MSF develops after 5-7 day incubation period. Ocular involvement is common in rickettsiosis, but it is

usually asymptomatic and self-limited. Ocular inflammation in a patient with high fever, headache, malaise and skin rash living in or returning from an endemic area during the spring or summer, suggest Rickettsial infection.^{2,3}

Associated ocular conditions include conjunctivitis, keratitis, anterior uveitis, retinal vasculitis, white centered retinal hemorrhages, retinal artery occlusion, retinal vein occlusion, serous retinal detachments, white retinal lesions, cystoid macular edema and macular star: optic nerve involvement. In one third of patients, fluorescein angiographic abnormalities may be seen despite normal fundus appearance.² Retinitis is observed in at least 30% of patients with acute MSF.³ It is usually in the form of white retinal lesions. These lesions usually resolve with or without scarring in several weeks. Optic disc involvement includes optic disc edema, optic neuritis and ischemic optic neuropathy.²

We report here a patient with unilateral anterior uveitis accompanied by Mediterranean spotted fever caused by *Rickettsia conorii*.

CASE REPORT

A 64 year-old woman who had been hospitalized for high fever, skin rash and malaise into Infectious Diseases Department of our hospital 3 days ago was referred for blurred vision in her left eye over a 15 days period. The symptoms including high fever, skin rash, fatigue and myalgia following a tick bite had all started approximately 3 weeks before the present visit. At presentation, visual acuity were 20/63 in the left eye and 20/20 in the right eye.

Slitlamp examination revealed conjunctival injection, anterior chamber cells and flare (++), posterior synechia between 12 and 3 o'clock, iris pigments over the anterior capsule in the left eye (Figure 1). Cells were aggregated around a possible fibrin core and were floating in the anterior chamber. The right eye appeared normal in slitlamp examination. Intraocular pressure was measured 15 mmHg. Fundus examination revealed slight pigmentary changes in both eyes (Figure 2).

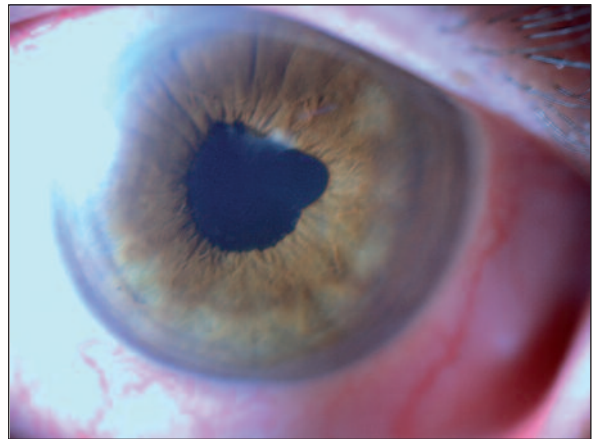


FIGURE 1: Anterior segment photo of the left eye before treatment (anterior chamber cells and flare (++), posterior synechia between 12 and 3 o'clock, iris pigments over the anterior capsule).

(See for colored form <http://oftalmoloji.turkiyeklinikleri.com/>)

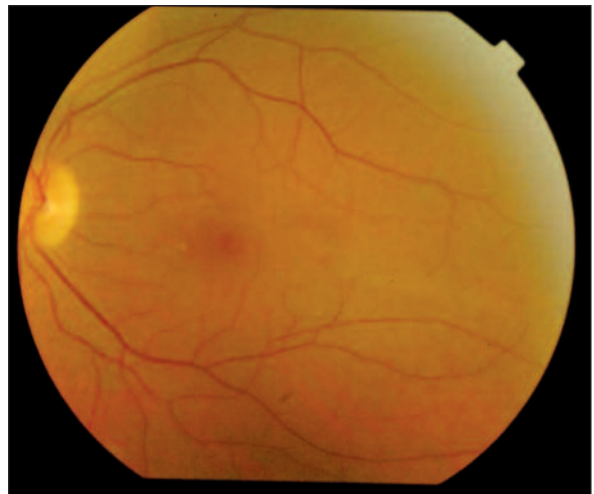


FIGURE 2: Posterior segment photo of the left eye before treatment (slight pigmentary changes).

(See for colored form <http://oftalmoloji.turkiyeklinikleri.com/>)

Laboratory findings were as follows: Number of leukocytes was within the normal range. Blood culture was negative. Liver function tests (ALT, AST) and C-reactive protein were high at initial examination. Polymerase chain reaction (PCR) analysis of skin lesion (tache noire) was positive for *Rickettsia conorii*. Anterior chamber tap was made for the PCR sample. PCR result of aqueous humor was negative.

Systemic doxycycline at a dose of 2x100 mg was given orally over a period of two weeks, along

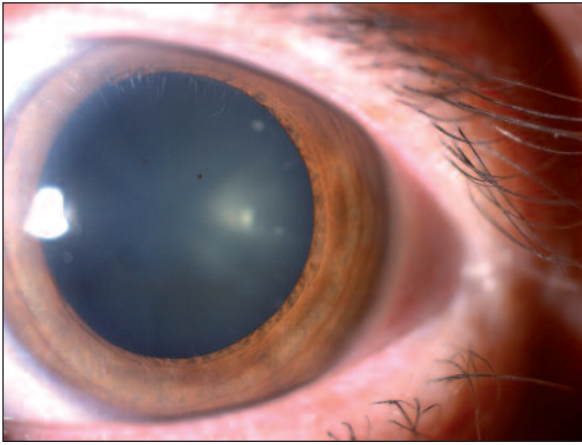


FIGURE 3: Anterior segment photo of the left eye after treatment (improvement in all ocular signs except iris pigments over the anterior capsule). (See for colored form <http://oftalmoloji.turkiyeklinikleri.com/>)

with topical dexamethasone hourly, cyclopentolate 3x1 and phenylephrine 4x1. Phenylephrine was discontinued after the posterior synechiae were broken. In the third week, improvement in all ocular signs was seen except iris pigments over the anterior capsule (Figure 3). Visual acuity gradually improved to 100/100. The patient was followed for three months. There was no pathology during the follow-up period.

DISCUSSION

Retinitis is observed in at least 30% of patients with acute MSF.³ Khairallah et al. stated posterior segment manifestations of *Rickettsia conorii* infection including vitreous inflammation, white retinal lesions, intraretinal hemorrhages, serous retinal detachment, optic disc staining, retinal vascular leakage and hypofluorescent choroidal dots. Posterior segment findings resolved in 3 to 10 weeks in that study.⁴

REFERENCES

1. Kalantri SP, Joshi R, Riley LW. Chikungunya epidemic: an Indian perspective. *Natl Med J India* 2006;19(6):315-22.
2. Khairallah M, Jelliti B, Jenzeri S. Emergent infectious uveitis. *Middle East Afr J Ophthalmol* 2009;16(4):225-38.
3. Simon F, Parola P, Grandadam M, Fourcade S, Oliver M, Brouqui P, et al. Chikungunya infection: an emerging rheumatism among travelers returned from Indian Ocean islands. Report of 47 cases. *Medicine (Baltimore)* 2007; 86(3):123-37.
4. Khairallah M, Ladjimi A, Chakroun M, Messaoud R, Yahia SB, Zaouali S, et al. Posterior segment manifestations of *Rickettsia conorii* infection. *Ophthalmology* 2004;111(3):529-34.
5. Khairallah M, Zaouali S, Ben Yahia S, Ladjimi A, Messaoud R, Jenzeri S. Anterior ischemic optic neuropathy associated with rickettsia conorii infection. *J Neuroophthalmol* 2005;25(3):212-4.
6. Rizo AE, Muñoz O, Auladell C, Miranda ML. A case of bilateral uveitis secondary to Mediterranean spotted fever. *Clin Infect Dis* 1992; 14(2):624-5.
7. Mendivil A, Cuartero V. Endogenous endophthalmitis caused by *Rickettsia conorii*. *Acta Ophthalmol Scand* 1998;76(1):121-2.

Optic disc involvement includes optic disc edema, optic neuritis and ischemic optic neuropathy.² Khairallah et al. presented a case of unilateral acute anterior ischemic optic neuropathy associated with rickettsia conorii infection.⁵

Although posterior segment findings of MSF are more often reported, reports of isolated anterior uveitis are rare.⁶ We present here a case with unilateral nongranulomatous anterior uveitis without any clinically visible posterior segment involvement. As we did not perform fundus angiography during the active course of the disease, we cannot eliminate subclinical posterior segment involvement.

Diagnosis of rickettsial infection is confirmed by positive indirect immunofluorescent antibody test or PCR. We attempted to demonstrate the presence of organisms in the anterior chamber by PCR. But the samples taken from the anterior chamber was negative whereas the sample from tache noire was positive for *Rickettsia conorii*. Intraocular presence of *Rickettsia conorii* antigen was demonstrated previously in a case with endogenous endophthalmitis. Mendivil and Cuartero reported an endogenous endophthalmitis caused by *Rickettsia conorii*.⁷

In conclusion, in patients with ocular inflammation followed by high fever, headache, malaise and skin rash, living in or returning from an endemic area during spring or summer, Rickettsial infection should be kept in mind in the differential diagnosis. Visual prognosis is good with systemic antibiotic and topical antiinflammatory therapy in isolated anterior segment involvement.