

# Investigation of the Levels of Interferon- $\gamma$ and Interleukin-1 $\alpha$ and Inducible Nitric Oxide Synthase-Production in Human Radicular Cysts

## RADİKÜLER KİSTLERDE İNDÜKLENEBİLİR NİTRİK OKSİT SENTAZ ÜRETİMİ VE İNTERFERON- $\gamma$ İLE İNTERLÖKİN-1 $\alpha$ DÜZEYLERİNİN İNCELENMESİ

Buket AYBAR, DDS PhD,<sup>a</sup> Bilgin ÖNER, DDS PhD<sup>a</sup> Haydar DURAK, MD<sup>b</sup>

<sup>a</sup>Department of Oral Surgery, İstanbul University School of Dentistry,

<sup>b</sup>Department of Pathology, İstanbul University Cerrahpaşa Faculty of Medicine, İSTANBUL

### Abstract

**Objective:** The purpose of this study was to determine the percentage of interferon- $\gamma$  (IFN- $\gamma$ ), interleukin-1 $\alpha$  (IL-1 $\alpha$ ) and inducible nitric oxide synthase (iNOS) producing cells in radicular cysts using immunostaining procedures.

**Material and Methods:** Nineteen patients, who were diagnosed with radicular cysts, were subjects in the present study. Inflamed periapical tissues were obtained from patients at the time of surgical treatment. Clinically healthy periodontal ligament tissues were obtained from ten premolars extracted for orthodontic reasons of ten patients. This consisted the control group. Gingival tissues were also obtained from these ten patients. Samples were subjected to immunohistochemical analysis with specific antibodies to IFN- $\gamma$ , IL-1 $\alpha$  and iNOS. The data were analyzed by using Kruskal-Wallis One-Way ANOVA test. Multiple comparisons were done by Newman-Keuls test.

**Results:** iNOS positive cell percentage in radicular cysts was found to be statistically higher than the ones in periodontal ligament tissue ( $p < 0.001$ ) and gingival tissue ( $p < 0.01$ ). IFN- $\gamma$  positive cell percentage in radicular cysts was higher than the one in periodontal ligament tissue ( $p < 0.01$ ).

**Conclusion:** These results suggest that iNOS positive cells are present in a significant percentage in local inflammation sites such as radicular cysts.

**Key Words:** Radicular cysts; nitric oxide

Türkiye Klinikleri J Dental Sci 2007, 13:6-11

### Özet

**Amaç:** Bu çalışmanın amacı, radiküler kistlerde interferon- $\gamma$  (IFN- $\gamma$ ), interlökin-1 $\alpha$  (IL-1 $\alpha$ ) ve indüklenebilir nitrik oksit sentaz (iNOS) düzeylerinin incelenmesidir.

**Gereç ve Yöntemler:** Radiküler kisti olduğu saptanan 19 hasta deney grubunu oluşturmuştur. İnflamasyonlu periapikal doku, cerrahi operasyon esnasında çıkartılmıştır. Kontrol grubu olarak da, 10 hastanın ortodontik amaçla çekilen premolar dişlerinin periodontal ligament dokusu alınmıştır. Ayrıca bu 10 hastanın gingival dokusu da alınmıştır. Örnekler; IFN- $\gamma$ , IL-1 $\alpha$  ve iNOS'a yönelik spesifik antikörlerle immunohistokimyasal işleme tabi tutulmuştur. Veriler, Kruskal-Wallis One-Way ANOVA analiziyle istatistiksel olarak kıyaslanmıştır. Çoklu karşılaştırmalarda ise Newman-Keuls testi uygulanmıştır.

**Bulgular:** Radiküler kistlerde; iNOS pozitif hücrelerin yüzdesi periodontal ligament ( $p < 0.001$ ) ve gingival dokuya ( $p < 0.01$ ) oranla istatistiksel olarak daha yüksek bulunmuştur. Radiküler kistlerde IFN- $\gamma$  pozitif hücrelerin yüzdesi periodontal ligament dokusuna oranla ( $p < 0.01$ ) daha yüksek bulunmuştur.

**Sonuç:** Elde ettiğimiz bulgular, iNOS pozitif hücrelerin radiküler kist gibi lokal inflamasyon bölgelerinde belirgin bir farklılıkla yüksek bulunduğunu göstermiştir.

**Anahtar Kelimeler:** Radiküler kistler, nitrik oksit

Radicular cysts are by far the most common cysts of the jaws. The periapical cyst develops from a preexisting periapical granuloma, which represents a form of chronically in-

flamed granulation tissue in bone at the apex of nonvital teeth. These inflammatory cysts derive their epithelial linings from proliferation of small odontogenic epithelial residues (rests of Malassez) within the periodontal ligament.<sup>1</sup> Available evidence indicates that the development of these cavities in proliferating epithelium may be mediated by immunologic reaction. Activated epithelial cell rests of Malassez can obtain antigenicity or become recognized as antigens and consequently elicit immunologic reactions.<sup>2,3</sup>

Geliş Tarihi/Received: 08.09.2006 Kabul Tarihi/Accepted: 24.01.2007

Bu çalışma İstanbul Üniversitesi Araştırma Fonu tarafından desteklenmiştir. Proje No:1661-3004-2001

**Yazışma Adresi/Correspondence:** Buket AYBAR, DDS PhD  
İstanbul University School of Dentistry,  
Department of Oral Surgery, İSTANBUL  
buketaybar@hotmail.com

Copyright © 2007 by Türkiye Klinikleri

Nitric Oxide (NO) has a variety of biological activities, including the inhibition of neutrophil adhesion to endothelium,<sup>4</sup> the dysfunction of lysosomal enzyme release and a decrease of neutrophil chemotaxis.<sup>5</sup> In addition, it has been demonstrated that NO induces apoptosis<sup>6</sup> and also inhibits mitochondrial respiration and DNA synthesis. Thus, it is thought to modulate inflammation and to induce substantial tissue damage.

NO, first identified as an endothelial-derived relaxing factor, is synthesized from L-arginine by nitric oxide synthase (NOS) and is known to serve various functions. NOS is classified as constitutive NOS (cNOS) and inducible NOS (iNOS).<sup>7-9</sup> Cells that contain cNOS quickly and transiently produce small amounts of NO in response to agonists which raise intracellular Ca<sup>2+</sup> concentrations, while cells with iNOS produce large amounts of NO for a prolonged period following a lag of several hours during which the enzyme is induced.<sup>10</sup> Chondrocytes, synoviocytes, macrophages and polymorphonuclear leukocytes<sup>11</sup> have inducible forms of NOS. iNOS is more remarkable than cNOS because it can induce a large amount of NO with appropriate stimulation.<sup>5</sup>

The expression of iNOS is stimulated by several cytokines such as interleukin 1 $\alpha$  (IL-1 $\alpha$ ), tumor necrosis factor- $\alpha$  (TNF- $\alpha$ ) and interferon  $\gamma$  (IFN- $\gamma$ ). IFN- $\gamma$  enhances the expression of iNOS induced by IL-1 $\alpha$  or TNF- $\alpha$ , whereas IL-4, IL-10 and transforme growth factor  $\beta$  (TGF- $\beta$ ), inhibit the induction of iNOS.<sup>7,12-14</sup> These cytokines play a crucial role in immune and inflammatory responses.

The purpose of the present study was to determine the percentages of iNOS, IFN- $\gamma$  and IL-1 $\alpha$  producing cells in radicular cysts using immunostaining procedures.

### Material and Methods

40 adult patients with radiographic evidence of periapical alveolar bone loss were referred to Istanbul University, Faculty of Dentistry Dept. of Oral Surgery. Of the 40 histologically examined periapical lesions 19 were characterized as radicular cysts and utilized for immunostaining. Of these

19 patients 11 were male and 8 female. The mean age of patients was 38 years. None of the patients were taking any drugs; analgesics or anti-inflammatory drugs, and they did not suffer from systemic diseases. Inflamed tissues of the periapical lesions were removed at the time of surgery. Clinically healthy periodontal ligament tissues were obtained from 10 premolars extracted for orthodontic reasons of 10 patients. This consisted the control group. Five of these patients were male and 5 female. Gingival tissues were also obtained from these 10 patients who had no gingivitis or periodontal disease. Written consents were obtained from all patients prior to the collection of samples.

Histological and immunohistochemical examinations were performed on surgically removed samples of periapical lesions, periodontal ligaments and gingival tissues. Immediately after obtaining the tissues, they were cut into 2 halves. One half was fixed with buffered formalin and then embedded in paraffin. The other half was fixed with acetone and embedded in a compound to freeze at the optimum cutting temperature (OCT compound, Tissue-Tek, Elkhort, IN, USA). Paraffin and cryostat sections of 4- $\mu$ -thick, were then prepared. Nine sections of each fixed specimen were serially cut from the center of the tissue. Paraffin sections were subjected to haematoxylin-eosine staining and evaluated histologically using a light microscope (Olympus BX-50 microscope, Japan).

Frozen serial sections from periapical, periodontal ligament and gingival tissues were mounted on 3-aminopropyl-triethoxy-silane-coated (Sigma Chemical Co., St.Louis, MO. USA) glass slides in a cryostat, and then air dried for 30 min at room temperature (RT) and processed for indirect immunohistochemistry. NOS2 (H-174) cat # sc-8310, Lot # C290 rabbit polyclonal IgG (Santa Cruz Biotechnology, Inc USA), IL-1 $\alpha$  (c-18) cat # sc - 1253, Lot # D061 goat polyclonal, Ig G 200  $\mu$ g/ ml (Santa Cruz Biotechnology, Inc USA), IFN- $\gamma$  (c-19) cat # sc-1377, Lot # J180 goat polyclonal IgG (Santa Cruz Biotechnology, Inc USA), were obtained from appropriate companies.

Every 3 sections were immunohistochemically stained by human iNOS, human IFN- $\gamma$  and IL-1 $\alpha$ . Briefly, the sections were fixed with acetone for 10 min at RT. Then the sections were washed with phosphate buffered solution (PBS) for 5 min. The staining procedures were performed in a humidity chamber according to the manufacturer's recommendation. Finally the sections were incubated with AEC for 5-15 min washed with water, counterstained with haematoxylin and closed with glycerin gel.

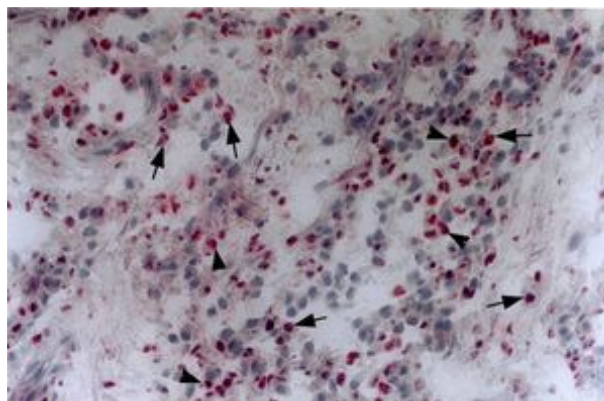
Positive cells (iNOS, human IFN- $\gamma$  and IL-1 $\alpha$ ) were counted under the microscope using x 40 objective and x 10 ocular lenses by the same pathologist. The percentages of the positive inflammatory cells in a 100 stained and unstained inflammatory cells in all areas were determined. Lymphocytes, neutrophils, macrophages and plasmocytes in at least 5 high-power fields per section were counted. Then the mean percentages of positive cells were determined from the percentages obtained from 15 areas of 3 sections. Data didn't show normally distribution. Because of this non parametric test was preferred. The data were analyzed by using Kruskal-Wallis One-Way ANOVA test. Multiple comparisons were done by Newman-Keuls test.

## Results

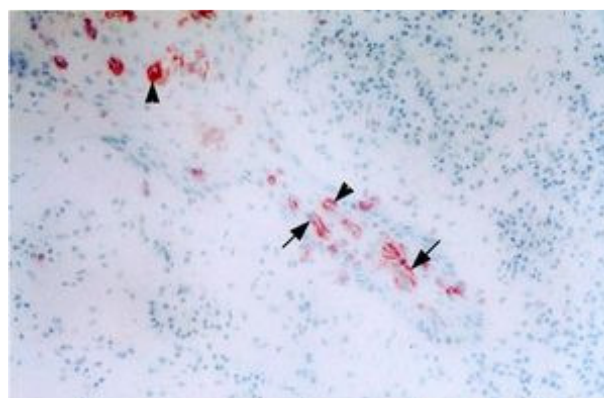
In periapical-inflamed tissues, polymorphonuclear leukocytes and mononuclear cells also showed iNOS reactivity (Figure 1). Epithelial cells, endothelial cells and fibroblasts were significantly stained with iNOS antibodies (Figure 2). Some lymphocytes showed iNOS synthesis but some did not. Cells adjacent to blood vessels showed significant iNOS synthesis whereas cells away from the blood vessels showed weak or no iNOS synthesis.

IL-1 $\alpha$  and IFN- $\gamma$  (Figure 3) producing cells were localized in all samples of radicular cysts.

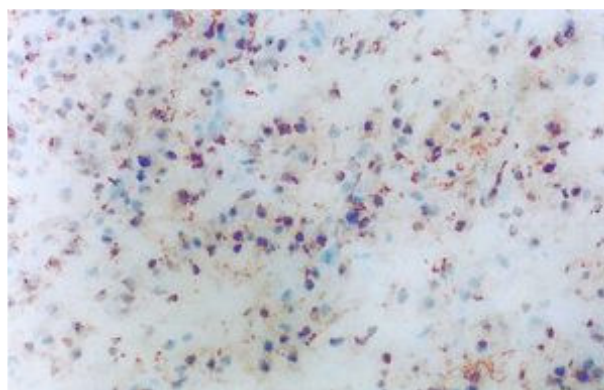
Microscopic analysis for IFN- $\gamma$  revealed that IFN- $\gamma$  producing cells were lymphocyte-like mononuclear cells. In addition, we found nearly same ratios IFN- $\gamma$  producing cells and iNOS positive cells on the sections of the same tissues.



**Figure 1.** Immunohistochemistry showing iNOS production of cells in radicular cysts. Arrowheads [from a sample with a high positive cell percentage] show iNOS producing cells (original magnification x 400).



**Figure 2.** Immunohistochemistry showing iNOS production in epithelial cells of the radicular cysts. Arrowheads show iNOS producing cells (original magnification x 200).



**Figure 3.** Immunohistochemistry showing IFN- $\gamma$  production of cells in radicular cysts [from a sample with a high positive cell percentage] (original magnification x 400).

In the gingival tissues positive cells for all of the reactants were much less in percentage than those in the periapical tissues. The percentages of IFN- $\gamma$  positive cells were higher than the other two antibodies.

In periodontal ligament specimens IFN- $\gamma$  and IL-1 $\alpha$  producing cells, and iNOS-positive cells could not be detected.

In the sections of some patients numerous iNOS, IL-1 $\alpha$  and IFN- $\gamma$  positive cells were observed while a few positive cells were detected in the sections of other patients.

Immunohistochemical staining revealed that immunoreactive iNOS was significantly synthesized by a variety of cells. Mononuclear cells, exhibited immunoreactivity to iNOS. iNOS reactivity was also observed in the epithelial tissue. Cells adjacent to blood vessels showed significant iNOS synthesis whereas cells away from the blood vessels showed weak or no iNOS synthesis.

The mean percentages and standard deviations of cytokine-producing cells and iNOS-positive cells in the sample of periapical, periodontal ligament and gingival tissues are summarized in Table 1. iNOS positive cell percentage in radicular cysts was found to be statistically higher than the ones in periodontal ligament tissue ( $p < 0.001$ ) and gingival tissues ( $p < 0.01$ ). The results demonstrated that IFN- $\gamma$  positive cell percentage in radicular cysts was higher than periodontal ligament tissues ( $p < 0.01$ ).

### Discussion

The pathways associated with local inflammation accompanied by periapical osteoclastic resorp-

tion are poorly understood, but certain factors, including cytokines and NO are considered to be responsible for mediating periapical tissue destruction. Its destruction may be owing to the presence of antigenic epithelium.<sup>2,15</sup> Because of its short life, NO may not diffuse far from the site of NO production in inflamed tissues. NO should be synthesized locally to be involved directly in the pathology and biochemistry of periapical lesions. Therefore, it is consistent with a hypothesis, suggesting that NO-producing cells could play a pivotal role in inflamed tissues.

Takeichi et al<sup>5</sup> found that polymorphonuclear leucocytes and mononuclear cells were immunoreactive for iNOS. Epithelial cells, endothelial cells and fibroblasts were also reactive for iNOS antiserum. Cells around the blood vessels showed significant staining with iNOS. While cells far from the vessels revealed weak or no iNOS synthesis. They also stated that IFN- $\gamma$  producing cells were mainly lymphocytes. Similar results were observed in our study.

In this study, iNOS reactivity in radicular cysts was found to be statistically significantly higher than the iNOS reactivity in the periodontal ligament and gingival tissues. These findings were consistent with Kabashima et al.<sup>7</sup>

IFN- $\gamma$  producing cells, IL-1 $\alpha$  producing cells and iNOS positive cells could not be detected in periodontal ligament specimens. Thus in the present study IFN- $\gamma$  reactivity was found to be significantly higher in radicular cyst cells when compared with the periodontal ligament cells. Our results are in compliance with findings in a study by Kabashima et al.<sup>7</sup>

**Table 1.** The percentages of positive cells in radicular cysts, gingival tissue and periodontal ligament.

	iNOS (% mean $\pm$ SD)	IL -1 $\alpha$ (% mean $\pm$ SD)	IFN- $\gamma$ (% mean $\pm$ SD)
Periodontal ligament tissues (n= 10) (Control group)	0 $\pm$ 0 *	0 $\pm$ 0	0 $\pm$ 0 <sup>⊗</sup>
Gingival tissues (n= 10) (Control group)	0.39 $\pm$ 0.74 #	0.29 $\pm$ 0.55	1.29 $\pm$ 2.06
Radicular cyst tissues (n= 19) (Experimental group)	4.13 $\pm$ 3.39 *#	1.07 $\pm$ 1.79	3.13 $\pm$ 2.78 <sup>⊗</sup>

Kruskal-Wallis One-Way ANOVA test, Newman-Keuls test (Multiple comparisons), \*  $p < 0.001$ ; #  $p < 0.01$ ; <sup>⊗</sup>  $p < 0.0$

In our study, when IL-1 $\alpha$  reactivity was correlated in the cells of the periapical, gingival and periodontal ligament tissues; no statistically significant results could be obtained. Lowik et al<sup>16</sup> and Ralston et al<sup>12</sup> found that IFN- $\gamma$ , when combined with TNF- $\alpha$  or IL-1, superinduces iNOS expression in a variety of cells. It seems that IL-1 $\alpha$  is not the only inducer in iNOS reactivity. In fact TNF- $\alpha$  and some endotoxins may play the same role.<sup>13,16</sup>

iNOS and IFN- $\gamma$  reactivity were not similar in all patients. The great degree of variability among the specimens of different patients were thought to be due to personal immunological differences.

Recently, Sakurai et al<sup>17</sup> have shown that synovial cells isolated from rheumatoid arthritis patients produce significant levels of NO. Interestingly, NO has been implicated in the immune rejection of allografted organs and in graft-versus-host disease.<sup>18</sup> Thus, NO may be involved in tissue damage in chronic inflammation. It is possible that similar mechanisms may be associated with periodontal disease. We concluded that the biological activities of NO may have an important role in the regulation and the delicate balance of the periapical lesions caused by chronic inflammation with bacterial infection in addition to humoral and cellular events that interact in this process. These concepts could lead us to improved pharmacological therapy of periapical periodontitis.

The aminoacid L-arginine was shown to be the precursor for the synthesis of NO, and endothelial cells cultured in the absence of L-arginine for 24 h showed a decrease in the release of NO.<sup>19</sup> This reaction would be restored by L-but not D arginine,<sup>20</sup> suggesting that the conversion of L-arginine to NO is specific. Thus, L-arginine analogue could be used as an inhibitor of the generation NO in stimulated inflammatory cells. It has been shown that the onset of experimentally induced rheumatoid arthritis, an autoimmune disease, was blocked by N<sup>G</sup>-monomethyl-L-arginine, an L-arginine analogue.<sup>21</sup> On the basis of this published evidence, it is hypothesized that an NO inhibitor could be applied as a pharmacological therapy for periapical lesions.

After endodontic surgery, recall evaluations to assess long-term healing are important. Same failures can occur.<sup>22</sup> In order not to have such recurrent cases, additional management with NO inhibitors to surgical intervention can be considered.

## Conclusions

We believe that pharmacological therapy can also be applied as a supportive treatment, and we suggest that NO inhibitors can be applied in root canals as a treatment for periapical lesions. These agents may be injected through the root canals during the operation, before the filling procedure.

## REFERENCES

1. Regezi AJ, Sciubba JJ: Oral Pathology/Clinical Pathologic Correlation. 3<sup>rd</sup> ed. Philadelphia: Pennsylvania, WB Saunders Company 1999, p.288-91
2. Torabinejad M: The role of immunological reactions in apical cyst formation and the fate of epithelial cells after root canal therapy: a theory. *Int J Oral Surg* 12:14-22, 1983
3. Torabinejad M, Walton ER: Periradicular lesions. Endodontics. (Eds. Ingle JJ, Bakland KL) London, BC Decker Inc: 2002. p.183
4. Kubes P, Suzuki M, Granger DN: Nitric oxide: an endogenous modulator of leukocyte adhesion. *Proc Natl Acad Sci USA* 88:4651-5, 1991
5. Takeichi O, Hayashi M, Tsurumachi T, et al: Inducible nitric oxide synthase activity by interferon-gamma-producing cells in human radicular cysts. *Int Endod J* 32: 124-30, 1999
6. Albina JE, Cui S, Mateo RB, et al: Nitric oxide-mediated apoptosis in murine peritoneal macrophages. *J Immunol* 150: 5080-5, 1993
7. Kabashima H, Nagata K, Maeda K, et al: Interferon-gamma-producing cells and inducible nitric oxide synthase-producing cells in periapical granulomas. *J Oral Pathol Med* 27: 95-100, 1998
8. Moncada S, Palmer RM, Higgs EA. Nitric oxide: physiology, pathophysiology, and pharmacology. *Pharmacol Rev* 43: 109-42, 1991
9. Nathan C, Xie QW: Regulation of biosynthesis of nitric oxide. *J Biol Chem* 269: 13725-8, 1994
10. Xie QW, Cho HJ, Calaycay J et al: Cloning and characterization of inducible nitric oxide synthase from mouse macrophages. *Science* 256: 225-8, 1992
11. Hibbs JB Jr, Taintor RR, Vavrin Z et al. Nitric oxide: a cytotoxic activated macrophage effector molecule. *Biochem Biophys Res Commun* 157: 87-94, 1988
12. Ralston SH, Todd D, Helfrich M et al: Human osteoblast-like cells produce nitric oxide and express inducible nitric oxide synthase. *Endocrinology* 135: 330-6, 1994
13. Ralston SH, Ho LP, Helfrich MH et al: Nitric oxide: a cytokine-induced regulator of bone resorption. *J Bone Miner Res* 10: 1040-9, 1995

14. Ding A, Nathan CF, Graycar J et al: Macrophage deactivating factor and transforming growth factors-beta 1 -beta 2 and -beta 3 inhibit induction of macrophage nitrogen oxide synthesis by IFN-gamma. *J Immunol* 145: 940-4,1990
15. Bhaskar SN: Nonsurgical resolution of radicular cysts. *Oral Surg* 34: 458,1972
16. Lowik CW, Nibbering PH, van de Ruit M et al: Inducible production of nitric oxide in osteoblast-like cells and in fetal mouse bone explants is associated with suppression of osteoclastic bone resorption. *J Clin Invest* 93: 1465-72, 1994
17. Sakurai H, Kohsaka H, Liu MF et al: Nitric oxide production and inducible nitric oxide synthase expression in inflammatory arthritides. *J Clin Invest* 96: 2357-63, 1995
18. Hoffman RA, Langrehr JM, Billiar TR et al: Alloantigen-induced activation of rat splenocytes is regulated by the oxidative metabolism of L-arginine. *J Immunol* 145: 2220-6, 1990
19. Palmer RM, Ashton DS, Moncada S: Vascular endothelial cells synthesize nitric oxide from L-arginine. *Nature* 333: 664-6, 1988
20. Billiar TR, Hoffman RA, Curran RD et al: A role for inducible nitric oxide biosynthesis in the liver in inflammation and in the allogeneic immune response. *J Lab Clin Med* 120: 192-7,1992
21. Stefanovic-Racic M, Meyers K, Meschter C et al: N-monomethyl arginine, an inhibitor of nitric oxide synthase, suppresses the development of adjuvant arthritis in rats. *Arthritis Rheum* 37: 1062-9,1994
22. Walton ER. Principles of endodontic surgery. *Oral and Maxillofacial Surgery*. (Eds. Peterson LJ) Philadelphia, Mosby 1998, pp: 451-52.