

Management of Uncommon Neck and Axillary Lipoblastomas in Children

Çocuklarda Nadir Boyun ve Koltuk Altı Lipoblastomlarının Yönetimi

^{id} Fatih AKOVA^a, ^{id} Emrah AYDIN^b, ^{id} Murat BİNAR^c

^aDepartment of Pediatric Surgery, Biruni University Faculty of Medicine, İstanbul, TURKEY

^bDepartment of Pediatric Surgery, Koç University Faculty of Medicine, İstanbul, TURKEY

^cClinic of Otorhinolaryngology, Medicana International İstanbul Hospital, İstanbul, TURKEY

This study was presented as orally in INSAC-Natural and Health Sciences 2020 (Online Presentation), 22-23 May 2020, Turkey.

ABSTRACT Objective: Lipoblastomas are benign tumors developing from embryonic fat tissue with few cases reported in the head and neck region. Herein, we aim to present the management of a rare type of lipoblastoma in childhood. **Material and Methods:** A retrospective chart review was performed on all patients who were admitted due to a mass in the neck and axillary region between January 2015 and December 2019. Data were collected on demographics, comorbidities, preoperative characteristics, operative interventions, and postoperative complications and outcomes. The patients with lipoblastoma were further analyzed. **Results:** There were 52 patients operated on due to a mass in the neck or axillary region during the study time. The mean age was 5.42±4.16. The majority of the patients (40/52) were diagnosed with enlarged lymph nodes of which 32 (80%) were diagnosed with lymphoma. Among these populations, only two (3.8%) of them were diagnosed with lipoblastoma. Both cases were asymptomatic other than a painless mass. The histopathological examination confirmed the diagnosis of lipoblastoma after surgical excision. Both cases have been uneventful for four years postoperatively. **Conclusion:** In conclusion, lipoblastomas emerge as a slowly growing mass in early childhood and are mostly seen on the trunk and extremities. Although benign, they have the potential to increase in size and invade adjacent tissues. The gold standard treatment is complete surgical excision. Due to the possibility of recurrence, regular follow-up is strongly recommended after surgery.

ÖZET Amaç: Lipoblastom, embriyonik yağ hücrelerinden köken alan iyi huylu bir tümördür. Baş-boyun bölgesinde bildirilen vaka sayıları sınırlıdır. Bu çalışmada, nadir yerleşimli lipoblastoma yaklaşımı literatür ışığında sunmayı amaçladık. **Gereç ve Yöntemler:** Kliniğimize Ocak 2015 ve Aralık 2019 yılları arasında boyun ve koltuk altı bölgesinde şişlik ile başvuran hastaların dosyaları geriye dönük olarak incelendi. Olguların demografik özellikleri, eşlik eden hastalıkları, ameliyat bulguları, komplikasyonları ve son durumları belirlendi. Bu olgular arasında lipoblastom tanısı alanlar detaylı olarak analiz edildi. **Bulgular:** Belirtilen dönemde boyun ve koltuk altı bölgesinde şüpheli lezyon ile yaş ortalaması 5,42±4,16 yıl olan 52 hasta başvurdu. Hastaların büyük çoğunluğunda (40/52) büyümüş lenf nodu mevcuttu ve bu hastaların 32 (%80)'si lenfoma tanısı aldı. Bu hastalardan sadece 2 tanesi (%3,8) lipoblastom tanısı aldı. Her 2 olguda da başvuru anında ana şikâyet ağrısız büyüyen şişlik idi. Cerrahi eksizyon sonrası yapılan histopatolojik inceleme ile lipoblastom tanısı doğrulandı. Erken dönemde komplikasyon gözlenmeyen her 2 olgu da postoperatif 4. yılda sorunsuz takip edilmektedir. **Sonuç:** Lipoblastom, çocukluk çağında ağrısız büyüyen, çoğunlukla gövde ve ekstremiteleri tutan bir lezyondur. İyi huylu olmasına rağmen büyüme ve çevre dokulara invaze olma eğilimindedir. Cerrahi olarak çıkarılması tedavide altın standarttır. Nüks etme ihtimali nedeni ile uzun süreli takip önerilmektedir.

Keywords: Lipoblastoma; childhood; head and neck; axillary; recurrence

Anahtar Kelimeler: Lipoblastom; çocuk; baş boyun; koltuk altı; nüks

Lipoblastoma is a benign mesenchymal tumor with the lipomatous origin of subcutaneous fat tissue. It's mostly seen in children under 3 years old where the majority of the cases are during infancy.¹⁻³ In childhood, the main presenting symptom is a growing mass.⁴ Although the tumor itself is benign and does

not necessarily metastasize, it has a tendency to invade deeper tissues. Lipoblastoma is classified as benign adipocytic tumors, along with lipomas, lipomatosis, lipoblastomatosis, angiolipomas, and myolipomas. If incompletely resected, the local recurrence rate is quite high which is almost 80%.^{5,6}

Correspondence: Emrah AYDIN

Department of Pediatric Surgery, Koç University Faculty of Medicine, İstanbul, TURKEY/TÜRKİYE

E-mail: dremrahaydin@yahoo.com



Peer review under responsibility of Türkiye Klinikleri Journal of Pediatrics.

Received: 31 May 2020

Received in revised form: 02 Jan 2021

Accepted: 23 Jan 2021

Available online: 15 Feb 2021

2146-8990 / Copyright © 2021 by Türkiye Klinikleri. This is an open access article under the CC BY-NC-ND license (<http://creativecommons.org/licenses/by-nc-nd/4.0/>).

Therefore, complete resection is crucial in the management of these patients. The macroscopic appearance of the lesion is pale yellow and myxoid cut surface with small cystic foci while microscopically it has lobules that are constituted of immature adipose tissue divided by fibrous septa. Lipoblasts are in different stages and they don't have atypia or mitoses; plexiform capillary network and mature adipose tissue are seen in the central part of the lobules.^{7,8} There are 85 cases reported in childhood whereas only 5 cases were reported up to date in the head and neck region.^{9,10} Herein, we aim to present the management of a rare type of lipoblastoma in childhood.

MATERIAL AND METHODS

Following approval by the Non-interventional Researches Ethics Committee of Biruni University with number 2020/40-12 on 28.05.2020 and consent by the parents, data was assembled through an institutional database and augmented with the electronic medical record for the hospital. The study was conducted per the principles of the Helsinki Declaration. A retrospective chart review was performed on all patients who were admitted due to a mass in the neck and axillary region and necessitate surgery between January 2015 and December 2019. Data were collected on demographics, comorbidities, preoperative characteristics, operative interventions, and postoperative complications and outcomes. The patients with lipoblastoma were further analyzed.

RESULTS

There were 52 patients operated on due to a mass in the neck or axillary region during the study time. The

mean age was 5.42 ± 4.16 . The majority of the patients (40/52) were diagnosed with enlarged lymph nodes of which 32 (80%) were diagnosed with lymphoma. Among these patients, only two (3.8%) of them were diagnosed with lipoblastoma.

The first patient was an 11-month-old girl admitted with a history of swelling in the right side of her neck. The patient was asymptomatic otherwise and the physical examination was normal. Ultrasonography (US) revealed a 5x2 cm hyperechogenic solid lesion at the posterior cervical region while the computerized tomography (CT) scan showed a multi-lobulated fatty intense lesion with non-homogeneous soft tissue that was 4,5x3 cm in size and located at the posterior border of sternocleidomastoid (SCM) muscle. The preoperative diagnosis was suggestive of a lipoma or lipoblastoma (Figure 1).

The surgery was performed under general anesthesia and it was uneventful. A transverse cervical incision through the posterior border of the SCM muscle was used to reach the lesion. The lesion was dissected from the surrounding internal jugular vein and esophagus. Macroscopically, the tumor was found 7x4 cm in size (Figure 2). A minivac drain was placed which was removed on the second postoperative day prior to discharge. The histopathologic examination revealed a lesion with solid areas and myxoid degeneration with multi-lobules. No mitosis or necrosis could be shown. She has been free of symptoms in the last four years.

The second patient was a 1-year old boy with a painless right anterior axillary swelling. The CT scan demonstrated a fatty intense encapsulated lesion with a partial soft tissue in it. The lesion was 51x30x52

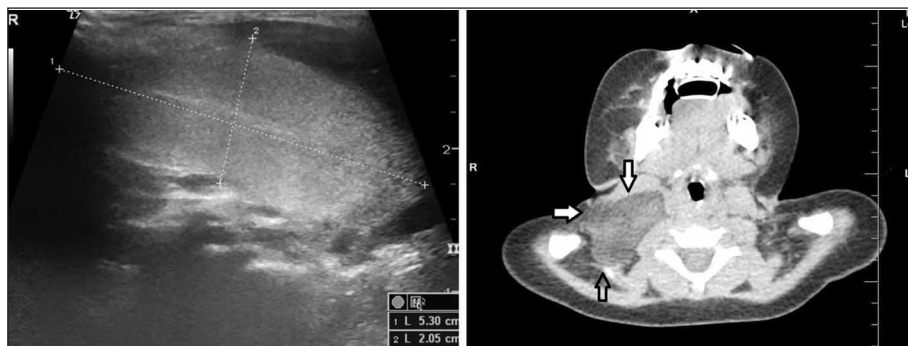

FIGURE 1: The preoperative work-up that demonstrates the lesion on the right side of the neck by ultrasonography on the right and computerized tomography on the left.

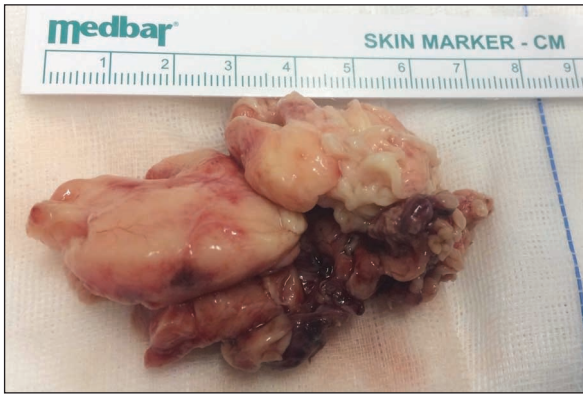

FIGURE 2: The macroscopic view of the lesion postoperatively.

mm in size and a lipoblastoma was suspected (Figure 3). The surgery was performed under general anesthesia. A parallel incision to the skin lines was performed and the lesion was identified just beneath and dissected meticulously. The lesion was very close to axillary vessels and nerve bundles. Macroscopically, the tumor was 6x6 cm. A minivac drain was placed which was removed on the second postoperative day prior to discharge. The histopathologic examination revealed a lesion that had more solid areas compared to lipoma and had lipoblasts showing myxoid degeneration with multi-lobules. No mitosis or necrosis could be shown. He has been free of any symptoms in the last four years.

DISCUSSION

The term *lipoblastoma* has been first used by Jaffe in 1926. Lipoblastomas are rare tumors of fetal fat tis-

sue that are always benign and seen mostly in infancy and early childhood. They arise within the adipose tissue and contain different stages of fat cells ranging from immature lipoblasts to mature adipocytes. Of all childhood neoplasms, they account for less than 1%.¹¹ Most of the reports suggest a slight male predominance.¹² Clinical presentation is only a slowly growing painless soft tissue mass in most of the cases. However, mass effect and pressure on neural structures can result in more severe complaints. Traditionally, it is mostly encountered on the extremities (30-70%) and trunk (20-50%) in children.¹³ Other reported locations are parotid gland, eyelid, tonsillar fossa, retropharyngeal space, cheek, skin, orbit, mediastinum, retroperitoneum, heart, lung, groin, mesentery, omentum, scrotum, labia, axillary, inguinal, and perineal regions.¹⁴⁻¹⁷

Macroscopically, lipoblastomas are soft gelatinous mass lesions in multi-lobules, pale yellow, brownish or tan in color, with the myxoid cut surface of small cystic foci.¹⁸ In the histological examination, lobules separated by fibrous septa composed of immature and mature lipoblasts in different stages without atypia or mitosis, plexiform capillary network, mesenchymal cells, and myxoid stroma are seen.¹⁹

In the differential diagnosis, lipoma, hibernoma, lymphangioma, rhabdomyosarcoma, fibrous hamartoma, and well-differentiated liposarcoma should be considered.^{14,20} True lipomas on imaging show similar characteristics as subcutaneous fat tis-

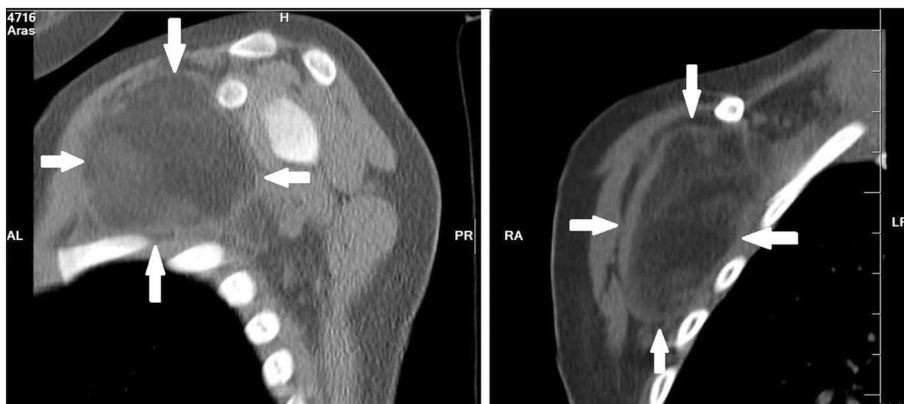


FIGURE 3: The preoperative workup that demonstrates the lesion on the right side of the neck by computerized tomography.

sue and may include a few thin septa.²¹ On imaging, it is very difficult to distinguish lipoblastoma from myxoid liposarcoma. In such a situation, the age of the patient should be considered for clinical diagnosis since liposarcomas are very rare in children less than 10 years of age. Therefore, a fat originated lesion with non-lipomatous components in patients less than 3 years old is most probably a lipoblastoma.^{15,22} When the histopathologic analysis is not enough in difficult cases, cytogenetic analysis can be requested for correct diagnosis.^{23,24} The rearrangements of the chromosomal region 8q11-q13 and the upregulation of the target gene PLAG1 are diagnostic for lipoblastoma. On the other hand, a distinctive translocation t (12; 16) is observed in myxoid liposarcoma.^{14,24,25}

The magnetic resonance imaging (MRI), CT, and US are used in the certain and differential diagnosis of the tumor. Of those, MRI is the most beneficial imaging method for the evaluation of tumor extension and surgical planning.¹⁸ The tumor in MRI is recognized as a hypointense lesion on T1 scans compared to subcutaneous fat because of its content of immature adipose cells. The intensity of MRI can change according to the maturity of lipoblastoma. Although hypointensity in early T1-weighted images and hyperintensity in T2-weighted images are observed, the T1-weighted images become hyperintense with maturity. Besides, differing from subcutaneous fat, the hyperintensity continues with fat-suppression.^{17,26} Fat-saturated T1-weighted images can show a lesion with central enhancement surrounded by a fat-suppressed hypodense peripheral rim. The contrast-enhanced CT scans can show a lesion largely containing fatty tissue surrounded by a vessel-like structure running through the mass with a central portion of higher density.

The best treatment method, widely accepted by many authors, is surgical excision. The main difficulty during the surgery depends on the lesion's invasion of facial planes. Although the tumor is benign and does not metastasize, it shows a tendency to make invasion deeper tissues. This situation makes the surgery challenging, especially in the head and neck region. Even though the traditional approach has

been a complete resection of the tumor for many years, some authors also suggest that incomplete but near-total excision can be preferred to avoid tissue mutilation in difficult cases.^{15,16,26,27} Since the cases are mostly under 3 years old and the tumor is localized, one may prefer a more conservative surgery. To the best of our knowledge, spontaneous regression of lipoblastoma has only been reported in one case previously. Mognato et al. reported a spontaneously resolved congenital diffuse lipoblastoma on a 2-day-old boy's left thigh after their 1-year follow-up with MRI.²⁸ However, considering the rapid growth rate in many patients, expectant management is not always feasible, and thus conservative surgical excision is the mainstay of the therapy.¹² Moreover, the tumor can reach larger sizes when not resected. To keep surrounding structures uninjured, complete resection should not be delayed too far.²⁹

After the initial surgery, especially in case of incomplete excision, up to 25% recurrence is reported. For this reason, regular follow-up is important after the first surgery. The average period for recurrence seems to be 3 years.²⁷ However, recurrences can occur as late as 10 years after the first surgical excision.¹² Re-excision becomes the treatment of choice in recurrence.^{12,30} In all cases presented here, surgical excision was performed, and the postoperative course was uneventful. Both cases are free of symptoms on the postoperative follow-up after four years. The location of the tumor also affects the re-operation possibility. Nagano et al. reported that 9 out of 19 (47%) mesenteric lipoblastoma cases needed additional bowel resection because of severe tumor adhesion to the border of the intestine.¹¹

CONCLUSION

In conclusion, lipoblastomas emerge as a slowly growing mass in early childhood and are mostly seen on the trunk and extremities. Although benign, they have the potential to increase in size and invade adjacent tissues. The gold standard treatment is complete surgical excision. Due to the possibility of recurrence, regular follow-up is strongly recommended after surgery.

Source of Finance

During this study, no financial or spiritual support was received neither from any pharmaceutical company that has a direct connection with the research subject, nor from a company that provides or produces medical instruments and materials which may negatively affect the evaluation process of this study.

Conflict of Interest

No conflicts of interest between the authors and / or family members of the scientific and medical committee members or members of the potential conflicts of interest, counseling, expertise, working

conditions, share holding and similar situations in any firm.

Authorship Contributions

Idea/Concept: Fatih Akova, Emrah Aydın, Murat Binar; **Design:** Fatih Akova, Emrah Aydın, Murat Binar; **Control/Supervision:** Fatih Akova, Emrah Aydın, Murat Binar; **Data Collection and/or Processing:** Fatih Akova; **Analysis and/or Interpretation:** Fatih Akova, Emrah Aydın, Murat Binar; **Literature Review:** Fatih Akova, Emrah Aydın, Murat Binar; **Writing the Article:** Fatih Akova, Emrah Aydın, Murat Binar; **Critical Review:** Fatih Akova, Emrah Aydın, Murat Binar.

REFERENCES

1. Wu Q. Andrews' diseases of the skin: Clinical dermatology, 13th edition. J Am Acad Dermatol. 2019;81(6):e187. [Crossref]
2. Burchhardt D, Fallon SC, Lopez ME, Kim ES, Hicks E, Brandt ML. Retroperitoneal lipoblastoma: A discussion of current management. J Pediatr Surg. 2012;47(10):e51-54. [Crossref] [PubMed]
3. Tatlıdede S, Gönen E, Yalçın M, Kabukçuoğlu F, Çetinçelik Ü, Baş L. Tekrarlayan serviko-aksiller lipoblastomatozis: Olgu sunumu. [Recurrent cervico-axillary lipoblastomatozis: Case presentation]. Çocuk Cerrahisi Dergisi. 2007;21(1):49-52. [Link]
4. Susam-Sen H, Yalçın B, Kutluk T, Tanyel FC, Haliloglu M, Orhan D, et al. Lipoblastoma in children: Review of 12 cases. Pediatr Int. 2017;59(5):545-50. [Crossref] [PubMed]
5. Chun YS, Kim WK, Park KW, Lee SC, Jung SE. Lipoblastoma. J Pediatr Surg. 2001;36(6):905-7. [Crossref] [PubMed]
6. Dutton JJ, Escaravage GK Jr, Fowler AM, Wright JD. Lipoblastomatozis: case report and review of the literature. Ophthalmic Plast Reconstr Surg. 2011;27(6):417-21. [Crossref] [PubMed]
7. Coffin CM, Lowichik A, Putnam A. Lipoblastoma (LPB): a clinicopathologic and immunohistochemical analysis of 59 cases. Am J Surg Pathol. 2009;33(11):1705-12. [Crossref] [PubMed]
8. Hasdıraz L. Çocukluk çağının mediastinal tümör ve kistleri [Mediastinal tumors and cysts of childhood]. Toraks Cerrahi Bülteni. 2011;2:136-46. [Crossref]
9. Guanà R, Garofalo S, Ferrero L, Cortese MG, Lonati L, Teruzzi E, et al. Infantile abdominal and pelvic lipoblastomas: a case series. European J Pediatr Surg Rep. 2019;7(1):e104-e109. [Crossref] [PubMed] [PMC]
10. Kassem R, Faiz A, Kumar SY, John SA, Khan YA, Khan AS. Lipoblastoma and lipomatosis in children-case report. J Pediatr Surg Case Reports. 2017;19:4-5. [Crossref]
11. Nagano Y, Uchida K, Inoue M, Ide S, Shimura T, Hashimoto K, et al. Mesenteric lipoblastoma presenting as a small intestinal volvulus in an infant: A case report and literature review. Asian J Surg. 2017;40(1):70-3. [Crossref] [PubMed]
12. Shen LY, Amin SM, Chamlin SL, Mancini AJ. Varied presentations of pediatric lipoblastoma: case series and review of the literature. Pediatr Dermatol. 2017;34(2):180-6. [Crossref] [PubMed]
13. Choi HJ, Lee YM, Lee JH, Kim JW, Tark MS. Pediatric lipoblastoma of the neck. J Craniofac Surg. 2013;24(5):e507-10. [Crossref] [PubMed]
14. Kerkeni Y, Sahnoun L, Ksia A, Hidouri S, Chahed J, Krichen I, et al. Lipoblastoma in childhood: about 10 cases. Afr J Paediatr Surg. 2014;11(1):32-4. [Crossref] [PubMed]
15. Bruyeer E, Lemmerling M, Poorten VV, Sciort R, Hermans R. Paediatric lipoblastoma in the head and neck: three cases and review of literature. Cancer Imaging. 2012;12(3):484-7. [Crossref] [PubMed] [PMC]
16. Pham NS, Poirier B, Fuller SC, Dublin AB, Tollefson TT. Pediatric lipoblastoma in the head and neck: a systematic review of 48 reported cases. Int J Pediatr Otorhinolaryngol. 2010;74(7):723-8. [Crossref] [PubMed]
17. Dutta M, Kundu S, Roy, Mukhopadhyaya S. Lipoblastomatozis of the retropharyngeal space: pathogenesis, presentation, and management, with a focus on head-neck lipoblastoma(toses). B-ENT. 2016;12(1):33-9. [PubMed]
18. Abdul-Ghafar J, Ahmad Z, Tariq MU, Kayani N, Uddin N. Lipoblastoma: a clinicopathologic review of 23 cases from a major tertiary care center plus detailed review of literature. BMC Res Notes. 2018;11(1):42. [Crossref] [PubMed] [PMC]
19. Gong LH, Liu WF, Ding Y, Geng YH, Sun XQ, Huang XY. Diagnosis and differential diagnosis of desmoplastic fibroblastoma by clinical, radiological, and histopathological analyses. Chin Med J (Engl). 2018;131(1):32-6. [Crossref] [PubMed] [PMC]
20. Segquier-Lipszyc E, Hermann G, Kaplinski C, Lotan G. Fibrous hamartoma of infancy. J Pediatr Surg. 2011;46(4):753-5. [Crossref] [PubMed]
21. Navarro OM, Laffan EE, Ngan BY. Pediatric soft-tissue tumors and pseudo-tumors: MR imaging features with pathologic correlation: part 1. Imaging approach, pseudotumors, vascular lesions, and adipocytic tumors. Radiographics. 2009;29(3):887-906. [Crossref] [PubMed]
22. Moholkar S, Sebire NJ, Roebuck DJ. Radiological-pathological correlation in lipoblastoma and lipoblastomatozis. Pediatr Radiol. 2006;36(8):851-6. [Crossref] [PubMed]
23. Dille AV, Patel DL, Hicks MJ, Brandt ML. Lipoblastoma: pathophysiology and surgical management. J Pediatr Surg. 2001;36(1):229-31. [Crossref] [PubMed]
24. Bartuma H, Domanski HA, Von Steyern FV, Kullendorff CM, Mandahl N, Mertens F. Cytogenetic and molecular cytogenetic findings in lipoblastoma. Cancer Genet Cytogenet. 2008;183(1):60-3. [Crossref] [PubMed]

25. Moaath A, Raed E, Mohammad R, Mohammad S. Lipoblastoma: a rare mediastinal tumor. *Ann Thorac Surg.* 2009;88(5):1695-7. [[Crossref](#)] [[PubMed](#)]
26. Ko SF, Shieh CS, Shih TY, Hsiao CC, Ng SH, Lee TY, et al. Mediastinal lipoblastoma with intraspinal extension: MRI demonstration. *Magn Reson Imaging.* 1998;16(4):445-8. [[Crossref](#)] [[PubMed](#)]
27. Speer AL, Schofield DE, Wang KS, Shin CE, Stein JE, Shaul DB, et al. Contemporary management of lipoblastoma. *J Pediatr Surg.* 2008;43(7):1295-300. [[Crossref](#)] [[PubMed](#)]
28. Mognato G, Cecchetto G, Carli M, Talenti E, d'Amore ES, Pederzini F, et al. Is surgical treatment of lipoblastoma always necessary? *J Pediatr Surg.* 2000;35(10):1511-3. [[Crossref](#)] [[PubMed](#)]
29. Sakamoto S, Hashizume N, Fukahori S, Ishii S, Saikusa N, Yoshida M, et al. A large retroperitoneal lipoblastoma: A case report and literature review. *Medicine (Baltimore).* 2018;97(40):e12711. [[Crossref](#)] [[PubMed](#)] [[PMC](#)]
30. Hicks J, Dilley A, Patel D, Barrish J, Zhu SH, Brandt M. Lipoblastoma and lipoblastomatosis in infancy and childhood: histopathologic, ultrastructural, and cytogenetic features. *Ultrastruct Pathol.* 2001;25(4):321-33. [[Crossref](#)] [[PubMed](#)]