

Bleomycin-Induced Pulmonary Fibrosis, Severe Hypoxia and Intracardiac Air Embolism: Case Report

Bleomisin'e Bağlı Pulmoner Fibrozis, Ciddi Hipoksi ve İntrakardiyak Hava Embolisi

Bülent GÜÇYETMEZ^a
Aylin OGAN,^a
Berrin YALÇIN GÜDER,^a
Aylin ÇİMET AYYILDIZ,^a
Lütfi TELCİ^b

^aIntensive Care Unit,
International Hospital, İstanbul,
^bDepartment of Anesthesiology,
İstanbul University
İstanbul Faculty of Medicine, İstanbul

Geliş Tarihi/Received: 01.01.2013
Kabul Tarihi/Accepted: 04.03.2013

Yazışma Adresi/Correspondence:
Bülent GÜÇYETMEZ
International Hospital,
Intensive Care Unit, İstanbul,
TÜRKİYE/TURKEY
drbulentgucyetmez@yahoo.com

ABSTRACT Bleomycin sulphate is a mixture of cytotoxic glycopeptide antibiotics isolated from a strain of *Streptomyces verticillus*. Use of bleomycin in squamous cell carcinoma, lymphoma, testicular carcinoma and malignant pleural effusion has been associated with the development of pulmonary fibrosis in 1% of cases. Bleomycin-induced pulmonary fibrosis results in severe hypoxemia due to inflammation that develops in the alveolar capillary membrane and this patients are associated with less-than-expected response to medical treatment besides the likelihood of complications related to mechanical ventilation. Herein, we report development of severe hypoxemia and intracardiac air embolism under mechanical ventilation who has no response to medical treatment in a 39-year-old male patient following bleomycin treatment.

Key Words: Bleomycin; pulmonary fibrosis; embolism, air

ÖZET Bleomisin sülfat, *Streptomyces verticillus*'un bir alt türünden izole edilmiş sitotoksik glikopeptid antibiyotiklerin bir karışımıdır. Skuamöz hücreli karsinom, lenfoma, testiküler karsinom ve malign plevral effüzyonda kullanılan bleomisine bağlı %1 olguda pulmoner fibrozis gelişmektedir. Bleomisin'e bağlı gelişen pulmoner fibrozis alveolokapiller membranda inflamasyon oluşumuna bağlı ciddi hipoksi ile sonuçlanır. Bu hastalarda medikal tedaviye yanıt beklenenden azdır ayrıca mekanik ventilasyona bağlı olası komplikasyonlar gelişmektedir. Bleomisin tedavisini takiben pulmoner fibrozis gelişen, medikal tedavilere yanıt alınmayan, ciddi hipoksi ile seyreden ve mekanik ventilasyon altında intrakardiyak hava embolisi gelişen 39 yaşındaki erkek olgumuz sunulmuştur.

Anahtar Kelimeler: Bileomisin; pulmoner fibrozis; emboli, hava

Türkiye Klinikleri J Case Rep 2015;23(1):12-5

Bleomycin sulphate is a mixture of cytotoxic glycopeptide antibiotics isolated from a strain of *Streptomyces verticillus*.¹ Use of bleomycin in squamous cell carcinoma, lymphoma, testicular carcinoma and malignant pleural effusion has been associated with the development of pulmonary fibrosis in 1% of cases.² Development of alveolitis in the early period of bleomycin-induced inflammation and fibrosis due to chronic inflammation have been demonstrated.^{3,4} In the acute phase, an increase in the prothrombotic and procoagulant activity while a decrease in the fibrinolytic activity occurs in the bronchoalveolar compartment.⁵ Fibroblast deposition in the lung capillary endothelial cells, possibly through endothelial–mesenchymal transition was also shown in bleomycin-induced pulmonary fibrosis.⁶ Herein we report development of pulmonary fibrosis following bleomycin treatment in

doi: 10.5336/caserep.2013-33534

Copyright © 2015 by Türkiye Klinikleri

a 39-year-old male patient who was unresponsive to medical therapy and developed intracardiac air embolism under mechanical ventilation therapy.

CASE REPORT

A 39-year-old male patient who had been received 2 doses of 0.5 U/kg bleomycin following orchietomy and radiotherapy for the testicular tumor a month ago was admitted to the emergency department with the signs of tachypnea (30/min), fever (38.8 °C) and poor oxygen saturation (SpO₂: 88%). Informed consent form was taken from the patient and the patient was transferred to intensive care unit (ICU) upon detection of bilateral consolidation in the lung tomography with the diagnosis of bronchopneumonia (Figure 1). His length of stay in the ICU was composed of four consecutive phases principally, including noninvasive mechanical ventilation (NIMV) phase, invasive mechanical ventilation phase prior to tracheotomy (IMV), tracheal insufflation phase and post-insufflation phase (Figure 2). While administration of NIMV in BIPAP/ST mode with PEEP: 8 cm H₂O, FiO₂: 40% in the first three days of hospitalization at the ICU enabled improvement in PaO₂/FiO₂ ratio, tachypnea (50/min), hypercarbia (70 mmHg), PaO₂/FiO₂ (178) development on the third day of ICU stay necessitated initiation of IMV in pressure controlled ventilation (PCV) mode with PEEP; 10 cm H₂O, FiO₂: 40%. Although recruitment maneuver (30 cmH₂O PEEP; 30 sec) was administered on days 3 and 11, no improvement was observed in PaO₂/FiO₂ ratio and hypercarbia. On day 8, upon identification of an increase in the consolidation areas in the lung tomography (Figure 1) and development of septic shock; noradrenaline and hydrocortisone were added to the treatment. From day 12 to 21, percutaneous tracheotomy was performed followed with tracheal oxygen insufflation (10 L/min) while IMV support was continued in SIMV-PSV mode. In this period, PEEP was reduced while peak pressures were increased due to hypercarbia. Due to continuation of hypoxia and hypercarbia under tracheal insufflation from the day 17, inhaler surfactant, inhaler iliomedin (PGI₂) and intravenous non-steroidal anti-inflammatory drug (NSAID) were added to the treatment. Upon tomographic finding of an increase in consolidation areas

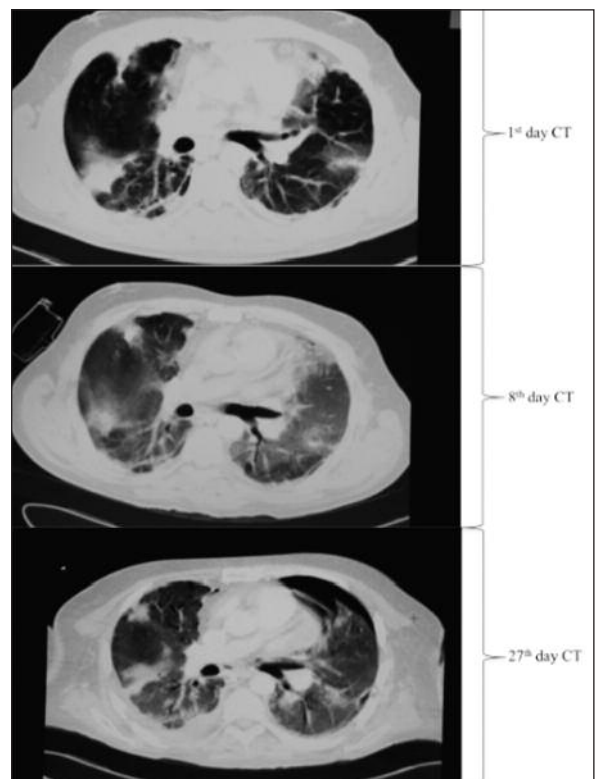


FIGURE 1: Radiological imaging.

on day 21 (Figure 1) inhaler treatments and tracheal insufflation were discontinued. While recruitment maneuver was repeated (30 cmH₂O PEEP; 30 sec), he developed hypercarbia (97 mmHg) and pneumothorax. The pneumothorax recurred two more times between days 21 and 30 following thoracic drainage as accompanied with lack of improvement in PaO₂/FiO₂ ratio and PaCO₂ under high Peak and PEEP pressures. Patient developed sudden hypotension, bradycardia and poor saturation (85%) on day 30. Trans-esophageal echocardiography (TEE) revealed intracardiac air embolism and patient was lost following cardiac arrest (Figure 3).

DISCUSSION

Bleomycin is the most commonly used drug in induction of pulmonary fibrosis in experimental studies.²⁻⁴ To date, no treatment has been clearly shown to reverse the fibrosis after the development of pulmonary fibrosis,^{7,8} whereas there are also studies indicating the prevention or slowing down of fibrosis development via use of certain drugs

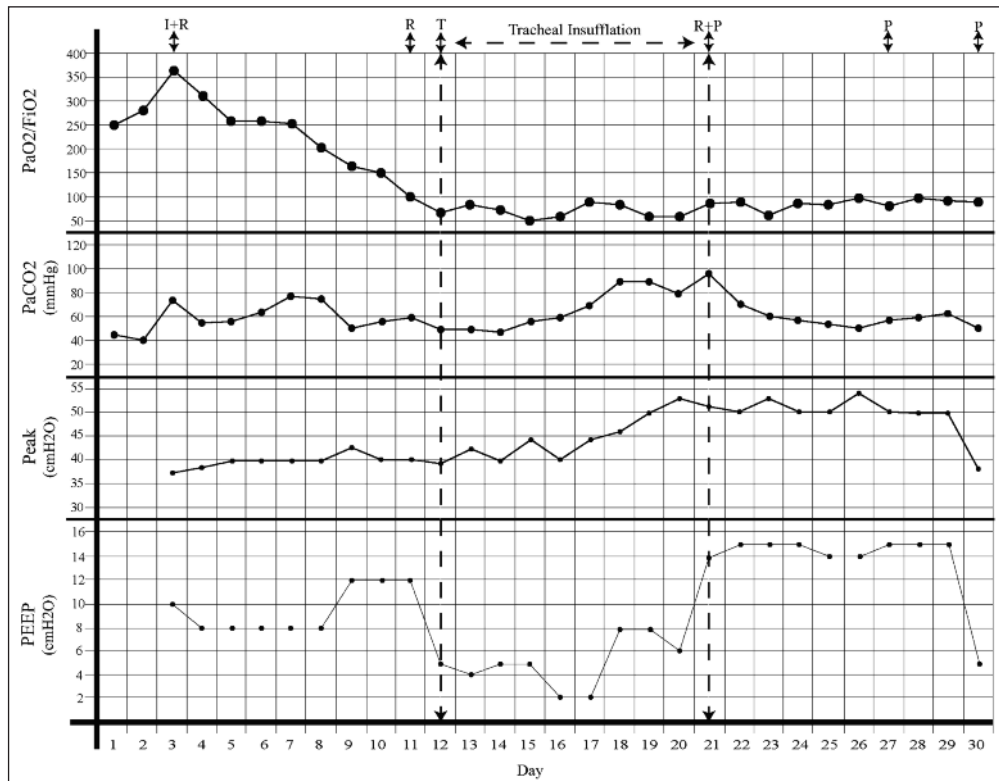


FIGURE 2: Daily $\text{PaO}_2/\text{FiO}_2$ (max.), PaCO_2 (max.), Peak (min.), PEEP (max.), I: Intubation, R: Recruitment; T: Tracheotomy; P: Pneumothorax.

prior to or concomitant with bleomycin treatment including glucocorticoids, prostaglandins, surfactants, prostacyclin analogues.⁹⁻¹¹ In our case, there was no response to treatment with inhaler surfactant, inhaler prostacyclin, and IV NSAIDs one month after the use of bleomycin. NIMV and IMV was shown to be similar in terms of mortality in case of need to mechanical ventilation support among patients with pulmonary fibrosis.^{12,13}

In our patient, due to development of tachypnea, hypoxia and hypercarbia despite the NIMV support within the first three days, IMV was initiated while peak and PEEP pressures were also required since hypoxia and hypercarbia were maintained under IMV. Use of high tidal volume after pulmonary fibrosis was shown to be associated with increase in lung injury and decrease in survival by triggering the inflammatory process.¹⁴⁻¹⁷ For tidal volumes over 6ml/kg, release of inflammatory mediators from epithelial membrane such as macrophage inflammatory protein-2 (MIP-2) and IFN- γ -inducible protein (IP-10) has been

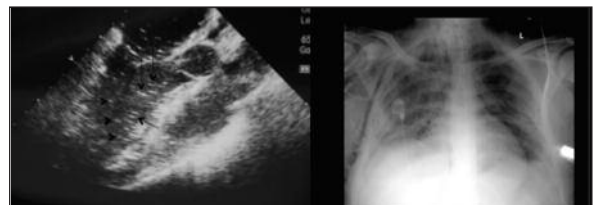


FIGURE 3: Intracardiac air embolism.

shown to cause ventilator induced lung injury (VILI).^{18,19} Similarly, in cases with bleomycin-induced pulmonary fibrosis MIP-2 and IP-10 lead lung injury via angiogenic activity and fibroblast migration.²⁰⁻²² For this reason, management of artificial ventilation process in bleomycin-induced pulmonary fibrosis has been quite challenging. It seems more appropriate to use low inspiratory pressures and self-controlled NIMV or IMV models. Since concomitant presence of pulmonary hypertension in pulmonary fibrosis has been claimed to cause stroke via leakage of air into the alveolo-capillary bed, use of high inspiratory pressure may exacerbate the fragility of the alveolo-capillary re-

gion.²³ The rate of intracardiac air formation was shown to be 73% after open heart surgery and 11% following coronary bypass graft, while a total of 6 cases were reported to develop acute myocardial infarction due to intracardiac air following open heart surgery.^{24,25} In case of experimental studies, it was demonstrated that 0.1 ml of air in coronary vessels is sufficient to cause myocardial infarction.²⁶ Data on higher efficacy of TEE in identification of intracardiac air embolism are available in the literature.²³⁻²⁷ In our patient diagnosed with pulmonary fibrosis and co-morbid pulmonary hypertension, development of intracardiac air embolism seems to be secondary to alveolo-capillary injury due to increased fragility of the region by application of high inspiratory pressures. Accordingly, development of

sudden cardiac arrest was considered to be related to acute myocardial infarction.

In conclusion, our report emphasizes that bleomycin-induced pulmonary fibrosis may have fatal consequences. Given that no benefit of the selected mechanical ventilation strategies or medical treatments on the clinical course, this group of patients seems to be drawn into a therapeutic process with the lung transplantation as the single most alternative. Therefore, meticulous consideration of the exact indications as well as likely complications is essential in patients to receive bleomycin treatment. Moreover, prophylactic treatments planned to be administered prior to or simultaneously with bleomycin may contribute significantly to the prevention of fatal outcomes in patients to receive bleomycin.

REFERENCES

- Cutroneo KR, Sterling KM Jr. A molecular basis for bleomycin-induced pulmonary fibrosis. *Chest* 1986;89(3 Suppl):121S-122S.
- Phillips JE, Peng R, Burns L, Harris P, Garrido R, Tyagi G, et al. Bleomycin induced lung fibrosis increases work of breathing in the mouse. *Pulm Pharmacol Ther* 2012;25(4): 281-5.
- Balazs G, Noma S, Khan A, Eacobacci T, Herman PG. Bleomycin-induced fibrosis in pigs: evaluation with CT. *Radiology* 1994;191(1): 269-72.
- Liu WW, Chen J, Liu YM, Li SM, Yu W, Chen JY, et al. [The comparative study of quartz dust and bleomycin-induced pulmonary fibrosis in rats]. *Zhonghua Lao Dong Wei Sheng Zhi Ye Bing Za Zhi* 2011;29(7):496-501.
- Günther A, Lübke N, Ermert M, Schermuly RT, Weissmann N, Breihecker A, et al. Prevention of bleomycin-induced lung fibrosis by aerosolization of heparin or urokinase in rabbits. *Am J Respir Crit Care Med* 2003;168(11): 1358-65.
- Hashimoto N, Phan SH, Imaizumi K, Matsuo M, Nakashima H, Kawabe T, et al. Endothelial-mesenchymal transition in bleomycin-induced pulmonary fibrosis. *Am J Respir Cell Mol Biol* 2010;43(2):161-72.
- Dackor RT, Cheng J, Voltz JW, Card JW, Ferguson CD, Garrett RC, et al. Prostaglandin E₂ protects murine lungs from bleomycin-induced pulmonary fibrosis and lung dysfunction. *Am J Physiol Lung Cell Mol Physiol* 2011;301(5): L645-55.
- Lawson WE, Polosukhin VV, Stathopoulos GT, Zoia O, Han W, Lane KB, et al. Increased and prolonged pulmonary fibrosis in surfactant protein C-deficient mice following intratracheal bleomycin. *Am J Pathol* 2005;167(5):1267-77.
- Lovgren AK, Jania LA, Hartney JM, Parsons KK, Audoly LP, Fitzgerald GA, et al. COX-2-derived prostacyclin protects against bleomycin-induced pulmonary fibrosis. *Am J Physiol Lung Cell Mol Physiol* 2006;291(2): L144-56.
- Oizumi K, Nakai Y, Konno K. [Antineoplastic drug-induced pneumonitis-fibrosis]. *Gan No Rinsho* 1984;30(9 Suppl):1217-24.
- Chandler DB, Young K. The effect of diclofenac acid (Voltaren) on bleomycin-induced pulmonary fibrosis in hamsters. *Prostaglandins Leukot Essent Fatty Acids* 1989;38(1):9-14.
- Stern JB, Mal H, Groussard O, Briugère O, Marceau A, Jebrak G, et al. Prognosis of patients with advanced idiopathic pulmonary fibrosis requiring mechanical ventilation for acute respiratory failure. *Chest* 2001;120(1): 213-9.
- Mollica C, Paone G, Conti V, Ceccarelli D, Schmid G, Mattia P, et al. Mechanical ventilation in patients with end-stage idiopathic pulmonary fibrosis. *Respiration* 2010;79(3): 209-15.
- Chen F, Gong L, Zhang L, Wang H, Qi X, Wu X, et al. Short courses of low dose dexamethasone delay bleomycin-induced lung fibrosis in rats. *Eur J Pharmacol* 2006;536(3): 287-95.
- Chaudhary NI, Schnapp A, Park JE. Pharmacologic differentiation of inflammation and fibrosis in the rat bleomycin model. *Am J Respir Crit Care Med* 2006;173(7):769-76.
- Fernández-Pérez ER, Yilmaz M, Jenad H, Daniels CE, Ryu JH, Hubmayr RD, et al. Ventilator settings and outcome of respiratory failure in chronic interstitial lung disease. *Chest* 2008;133(5):1113-9.
- Fernández-Pérez ER, Yilmaz M, Jenad H, Daniels CE, Ryu JH, Hubmayr RD, et al. Ventilator settings and outcome of respiratory failure in chronic interstitial lung disease. *Chest* 2008;133(5):1113-9.
- Matthay MA, Zimmerman GA, Esmon C, Bhatnagary J, Coller B, Doerschuk CM, et al. Future research directions in acute lung injury: summary of a National Heart, Lung, and Blood Institute working group. *Am J Respir Crit Care Med* 2003;167(7):1027-35.
- Keane MP, Belperio JA, Moore TA, Moore BB, Arenberg DA, Smith RE, et al. Neutralization of the CXCL chemokine, macrophage inflammatory protein-2, attenuates bleomycin-induced pulmonary fibrosis. *J Immunol* 1999; 162(9):5511-8.
- Keane MP, Belperio JA, Arenberg DA, Burdick MD, Xu ZJ, Xue YY, et al. IFN-gamma-inducible protein-10 attenuates bleomycin-induced pulmonary fibrosis via inhibition of angiogenesis. *J Immunol* 1999;163(10):5686-92.
- Pignatti P, Brunetti G, Moretto D, Yacoub MR, Fiori M, Balbi B, et al. Role of the chemokine receptors CXCR3 and CCR4 in human pulmonary fibrosis. *Am J Respir Crit Care Med* 2006;173(3):310-7.
- Shimabukuro DW, Sawa T, Gropper MA. Injury and repair in lung and airways. *Crit Care Med* 2003;31(8 Suppl):S524-31.
- Black M, Calvin J, Chan KL, Walley VM. Paradoxical air embolism in the absence of an intracardiac defect. *Chest* 1991;99(3):754-5.
- Oka Y, Moriwaki KM, Hong Y, Chuculate C, Strom J, Andrews IC, et al. Detection of air emboli in the left heart by M-mode transesophageal echocardiography following cardiopulmonary bypass. *Anesthesiology* 1985; 63(1):109-13.
- Okamura Y, Takeuchi Y, Gomi A, Nagashima M, Mori H, Hattori J. [Clinical evaluation of perioperative myocardial infarction as a complication of valve replacement]. *Kyobu Geka* 1989;42(12):1012-5.
- Goldfarb D, Bahnson HT. Early and late effects on the heart of small amounts of air in the coronary circulation. *J Thorac Cardiovasc Surg* 1963;46:368-78.
- Topol EJ, Humphrey LS, Borkon AM, Baumgartner WA, Dorsey DL, Reitz BA, et al. Value of intraoperative left ventricular microbubbles detected by transesophageal two-dimensional echocardiography in predicting neurologic outcome after cardiac operations. *Am J Cardiol* 1985;56(12):773-5.