

A Scleroderma Case with Coexisting Hashimoto's Thyroiditis and Polymyositis

HASHIMOTO TİROİDİTİ VE POLİMİYÖZİTLE BİRLİKTE OLAN BİR SKLERODERMA OLGUSU

Refik Ali SARI*, Alaattin AVŞAR*, Murat SARUÇ*, Mehmet MEŞHUR*, Gamze GÖKSEL*, Şerife ARSLAN*

* Depts. of Internal Medicine and Cardiology, and Physical Therapy and Rehabilitation, Medical School of Celal Bayar University, Manisa, TURKEY

Summary

Systemic sclerosis (SSc) is a generalized disorder that is characterized by fibrosis and microvascular injury in affected organs. Although SSc may show a single presentation without any other disease, one may see any of the aforementioned manifestations of SSc with features of SLE, RA, inflammatory muscle disease, chronic thyroiditis or Sjögren's syndrome. In this article a case with scleroderma with coexisting Hashimoto's thyroiditis, polymyositis is presented and literature is reviewed.

Key Words: Scleroderma, Hashimoto's thyroiditis, Polimiyosistis

T Klin J Med Sci 1998, 18:208-212

Özet

Sistemik skleroz etkilenen organlarda fibrozis ve mikrovasküler hasarla karakterize bir hastalıktır. Herne kadar SSc tek başına görülebilse de SLE, RA, inflamataur kas hastalığı, kronik tiroidit ve Sjögren sendromu ile birlikte overlap yapabilmektedir. Bu makalede Hashimoto tiroiditi ve polimiyozitle birlikte olan bir skleroderma vakası literatür ışığında gözden geçirildi.

Anahtar Kelimeler: Skleroderma, Hashimoto tiroiditi, Polimiyozit

T Klin Tıp Bilimleri 1998, 18:208-212

Systemic Sclerosis is a generalized disorder of the diffuse connective tissue characterized by scarring (fibrosis) and vascular obliteration in the skin, gastrointestinal tract, lungs, heart and kidneys. SSc, which affects women three or four times more than men, manifests two different clinical pictures as limited and diffuse SSc.(1) SSc may show a single presentation without any other disease, but the other hand, in some cases, it may be associated with otoimmune diseases like the aforementioned manifestations of SSc with features of SLE, RA, inflammatory muscle disease, chronic thyroiditis or Sjögren's syndrome, primary biliary cirrhosis. SSc, which affects women three or four times more than

men, manifests two different clinical pictures as limited and diffuse SSc.

In our literature review, there was no reported scleroderma case, which had coexisting Hashimoto's thyroiditis, polymyositis all together. This is what made us to report this case.

Case

A 54 years-old female patient (L.A.) suffered from pain at her neck, back, belly, both shoulders and both arms but more severe at left one and experienced lower extremity weakness in 1990. Nearly, at the same time; dysphagia and atypical abdominal pain occurred and duodenal ulcer was established radiographically. She had sometimes continuous, sometimes intermittent epigastric pain and gastrointestinal discomfort till two years ago, at which time she recognized creases at her face,

Geliş Tarihi: 22.05.1997

Yazışma Adresi: Dr.Refik Ali SARI
Celal Bayar Üniversitesi Tıp Fakültesi
İç Hastalıkları AD, MANISA

shiny skin appearance at her fingers, tight and thickened skin at the other parts of her body. She gained weight, complained from fatigue, headache, palpitation, constipation and irritability. By gradual increase in her symptoms, she suffered from more severe dyspnea and dysphagia.

On Physical examination; she looked nervous and fatigue. She had shiny and taut appearance at her face (Figure 1). There was loss of skin folds (Figure 2-3). The arterial blood pressure and the heart rate were 90/60 mm Hg and 64 beats/minute, rhythmic, respectively. All the joints were painful by motion and the pain was much more severe in the neck. There was symmetric muscle weakness of shoulder and pelvic girdles. There was tenderness of the chest and calf muscles, while palpating these areas but no pain and color change at the fingers. The thyroid gland was enlarged and tight. There was no cervical lymphadenopathy. The abdominal examination revealed epigastric tenderness. There wasn't hepatosplenomegaly and icterus. Neurologic examination was normal.

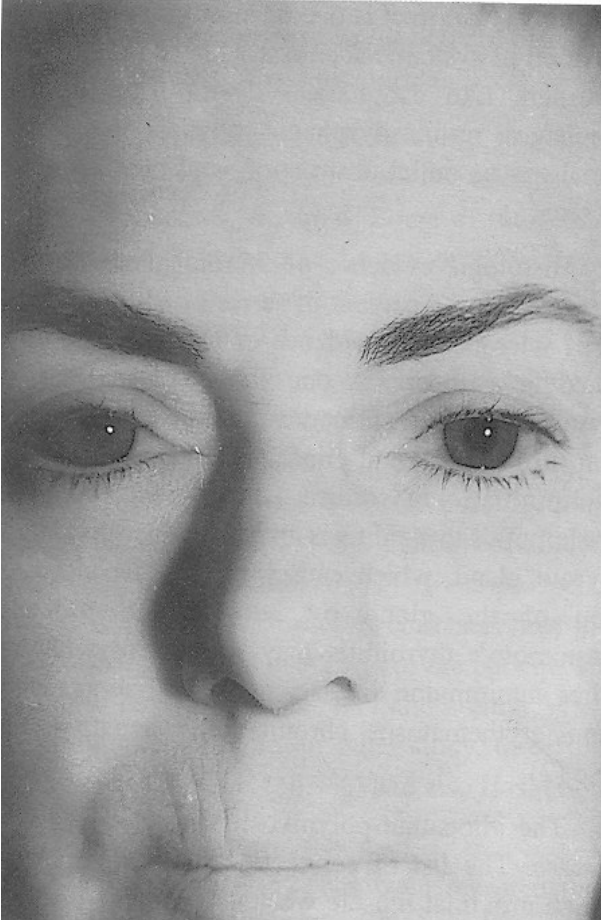


Figure 1.

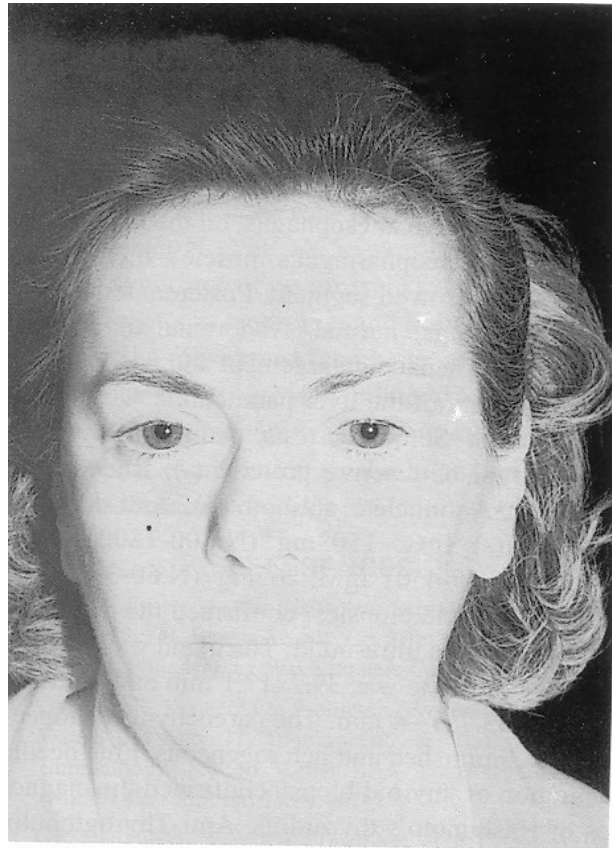

Figure 2.

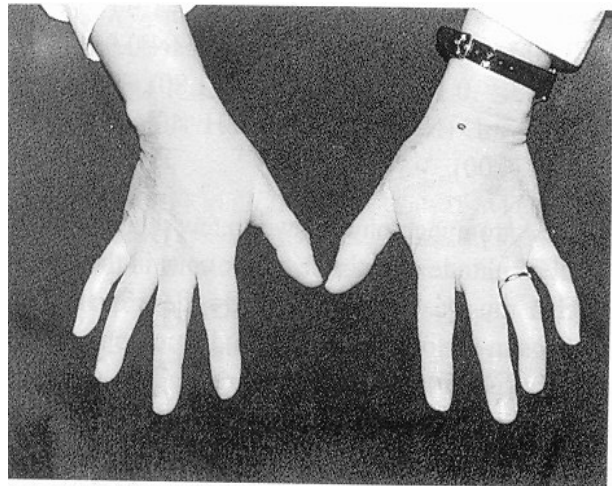


Figure 3.

Laboratory Findings

Hemoglobin: 8.9g m/dL, Hematocrit: 27.9%, White blood cell count: 8600/mm³ Platelet count: 245.000/mm³, Erythrocyte sedimentation rate: 24

mm/hour, Fasting blood glucose: 94 mg/dL, Blood urea nitrogen: 14.2 mg/dL, Creatinine: 1.1mg/dL, SGOT (AST): 78 IU/L, SGPT(ALT): 53I U/L, Gamma glutamyl transpeptidase: 40 IU/L, Lactate dehydrogenase: 893 IU/mL (Wroblewski), Alkaline phosphatase: 306 IU/L, Creatine-phosphokinase: 1948 IU/L, Total cholesterol: 344mg/dL, HDL-Cholesterol: 94 mg/dL, Triglycerede:178 mg/dL, Total proteins: 7.4 gr/dL, Albumin: 4.2 gr/dL, Uric acid: 4.6 mg/dL, Sodium:140 mmol/L, Potassium: 4.3 mmol/L, Urine analysis was normal. Echocardiography: normal. Electrocardiography: 3-3.5 mm ST segments depressions and T waves inversion in the anterior and inferior derivations (subendocardial ischemia or infarction). Esophagus passage radiography (Barium swallow radiography): At the cervical esophagus, on the left wall (at the level of cricopharyngeus muscle); there was a minimally narrowed segment. Posteroanterior lung graphic findings: normal. Abdominal ultrasound: there was no hepatic enlargement and no change in the echogenity of the liver paranchime. The spleen was normal. Serologic tests: Antistreptolysin O test: normal, C-reactive protein: (-), Rheumatoid factor:(-), Antinuclear antibody:(-), Anti-ds DNA antibody:(-) IgG: 1503mg (N:800-1800), IgA: 263mg (N:85-450) IgM: 265mg (N:60-370). The skin and muscle biopsies confirmed the diagnosis of SSc. Thyroid ultrasound: The gland was lobulated . The left lobe was 39.2x17.1 mm and the right one was 43.7x14.4 mm. The parenchyma echogenity was diminished and heterogeneous. Fine needle aspiration of thyroid biopsy confirmed the diagnosis of Hashimoto's thyroiditis. Anti-Thyroglobulin antibody: 1/5120, Anti-Microsomal antibody: 1/25600, confirming Hashimoto's thyroiditis. Serum Thyroid hormone concentrations revealed severe hypothyroidism. Free T3: 1.00 pg/mL (N:3.50-6.10), Free T4: 0.05 pg/mL (N:0.90-1.90), Total T3: 0.10 ng/mL (N:0.80-1.80), Total T4: 0.62 mg/mL (N:4.50-11.70), TSH: 40.40 mgr/mL (N:0.23-4.00).

Electromyography: showed a few short duration, small amplitude polyphasic motor units in the biceps brachia muscle but not revealed these qualitative findings in the other muscles. Audiometric findings: did not confirm Meniere's disease but revealed changes in the favor of connective tissue disease.

Clinical Progress

The patient was admitted to intensive care unit with the diagnosis of acute ischemic syndrome (unstable angina pectoris or acute non-Q myocardial infarction). Nitroglycerin infusion was started (30 mcg/min). Aspirin 300 mg/d, famotidine 40 mg/d and liquid antacid (magaldrate) 7x10cc/d were administered. After three days treatment, her symptoms were disappeared.

Because of severe hypothyroidism, the patient was given low dose levothyroxin, 25mg/d, as a starting dose by carefully monitoring cardiac functions and symptoms. The patient was transferred to her bed in the internal medicine clinic and isosorbid mononitrate 20 mg two times daily was added to her treatment. After the hospitalization three weeks, she was discharged with the treatment of isosorbid mononitrate 40 mg/d, aspirin 300 mg/d, famotidine 40 mg/d, prednisolone 40 mg/d and levothyroxin 100 mg/d (levothyroxin doses were gradually increased). The patient showed significant improvement in her symptoms and she is now followed with periodic control.

Discussion

Systemic sclerosis is a generalized disorder of connective tissue characterized clinically by thickening and fibrosis of the skin. The etiology and pathogenesis are unknown. The clinical course is rather slow. SSc is three or four times more common in women than men, and the disease onset is highest between ages 30 and 50. Involvement of gastrointestinal tract is one of most common manifestation of systemic sclerosis. One or more of the disorders like esophageal dysmotility, gastroesophageal reflux, dysphagia, odynophagia, functional gastric outlet obstruction, and bleeding may be seen(5).

Histologic evidence of thyroid gland fibrosis was found in 14 percent of series of autopsied cases of scleroderma. Evidence of hypothyroidism is noted in as many as one fourth of patients(6). Serum antithyroid antibodies, lymphocytic infiltration of the gland and clinic presentation of acute autoimmune thyroiditis are uncommon(7). Hashimoto's thyroiditis is an inflamatuar disease of thyroid gland, which causes progressive destruction of the gland by autoimmune process.

Hashimoto's thyroiditis may be present with the other autoimmune diseases together, like systemic lupus erythematosus, chronic active hepatitis, and SSc (2).

The idiopathic polymyositis is relatively rare disease. The list of connective tissue diseases in which proximal muscle weakness may be present, is long. That is why, it is not always easy to distinguish one from the other. SSc and polymyositis (PM) may be different clinical experiences of the same disease process (2,3). Up to 10% of patient with SSc have an inflammatory myopathy, most likely caused by microvascular injury. These patients have classic myositis, indistinguishable from polymyositis.

Mimori et al. analyzed 240 Japanese patients with scleroderma and 105 patients with polymyositis, 27 patients had both scleroderma and polymyositis together(4). The myositis of scleroderma is characterized by fiber size variation, mononuclear cell infiltration around perimysial blood vessels, increased amounts of connective tissue in the endomysial and perimysial regions, and occasional necrosis of single muscle fiber(8). The creatinine phospho kinase (CK) level, which is elevated in 99 percent of the patients, is the most sensitive test for polymyositis. The SGOT (AST), SGPT (ALT), lactate dehydrogenase, and aldolase are found increased in the sera of these patients. The erythrocyte sedimentation rate is normal in more than one half of patients. The electromyographic abnormalities are present in 90 percent of patients but in 10 percent, it is quite normal (1,2).

During our literature review, we found some scleroderma cases, which had coexisting wide range of diseases, reported. Some of the reported cases were; A woman at the age of 32 years with scleroderma, Hashimoto's thyroiditis, and membranous nephropathy (9); a patient with CREST syndrome and Hashimoto's thyroiditis (10); a 36 years old patient with scleroderma, thyroiditis and myasthenia gravis (11); and lastly, a 53 years old woman with scleroderma, who had the combination of Hashimoto's thyroiditis, Sjögren syndrome, and primary biliary cirrhosis (12). In a prospective study, The thyroid disorders were researched in 39 scleroderma patients and 18 % of the patients were

found to have antimicrosomal and antithyroglobulin antibodies (13). In an other study, three of 28 scleroderma patients (10.7%) had also Hashimoto's thyroiditis.

Werneck AL et al. has been reported that a thirty-six years old woman with myasthenia gravis developed cold intolerance after two years, and Hashimoto's thyroiditis diagnosis was established. Four years later she exhibited skin thickening (limited scleroderma). Hashimoto's thyroiditis and myasthenia gravis are infrequently associated. Occurrence of scleroderma and myasthenia gravis in the same patient is rare. The coincidence of these three disorders was not found in literature (14). Hosoya N et al; A 56-year-old woman with overlap syndrome of progressive systemic sclerosis (PSS), Sjogren's syndrome, and polymyositis is reported. She developed complete atrioventricular (AV) block and progressive bilateral hilar adenopathy, and was diagnosed as having sarcoidosis by histological examination of the hilar lymph nodes biopsied thoracoscopically (15).

REFERENCES

1. Le Roy. Systemic sclerosis (scleroderma). In: Wyngaarden JB, Smith LH, Benett JC, eds. Cecil Textbook of Medicine, 19th ed. Philadelphia: WB Saunders Co, 1992: 1530-5.
2. Kenneth HF, Kenneth ES. Progressive systemic sclerosis. In: Daniel PS, Abba IT, Tristram GP, eds. Basic & Clinical Immunology, 8th ed. Lebanon, a lange medical book (Middle East Edition) 1994: 401-4.
3. Gay RE, Buckingham RB, Prince RK, et al. Collagen types synthesized in dermal fibroblast cultures from patients with early progressive systemic sclerosis. *Arthritis Rheum* 1980; 23:190.
4. Uitto J, Murray L.W, Blumberg B, et al. Biochemistry of collagen in diseases. *Ann Intern Med* 1986; 105: 740.
5. Zamost BJ, Hirschberg J, Ippoliti AF, et al.: Esophagitis in scleroderma. Prevalance and risk factors. *Gastroenterology* 92:421,1987.
6. Gordon MB, Klein I, Dekker A, et al. Thyroid disease in progressive systemic sclerosis: Increased frequency of glandular fibrosis and hypothyroidism. *Ann Intern Med* 1981; 95: 431.
7. Lally EV and jimenez SA. Impotance in progressive systemic sclerosis. *Ann. Intern. Med.* 1981; 95:150.
8. Ringel RA, Brick JE, Brick JF, et al. Muscle involment in the scleroderma syndromes. *Arch Intern Med* 1990; 150:2550.

9. Akikusa B, Kondo Y, Iemoto Y, Ieosoto K, Wakashin M. Hashimoto's thyroiditis and membranous nephropathy developed in progressive systemic sclerosis (PSS). *Am J Clin Pathol* 1984; 81(2):260-3.
10. Ibanez JA, Izquierdo CC, Malumbres JP et al. The CREST syndrome and Hashimoto's thyroiditis, apropos a case seen in our primary care center. *An Med Interna* 1993; 10(2):99.
11. Werneck AL, Checcacci BT, Tuma G. Scleroderma, thyroiditis, and myasthenia gravis: study of a case. *Arq Neuropsiquiatr* 1993; 51(4):549-53.
12. Horita M, Takahashi N, Sieke M, Nasu S, Takaki R. A case of primary biliary cirrhosis associated with Hashimoto's thyroiditis, scleroderma and Sjogren's syndrome. *Ann Intern Med* 1992; 31(3):418-21.
13. De Keyser L, Narhi DC, Furst DE et al. Thyroid dysfunction in a prospectively followed series of patients with progressive systemic sclerosis. *J Endocrinol Invest* 1990; 13(2):161-9.
14. Werneck AL; Checcacci-Balod T; Tuma G. Scleroderma, thyroiditis, and myasthenia gravis: study of a case. *Arq Neuropsiquiatr (BRAZIL)*, 1993; 51(4); 549-53 (Abstract).
15. Hosoya N, Mimura T, Enokawa Y, Mizuno T, Hamasaki K, Matsuyama T, Matsuhashi N, Yotsumoto H, Yazaki Y. A rare case of cardiac sarcoidosis in a patient with progressive systemic sclerosis, Sjogren's syndrome, and polymyositis. *Intern Med (JAPAN)* 1995; 34 (12) 1164-7 (Abstract).